

# Skeletal Transversal Expansion Using Modified RME Appliance in Adult Patient

## Yetişkin Hastada Modifiye RME Apareyi Kullanılarak İskeletsel Transversal Genişletme

Serdar ÇİK<sup>1</sup>



<sup>1</sup> Republic of Turkey Ministry of Health,  
Kocaeli, Türkiye

Ali KİKİ<sup>2</sup>



<sup>2</sup> Atatürk University, Dentistry Faculty,  
Department of Orthodontics, Erzurum, Türkiye



### ABSTRACT

In this study, rapid maxillary expansion without corticotomy with the use of a miniscrew-supported appliance in an adult patient is presented. As a result of the clinical examination of an 18-year-old Caucasian female patient, she had a bilateral posterior crossbite. The upper midline was coincident with the facial midline, whereas there was a deviation to the right in the lower midline. Angle's Class II molar relationship on the right and Angle's Class I on the left were observed. Arch-length deficiency values were -2 mm in the upper and -3 mm in the lower. Overjet was 7.5 mm and overbite was 0 mm. It was determined by the hand-wrist radiograph that the patient's growth was ceased. It was planned to expand maxilla non-surgically prior to any other orthodontic interventions. After 55 quarter-turns of activation the appliance was left in mouth passively for 3 months. Her fixed treatment is continuing. With RME SNB angle did not change and SNA angle increased by approximately 1 degree. 1-SN decreased by approximately 6 and IMPA by 1 degrees. Inclinations of the upper first molar teeth were not significantly changed as confirmed by postero-anterior radiograph. Overjet increased from 7.5 to 9 mm while the amount of overbite remained as 0 mm. It was determined by the model analysis that the increase in intermolar was 6.18 mm and intercanine widths was 5.21 mm. There was no significant change in lower teeth in model measurements. It is seen that the presented appliance can achieve sutural expansion without any corticotomy in adult patients.

**Key Words:** Modified RME, Appliance, Adult patient, Corticotomy, MARPE

### Öz

Bu çalışmada, yetişkin bir hastada mini vida destekli aparey kullanımı ile kortikotomi olmaksızın hızlı maksiller ekspansiyon sunulmuştur. On sekiz yaşındaki kafkas kadın hastanın klinik muayenesinde bilateral posterior çapraz kapanışa sahip olduğu görüldü. Üst orta hat yüz orta hattı ile aynı hizada iken alt orta hatta sağa doğru bir sapma mevcuttu. Sağda Angle Sınıf II, solda Angle Sınıf I molar ilişki gözlemlendi. Üst çenede -2 mm ve alt çenede -3 mm yer ihtiyacı olduğu tespit edildi. Overjet 7,5 mm ve overbite 0 mm idi. El-bilek radyografisi ile hastanın büyümesinin sona erdiği tespit edildi. Diğer ortodontik müdahalelerden önce cerrahi olmayan bir şekilde maksilla genişletilmesi planlandı. 55 çeyrek tur aktivasyondan sonra aparey 3 ay pasif olarak ağızda bırakıldı. Hastanın sabit tedavisi devam etmektedir. RME ile SNB açısı değişmedi ve SNA açısı yaklaşık 1 derece arttı. 1-SN yaklaşık 6, IMPA ise 1 derece azaldı. Üst birinci molar dişlerin eğimleri, postero-anterior radyografiyle doğrulandığı gibi önemli ölçüde değişmedi. Overjet 7,5 mm'den 9 mm'ye çıkarken overbite miktarı 0 mm'de kaldı. Molarlar arası artışın 6,18 mm, kaninler arası genişliklerin ise 5,21 mm olduğu model analizi ile belirlendi. Model ölçülerinde alt dişlerde anlamlı bir değişiklik görülmedi. Sunulan apareyin yetişkin hastalarda herhangi bir kortikotomi gerekmeden sütür genişlemesini sağlayabildiği görülmektedir.

**Anahtar Kelimeler:** Modifiye RME, Cihaz, Erişkin hasta, Kortikotomi, MARPE

Geliş Tarihi/Received 13.04.2022  
Kabul Tarihi/Accepted 17.08.2022  
Yayın Tarihi/Publication Date 15.10.2024

Sorumlu Yazar/Corresponding author:  
Serdar ÇİK

E-mail: Serdar.cik@hotmail.com

Cite this article: Çik S, Kiki A. Skeletal Transversal Expansion Using Modified RME Appliance in Adult Patient. *Curr Res Dent Sci.* 2024;34(4): 306-309.



Content of this journal is licensed under a Creative Commons Attribution-NonCommercial-NoDerivatives 4.0 International License

## INTRODUCTION

One of the most common orthodontic problems is maxillary transversal constriction.<sup>1</sup> This constriction has both skeletal and dental manifestations. It has been reported in scientific studies that maxillary constriction may be caused by several reasons and it has been treated by different methods such as slow expansion, rapid expansion, semi-rapid expansion, surgically assisted rapid expansion (SARME) and surgical expansion, which are applied according to individual case needs.<sup>2</sup>

Tooth-borne (Hyrax) and tooth-tissue-borne (Haas) appliances and their modifications have been widely used for maxillary expansion. During expansion, different screw activation protocols have been suggested in the literature and discussions on this issue have been continuing.<sup>3,4</sup>

Studies<sup>5-8</sup> have reported that conventional rapid maxillary expansion (RME) may be hazardous especially to the supporting teeth. Researchers<sup>9</sup> recommend corticotomy in order to overcome the resistance of bony structures in adult patients. However, this can cause extra costs and traumatic procedures for the patient. In an attempt to avoid surgery and reduce or eliminate complications, skeletal anchorage units have recently started to be used for maxillary expansion by orthodontists and a few appliances have already been presented.<sup>10</sup> However, some of these are also supported by teeth additionally and the other choices require some special expansion screws and attachments. This case report presents a simple, cost-effective and totally bone-tissue supported maxillary expansion appliance in an adult patient.

## CASE PRESENTATION

The patient (18-year-old, Caucasian, female) was referred to our faculty due to maxillary constriction. As a result of her clinical examination, the presence of mouth breathing and nail biting habits were detected. Clinical observations showed that she had a symmetrical facial structure and a convex profile. The upper midline was coincident with the facial midline, whereas the lower midline was deviated to the right relative to the face. Angle's Class II molar relationship on the right and Angle's Class I on the left were observed. The patient had bilateral posterior crossbite as seen from the initial diagnostic records (Figure 1). Arch-length deficiency values were -2 mm in the upper and -3 mm in the lower. Overjet was 7.5 mm, and overbite was 0 mm. With the help of the hand-wrist radiograph it was detected that the patient had reached skeletal maturity. Lateral and postero-anterior cephalometric films were analyzed with Dolphin Imaging 11.8 Premium Software program (Dolphin Imaging, Chatsworth, CA, U.S.A.). Diagnostic radiographs are shown in Figure 2. Digital intraoral models and their analyzes were done by using 3Shape Trios 3 Cart (3Shape, Copenhagen, Denmark). The pre and post models and expansion measurements are shown in Figure 3.

Treatment goals set for the patient after clinical examination and analyzes were: first correction of the transversal constriction in the upper jaw, second bringing the teeth to their ideal positions and then optimizing the relationship between jaws. As treatment alternatives: since it was estimated that the amount of maxillary lateral deficiency was beyond the limits of dental expansion and considering the maturation of the patient, rapid maxillary expansion with surgical assistance was planned. However, the patient and her parents were quite concerned about the surgery and asked for a more conservative choice. Therefore it was decided to attempt maxillary expansion with a bone borne appliance<sup>11</sup> and avoid any potential hazardous effects on maxillary premolar and molar teeth. After the treatment method was

explained to the patient, informed consent was obtained and the treatment phase was started.

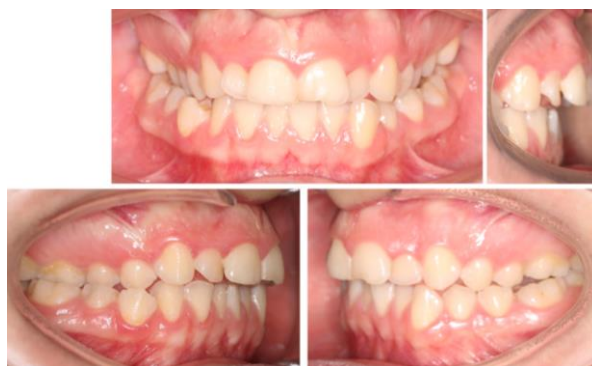

Figure 1. Initial Diagnostic Records.

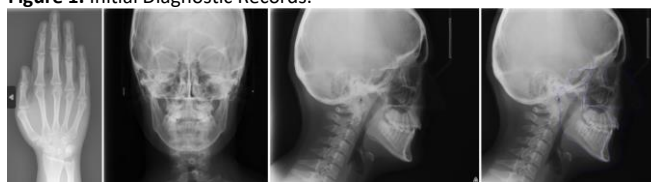

Figure 2. Pre-treatment radiographs.

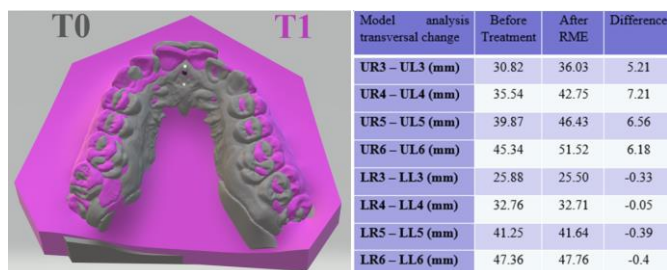


Figure 3. The pre and post models superimposition and expansion measurements.

## Treatment Progress

1. Appliance preparation and application: Four mini screws (Lomas, 2x7 mm, Mondeal, Mühlheim, Germany) were applied to the palatal bone under local anesthesia between the patient's upper first and second premolars and between the upper second premolar and the first molar bilaterally with an angle of 90 degrees to the bone surface. The position of the screws relative to the teeth roots was evaluated by occlusal radiography (Figure 5). Then, a plaster model was obtained and a RME screw (Leone, catalog no: A0620-11, Florence, Italy) was placed on the model and integrated with the mini screws by acrylic resin. (Orthocryl, Dentaurnum, Ispringen, Germany). After trimming and polishing, acrylic-coated expansion screw was attached to the miniscrews in the mouth with a sufficient amount of light cure composite resin bond (3M Unitek Transbond LR, Minnesota, USA). The appliance in situ is shown in Figure 4.
2. Activation of the appliance: The patient and her parents were instructed to activate the appliance one quarter-turn in the morning and the other in the evening. The patient was seen on the day of the 12th activation. Although the signs of sutural opening were observed on the occlusal radiograph (Figure 5). A complete separation between the maxillary bones was not evident. As the

patient was almost an adult, she was told to activate the screw once daily after this control appointment to avoid any complications and the patient was called for control ten days later. In the second control, it was observed that there was a diastema between the central teeth of the patient. Occlusal radiography taken at that visit confirmed complete separation of the maxillary halves.

3. Completion of the activation protocol and consolidation: The RME screw was fixed after 55 turns and the appliance was left in mouth passively for 3 months. At the end of the consolidation period, clinical and radiological records were repeated (Figure 6-8.) Since the aforementioned RME appliance does not interfere with fixed appliances, it can also be left in the mouth as a retention appliance against late relapse. The patient's treatment continues in our clinic with fixed appliances.

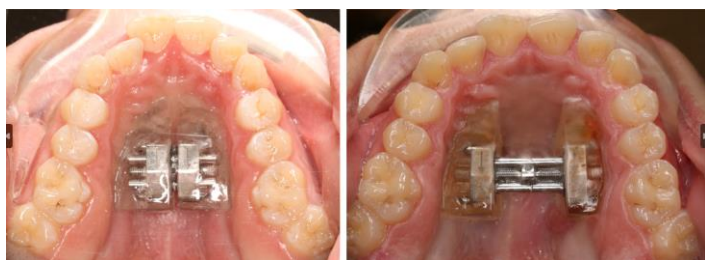

Figure 4. RME appliance applied to the patient's mouth.

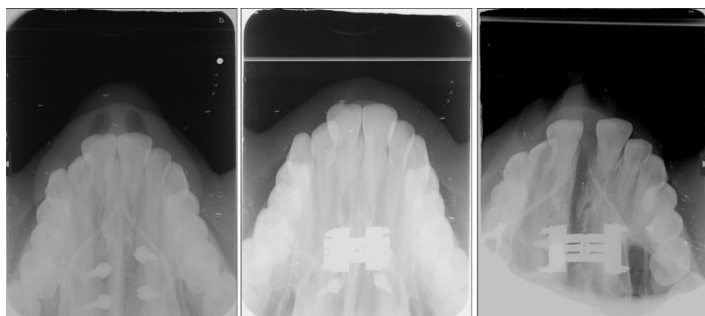


Figure 5. Occlusal radiography recordings taken from the patient.

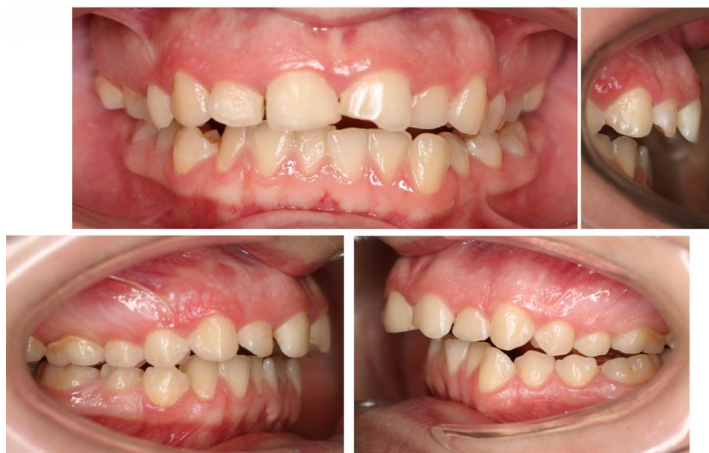

Figure 6. Intraoral photographs at the end of consolidation.

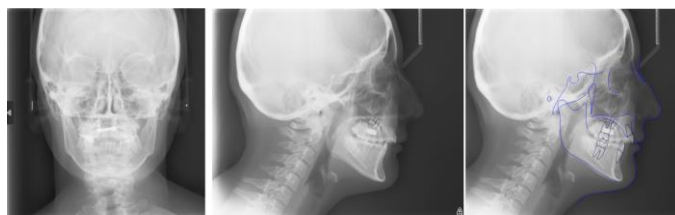

Figure 7. Cephalometric radiographs at the end of consolidation

Cephalometric Analysis	Before Treatment	After RME
SNA (°)	69.5	70.3
SNB (°)	65.7	65.6
ANB (°)	3.8	4.7
SN - GoGn (°)	45.3	47.1
Mandibular Body Length (GoGn)(mm)	73.5	73.6
UI - SN (°)	95.8	90.1
UI - NA (°)	26.3	19.9
UI - NA (mm)	2.9	2.9
L1 - NB (°)	13.9	13.6
L1 - NB (mm)	1.3	1.3
IMPA (L1-MP) (°)	80.0	79.3
Interincisal Angle (U1-L1) (°)	136.8	141.4
Pog - NB (mm)	5.8	5.8
Upper Lip to E-Plane (mm)	-10.3	-5.4
Lower Lip to E-Plane (mm)	-7.4	-6.1
UR6 - Midplane (°)	31.2	30.9
UL6 - Midplane (°)	19.9	20.6
AZ - ZA (mm)	129.6	129.7
JR - JL (mm)	62.4	64.7
UR6 - UL6 (mm)	45.5	51.9

Figure 8. Cephalometric analysis

## DISCUSSION

RME is frequently used in the treatment of transversal maxillary deficiency. Although it has been suggested that the ideal age for this treatment is between 8 and 15 years old, many researchers recommends early intervention.<sup>12</sup> However, an increasing number of young adults and adults appear in the current orthodontic patient population. In order to avoid hazardous effects on supporting teeth, corticotomy is usually recommended to assist the expansion process in adult patients.<sup>9</sup> However, in our case an attempt was made to expand maxilla by a miniscrew-supported custom-made appliance without any surgical intervention or any tooth support. This partially tissue and mostly bone borne appliance was quite successful to separate median sutura and treat bilateral posterior cross bite in an adult patient. The appliance presented here technically resembles Transpalatal Distractor of Mommaerts, but it is less traumatic and easier to apply. This type of

appliance may also be the choice in younger patients with oligodontia and/or periodontally-compromised teeth. As it has nothing to do with teeth, presented appliance allows application of aligners or labial or lingual attachments, and beginning fixed orthodontic treatment during retention period. On the other hand, it does not interfere with effective mouth cleaning during the treatment process. Since any kind of jack screws can be integrated into the appliance and due to the simplicity in its design, production cost is reduced. Also the appliance can easily be produced with CAD-CAM systems eliminating laboratory stages.

Alveolar tipping<sup>7,13</sup>, tipping and extrusion of maxillary posterior teeth<sup>7,13</sup>, clockwise rotation and opening of the mandible<sup>3,4,14</sup>, asymmetric expansion<sup>8</sup>, dehiscence<sup>5</sup> and root resorption<sup>15</sup> have been mentioned among the side effects of tooth-borne and tooth-tissue-borne RME appliances. However, any type of detrimental effects on teeth seems unlikely with our bone-supported appliance. Furthermore, unlike tooth supported expanders, there was almost no molar tipping with the present appliance as measured on postero-anterior radiograph (Figure 8.). This effect may have resulted from the superior position of the screw which is closer to the median suture and rotation center of maxillary halves than tooth-borne appliances. As stated in previous studies<sup>10</sup> bone-supported appliances are more stable than dental-supported appliances and cause less dental side effects.

The form of sutural opening and skeletal effects of the presented appliance are comparable and similar to that of tooth-borne rapid maxillary expansion appliances (Figure 3,8).<sup>4,7</sup> On the other hand, additional cost of four titanium mini screws and mild gingival irritation under the acrylic part may be noted as the handicaps of the appliance. However, presented maxillary expander is promising overall and especially may be an alternative to SARME in adult patients.

## CONCLUSION

In this case report, maxillary expansion was achieved by using a modified RME appliance that was designed to be supported by mini screws without corticotomy in an adult patient. The data (obtained) have shown that the appliance could effectively provide sutural expansion in adult patients without the aid of corticotomy. In addition, it can be an alternative to classical (conventional) RME appliances as it can be applied independently of the teeth.

### Acknowledge

We thank Abdulvahit ERDEM for their support in the treatment planning process.

**Hasta Onamı:** Hastadan bilgilendirilmiş onam alındı

**Hakem Değerlendirmesi:** Dış bağımsız.

**Yazar Katkıları:** Fikir – S.Ç., A.K.; Tasarım – S.Ç., A.K.; Denetleme – S.Ç., A.K.; Kaynaklar – S.Ç., A.K.; Veri Toplanması ve/veya İşlemesi – S.Ç., A.K.; Analiz ve/veya Yorum – S.Ç., A.K.; Literatür Taraması – S.Ç., A.K.; Makaleyi Yazan – S.Ç., A.K.; Eleştirel İnceleme – S.Ç., A.K.

**Çıkar Çatışması:** Yazarlar, çıkar çatışması olmadığını beyan etmiştir.

**Finansal Destek:** Yazarlar, bu çalışma için finansal destek almadığını beyan etmiştir.

**Informed Consent:** Informed consent was obtained from the patient.

**Peer-review:** Externally peer-reviewed.

**Author Contributions:** Concept – S.C., A.K.; Design – S.C., A.K.; Supervision – S.C., A.K.; Resources - S.C., A.K.; Data Collection and/or Processing – S.C., A.K.; Analysis and/or Interpretation – S.C., A.K.; Literature Search – S.C., A.K.; Writing Manuscript – S.C., A.K.; Critical Review – S.C., A.K.

**Conflict of Interest:** The authors have no conflicts of interest to declare.

**Financial Disclosure:** The authors declared that this study has received no financial support.

## REFERENCES

1. McNamara JA. Maxillary transverse deficiency. *Am J Orthod Dentofac Orthoped.* 2000;117(5):567-570.
2. Davidovitch M, Efstathiou S, Sarne O, Vardimon AD. Skeletal and dental response to rapid maxillary expansion with 2-versus 4-band appliances. *Am J Orthodontics Dentofac Orthoped.* 2005;127(4):483-492.
3. Haas AJ. Rapid expansion of the maxillary dental arch and nasal cavity by opening the midpalatal suture. *Angle Orthodontist.* 1961;31(2):73-90.
4. Wertz RA. Skeletal and dental changes accompanying rapid midpalatal suture opening. *Am J Orthod.* 1970;58(1):41-66.
5. Garib DG, Henriques JFC, Janson G, de Freitas MR, Fernandes AY. Periodontal effects of rapid maxillary expansion with tooth-tissue-borne and tooth-borne expanders: a computed tomography evaluation. *Am J Orthod Dentofac Orthoped.* 2006;129(6):749-758.
6. Baysal A, Karadede I, Hekimoglu S, et al. Evaluation of root resorption following rapid maxillary expansion using cone-beam computed tomography. *Angle Orthod.* 2011;82(3):488-494.
7. Garrett BJ, Caruso JM, Rungcharassaeng K, Farrage JR, Kim JS, Taylor GD. Skeletal effects to the maxilla after rapid maxillary expansion assessed with cone-beam computed tomography. *Am J Orthod Dentofac Orthoped.* 2008;134(1):8. e1-8. e11.
8. Alpern MC, Yurosko JJ. Rapid palatal expansion in adults: with and without surgery. *Angle Orthod.* 1987;57(3):245-263.
9. Lines PA. Adult rapid maxillary expansion with corticotomy. *Am J Orthod Dentofac Orthoped.* 1975;67(1):44-56.
10. Mommaerts M. Transpalatal distraction as a method of maxillary expansion. *Brit J Oral Maxillofac Surg.* 1999;37(4):268-272.
11. Çeken G. Kemik destekli ve hibrit apareylerle yapılan hizli üst çene genişletmesinin konik işinli bilgisayarlı tomografi ile karşılaştırılması. Doktora tezi. Atatürk Üniversitesi Diş Hekimliği Fakültesi; 2013.
12. Buccini R, D'antò V, Rongo R, Valletta R, Martina R, Michelotti A. Dental and skeletal effects of palatal expansion techniques: a systematic review of the current evidence from systematic reviews and meta-analyses. *J Oral Rehabil.* 2016;43(7):543-564.
13. Kılıç N, Kiki A, Oktay H. A comparison of dentoalveolar inclination treated by two palatal expanders. *Eur J Orthod.* 2008;30(1):67-72.
14. Basciftci F, Karaman A. Effects of a modified acrylic bonded rapid maxillary expansion appliance and vertical chin cap on dentofacial structures. *Angle Orthod.* 2002;72(1):61-71.
15. Odenrick L, Karlander OD, Eva Lilja, Pierce OD, Angela, FRACDS OD, Kretschmar U. Surface resorption following two forms of rapid maxillary expansion. *Eur J Orthod.* 1991;13(4):264-270.