

Case Report / *Olgu Sunumu*

Sarcoidosis of the Breast

Meme Sarkoidozu

Hayrettin GÖÇMEN, Funda COŞKUN, Şaduman BALABAN ADIM¹, Esra UZASLAN, Oktay GÖZÜ

Departments of Pulmonary Diseases and ¹Pathology, Medicine Faculty of Uludağ University, Bursa

Submitted / Başvuru tarihi: 26.03.2008 **Accepted / Kabul tarihi:** 29.05.2008

Sarcoidosis is a granulomatous disease which might affect many systems. Less than 1% of the cases suffer breast involvement. There are about 33 cases involving breast in the literature. In many cases, systemic symptoms mask breast involvement of sarcoidosis, that was generally recognized in result of surgical operation for malignancy. Breast and skin involvement together is rather rare in sarcoidosis. A 49-year-old female patient with mediastinoscopic diagnosis of sarcoidosis has been followed since 1999. Patient was treated with systemic corticosteroid twice due to skin involvement of sarcoidosis in 2002 and 2004. In 2006 macronodular lesions were found in both of her breast. Nodule excision and reduction mammoplasty were performed with pathological result of non-caseous granulomatous sarcoid inflammation. Patient was admitted as pulmonary sarcoidosis stage II with skin and breast involvement. Since lung, breast and skin involvement together is very rare in sarcoidosis we presented this case.

Key words: Sarcoidosis; breast involvement.

Sarkoidoz etyolojisi bilinmeyen ve tüm organları etkileyebilen sistemik bir hastalıktır. Olguların %1'inden azında meme tutulumu bildirilmiştir. Literatürde meme tutulumu ile ilgili 33 civarında olgu yayınlanmıştır. Bildirilen bu olguların 1/3'ünden azında meme, primer tutulum yeridir. Bu nedenle memedeki tutulumlar öncelikle malignite lehine yorumlanmakta ve yapılan cerrahi örnekleme sonucunda tanı konmaktadır. Sarkoidozda meme ve cilt tutulumu birlikteliği ise çok nadirdir. Mediastinoskopi ile sarkoidoz tanısı konmuş 49 yaşında kadın hasta 1999 yılından beri izlenmekteydi. 2002 ve 2004 yıllarında patoloji ile verifiye cilt tutulumu saptanarak iki kez sistemik kortikosteroid tedavisi almıştı. 2006 Mart ayında her iki meme başında büyük nodüler lezyonlar saptanmıştı. Nodül eksizyonu ve redüksiyon mammoplasti işlemi yapıldı. Histopatoloji sonucu meme sarkoidozu olarak bildirildi. Olgu, meme ve cilt tutulumunun eşlik ettiği akciğer sarkoidozu kabul edildi. Sarkoidozda akciğer, meme ve cilt tutulumunun nadir birlikteliği nedeniyle olgumuzu bildiriyoruz.

Anahtar sözcükler: Sarkoidoz; meme tutulumu.

Sarcoidosis is a multisystemic granulomatous disease with a diverse clinical spectrum of symptoms, that can involve almost any organ.^[1,2] It usually invades the lungs with fibro-

sis and may also involve lymph nodes, skin, liver, spleen, eyes, phalangeal bones, nervous system, locomotor system, lacrimal and salivary glands.^[3,4] Histologically, noncaseating epithe-

lioid cell granulomas in various organs and tissue occur, which undergo either resolution or hyaline fibrosis. Despite being a multisystem disease the breast is rarely affected in sarcoidosis^[1] but when present it may be confused with a malignant neoplasm clinically.^[4]

Herein, we report a patient with pulmonary and skin sarcoidosis who had breast involvement.

CASE REPORT

A 49-year-old female with history of skin and pulmonary sarcoidosis, which had been diagnosed by mediastinoscopic surgery eight years earlier, had been treated for twice in 2002 and 2004, due to aggravation of skin lesions. In 2006, during routine controls of outpatient department nodular lesions were found in both of her breasts. She had no family history of breast cancer or breast disease. The nodular lesions in nipples were soft, movable and nontender. Regional lymph nodes were not palpable. She was referred to plastic and reconstructive surgery for differential diagnosis. Fine needle aspiration cytology was performed and the

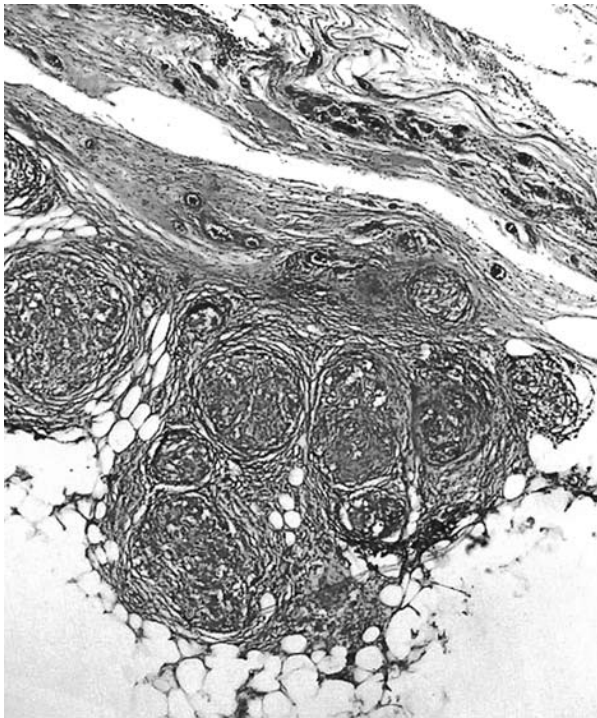


Fig. 1. Noncaseating granulomas in fibrolipomatous breast tissue (H-E x 100).

result was in favor of nonmalignancy. In 2006, the nodular lesions in both of the nipples were resected with the diagnosis of mammomegaly and mammoplasty was performed. Histological examination of the specimen of reduction mammoplasty revealed noncaseous epithelioid cell granulomas with multinuclear giant cells within breast parenchyma (Figs. 1, 2). The final pathological diagnosis was granulomatous mastitis secondary to sarcoidosis.

Chest radiographs and computed tomography showed bilateral hilar lymphadenopathy and recently nodular pulmonary infiltration. The patient was accepted as stage II sarcoidosis with breast involvement and systemic corticosteroid treatment was initiated.

DISCUSSION

Sarcoidosis is a multisystemic granulomatous disease and most commonly affects the lung but extrapulmonary involvements are seen in 40% of the cases.^[5,6] Despite this high percentage of the extrapulmonary effect, sarcoid involvement of the breast is exceedingly unusual and has been extremely rare. Review of the English language literature, which were published by Takahashi et al.^[3] in 2001, have disclosed 29 cases of sarcoid involvement of the breast (mammary sarcoidosis). When we searched the literature since this review, we found only four more breast sarcoidosis that were reported.^[4,7-9] To our knowledge, the present case is the 34th case of sarcoidosis with breast involvement in English literature

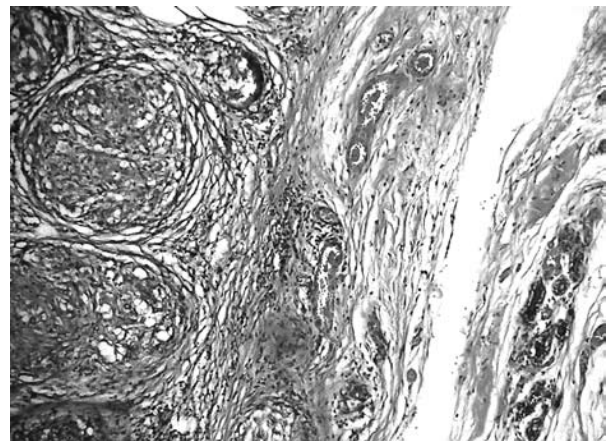


Fig. 2. Noncaseating granulomas in fibrolipomatous breast tissue (H-E x 400).

with English abstract. In 1921, Strandberg was probably the first to allude to the occurrence of sarcoidosis in the breast. The presented case had systemic sarcoidosis and bilateral breast nodules, which are clinically believed to represent sarcoidosis. But sarcoid involvement of the breast was not confirmed.^[3,10] Then the first case of breast sarcoidosis with adequate clinical and histological findings was reported by Scot in 1938.^[3]

There are only three cases with bilateral breast involvement of sarcoidosis in the review of Takahashi et al.^[3] (Strandberg 1921, Shah 1990, and Teuber 1994). In 2007, another bilateral breast involvement of sarcoidosis was notified by Nicholson and Mills.^[9] According to literature our patient is one of the total six cases who had bilateral breast sarcoidosis.

Breast sarcoidosis can often mimic breast carcinoma. Absence of axillary lymph node is in favor of sarcoidosis.^[11] Also excisional biopsy is generally required. The authors indicate that hypersensitivity response against silicone and other strange body can accelerate sarcoid reaction in the breast.^[12] But the present case had neither prior history of breast disease nor silicone gel breast implants. And from the histological findings and bacteriological examinations, granulomatous diseases other than mammary sarcoidosis were excluded, such as granulomatous mastitis, tuberculosis and autoimmune processes.

The patients with breast involvement of sarcoidosis generally complain of palpable masses in their breasts. The sizes of breast masses ranged from 0.5 cm to 8 cm in literature.^[3] There were multiple masses in the breast of our patient with the biggest being 5 cm in diameter.

Ultrasonographic findings of breast sarcoidosis are nonspecific.^[9] The observed findings are often unique or multiple nodular lesions that are difficult to distinguish from malignancy.^[13,14] Like some other breast sarcoidosis patients in literature, fibrocystic disease was revealed in our subject in ultrasonographic examination.

Laboratory findings are not useful for diagnosis of breast sarcoidosis. Serum ACE and lysosime levels, positivity of Kveim test can contribute to diagnosis of sarcoidosis. But in breast involvement this contribution is least.^[15] In our case, serum ACE level was 44.5 mg/dl and was not significant.

Since breast involvement is one of the extrapulmonary manifestations of sarcoidosis, the treatment was applied according to the extrapulmonary manifestations protocol of sarcoidosis.

In conclusion, despite multiorgan effects, breast involvement is extremely rare in sarcoidosis.^[16] Especially if the women with sarcoidosis complain of breast masses, sarcoid involvement should be considered. The exclusion of malignancy is generally necessary.

KAYNAKLAR

1. Banik S, Bishop PW, Ormerod LP, O'Brien TE. Sarcoidosis of the breast. *J Clin Pathol* 1986;39:446-8.
2. Wilhelm K, Teifke A, Müller-Quernheim J, Mitze M. Extrapulmonary manifestation of sarcoidosis in the breast. *Aktuelle Radiol* 1994;4:103-5. [Abstract]
3. Takahashi R, Shibuya Y, Shijubo N, Asaishi K, Abe S. Mammary involvement in a patient with sarcoidosis. *Intern Med* 2001;40:769-71.
4. Fiorucci F, Conti V, Lucantoni G, Patrizi A, Fiorucci C, Giannunzio G, et al. Sarcoidosis of the breast: a rare case report and a review. *Eur Rev Med Pharmacol Sci* 2006;10:47-50.
5. Aladesanmi OA. Sarcoidosis: an update for the primary care physician. *MedGenMed* 2004;6:7.
6. Harris KP, Faliakou EC, Exon DJ, Nasiri N, Gui GP. Isolated sarcoidosis of the breast. *J R Soc Med* 2000;93:196-7.
7. Ishimaru K, Isomoto I, Okimoto T, Itoyanagi A, Uetani M. Sarcoidosis of the breast. *Eur Radiol* 2002;12 Suppl 3:S105-8.
8. Mona el K, Pascal C, Charley H, Françoise B, Véronique B, Marie-Madeleine P. Quiz case. Breast sarcoidosis presenting as a metastatic breast cancer. *Eur J Radiol* 2005;54:2-5.
9. Nicholson BT, Mills SE. Sarcoidosis of the breast: An unusual presentation of a systemic disease. *Breast J* 2007;13:99-100.
10. Strandberg J. Contribution á la question de la clinique et de la pathogénie de la sarcoïde de Boeck. *Acta Derm Venerol* 1921;2:252-61.
11. Donaldson BA, Polynice A, Oluwole S. Sarcoidosis of the breast: case report and chart review. *Am Surg* 1995;61:778-80.
12. Teuber SS, Howell LP, Yoshida SH, Gershwin ME. Remission of sarcoidosis following removal of silicone gel breast implants. *Int Arch Allergy Immunol*

- 1994;105:404-7.
13. Kirshy D, Gluck B, Brancaccio W. Sarcoidosis of the breast presenting as a spiculated lesion. *AJR Am J Roentgenol* 1999;172:554-5.
 14. Gisvold JJ, Crotty TB, Johnson RE. Sarcoidosis presenting as spiculated breast masses. *Mayo Clin Proc* 2000;75:293-5.
 15. Studdy PR, Lapworth R, Bird R. Angiotensin-converting enzyme and its clinical significance--a review. *J Clin Pathol* 1983;36:938-47.
 16. Ross MJ, Merino MJ. Sarcoidosis of the breast. *Hum Pathol* 1985;16:185-7.