



Calvarial Hyperostosis Syndrome in an American Pit Bull Terrier

Amerikan Pit Bull Terrier bir Köpekte Calvarial Hiperosteozis Sendromu

Damla HAKTANIR¹ , Ebru ERAVCI YALIN² , Yalçın DEVECİOĞLU² , Alper DEMİRUTKU² , Aydın GÜREL¹ 

¹Department of Pathology, Istanbul University Faculty of Veterinary Medicine, Istanbul, Turkey

²Department of Surgery, Istanbul University Faculty of Veterinary Medicine, Istanbul, Turkey

Cite this article as: Haktanır, D., Eravcı Yalın, E., Devocioğlu, Y., Demirutku, A., Gürel, A., 2008. Calvarial Hyperostosis Syndrome in an American Pit Bull Terrier. Acta Vet Eurasia 44: 49-52

ORCID IDs of the authors: D.H. 0000-0001-5171-1927; E.E.Y. 0000-0002-0941-6745; Y.D. 0000-0002-8175-2321; A.D. 0000-0001-5788-1660; A.G. 0000-0002-0266-8771.

Abstract

Calvarial hyperostosis syndrome (CHS), which has been recently defined in juvenile dogs, is a rare, non-neoplastic, proliferative bone disease characterized by the swelling of the skull. Until recently, it was mostly reported in young Bullmastiffs with a sexual preference for male dogs. The objective of this study was to describe the clinical and pathological aspects of the condition as a contribution to literature due to its rarity in dogs. The paper presents the first reported case of Calvarial hyperostosis in turkey. A four-month-old female American Pit bull terrier was presented to the veterinary physician with the complaints of painful swelling on the head, loss of appetite, lethargy and fever. Radiograph of the skull revealed diffuse thickening

of the frontal and parietal bones and markedly increased bone opacity, and magnetic resonance imaging (MRI) scans revealed increased diploe thickness in all sequences. The preliminary clinical diagnosis of calvarial hyperostosis was confirmed by histopathology which revealed the presence of both immature woven bone and mature bone trabeculae separated by prominent basophilic cementing lines. The lesion is self-limiting, and most cases show spontaneous regression in few months, but in this case the patient was monitored until one year of age and no regression was seen.

Keywords: Calvarial hyperostosis, histopathology, clinical findings

Öz

Kalvarial Hiperosteozis (KHO) son yıllarda genç köpeklerde tanımlanmış olan ve nadir olarak görülen kafatası kemiğinde şişme ile karakterize neoplastik olmayan proliferatif bir kemik hastalığıdır. Bu hastalık daha çoğunlukta genç erkek Bull Mastiff larda bildirilmiştir. Çalışmada, Literatürde köpeklerde nadir olarak bildirilen bu sendromun klinik ve patolojik yönleriyle açıklanması amaçlanmıştır. Bu makale Köpeklerde Kalvarial Hiperosteozis konusunda Türkiyede ilk yayındır. Dört aylık dişi bir Amerikan Pit Bull Terrier köpek yüksek ateş, iştahsızlık, durgunluk ve kafada ağrılı şişlik şikayeti ile kliniğe getirildi. Kranium'un radyografik incelemesinde frontal ve parietal kemik-

lerde yaygın kalınlaşma ve kemik opazitesinde belirgin artış, manyetik rezonans (MR) görüntülenmesinde tüm kesitlerde diploe mesafesinde artış saptandı. Klinik olarak kalvarial hiperosteozis olduğu düşünülen bu olgu, histopatolojik inceleme ile doğrulandı. Mikroskopik incelemede ortamda geniş-kalın trabeküllerden oluşan kompakt bir kemik yapısı saptandı. Kemikğin tam olgunlaşmamış woven kemik ile olgunlaşmış trabeküllerden oluştuğu ve bu iki kemik yapısı arasında bazofilik görünümde belirgin bir sement hattı saptandı.

Anahtar kelimeler: Kalvarial hiperosteozis, histopatoloji, klinik bulgular

Address for Correspondence: Aydın Gürel - E-mail: agurel@istanbul.edu.tr

Received Date: 13 June 2017 - Accepted Date: 23 October 2017 - DOI: 10.5152/actavet.2018.009

© Copyright 2018 by Official Acta Veterinaria Eurasia. Available online at www.dergipark.gov.tr/iuvf



This work is licensed under a Creative Commons Attribution-NonCommercial 4.0 International License.

Introduction

Calvarial Hyperostosis Syndrome (CHS) is a recently defined rare osteopathy characterized by non-neoplastic proliferation of the flat bones of the skull (Pastor et al., 2000; McConnell et al., 2006; Mathes et al., 2012). Clinically and histologically, it resembles craniomandibular osteopathy and infantile cortical hyperostosis in humans (Pastor et al., 2000; Huchkowsky, 2002; Kamoun-Goldrat and Le Merrer, 2008; Varollo et al., 2012). Calvarial hyperostosis syndrome has been reported mostly in Bullmastiffs and case reports are available with respect to the presence of the disease in a Pit Bull Terrier and an English Springer Spaniel dog (Pastor et al., 2000; McConnell et al., 2006; Thompson et al., 2011; Mathes et al., 2012). The most prominent clinical manifestations are painful swelling of the skull bones, lymphadenopathy, eosinophilia and fever (Muir et al., 1996; Pastor et al., 2000; Thompson et al., 2011). Seizures, hydrocephalus, lameness and osteomyelitis are additional symptoms (Pastor et al., 2000; Thompson et al., 2011; Mathes et al., 2012).

To our knowledge, this is the first reported case of a dog with Calvarial Hyperostosis Syndrome in Turkey and we aimed to describe this case with its clinical and pathological aspects as a contribution to literature due to its rarity in dogs (Pastor et al., 2000; McConnell et al., 2006; Mathes et al., 2012) and to inform veterinary practitioners regarding the disease.

Case

A four-month-old female American Pit bull terrier was referred to the clinic of the Faculty of Veterinary Medicine, Department of Surgery with complaints of painful swelling to the head, loss of appetite, lethargy and fever. Clinical inspection revealed firm bilateral swelling of the parietal and frontal bones of the skull and diffuse edema extending to the right upper eyelid. (Figure 1a). Radiography of the skull revealed diffuse thickening of the frontal and parietal bones and markedly increased bone opacity (Figure 1b). Magnetic resonance imaging scans revealed increased diploe thickness in all sequences. No pressure related distortions were observed on the brain parenchyma (Figure 1c).

No abnormalities were observed on routine biochemical screening tests or in the hemogram and the dog tested negative for ca-

nine distemper virus, parvovirus and coronavirus using immunochromatographic assay. In addition, a biopsy sample was taken from the bone tissue for histopathological evaluation.

The patient was monitored until one year of age and the swelling in the lesioned area was observed to have enlarged and expanded. Symptomatic treatment was prescribed including steroids and nonsteroidal anti-inflammatory drugs to relieve pain. She was reported to have died at the age of 14 months due to poor care.

Bone biopsy samples harvested from the lesioned area were initially fixed in 10% formalin solution for 36 hours and then kept in a 5% nitric acid solution for 48 hours for decalcification. After routine tissue processing protocols, the specimens were embedded in paraffin, cut to a thickness of 4-5 μ m and stained with Hematoxylin and Eosin. Histopathologically, compact bone tissue composed of thickened trabeculae was observed in the sections. The bone trabeculae consisted of two structures: immature woven bone and mature trabeculae (Figure 2a). The trabeculae appeared thickened with narrowed medullary spaces which were replaced by highly vascular intermediate fibrosis and a few osteoblastic and osteoclastic cells were also seen (Figure 2b). Prominent basophilic cement lines were noted between these two structures (Figure 3a, b).

Discussion

Calvarial Hyperostosis Syndrome, which has recently been defined in juvenile dogs, is a non-neoplastic bone disease characterized by the swelling of the skull (Pastor et al., 2000; McConnell et al., 2006; Mathes et al., 2012). This syndrome has been most commonly reported in Bullmastiffs (Pastor et al., 2000; McConnell et al., 2006), and occasionally, in other breeds (Thompson et al., 2011; Mathes et al., 2012). This is the first reported case of canine CHS in a Pit Bull Terrier with its clinical, radiological and histopathological aspects in Turkey.

This condition was reported only in juvenile dogs and whether or not gender affects susceptibility to the disease is still a matter of debate (Pastor et al., 2000; McConnell et al., 2006; Mathes et al., 2012). In the presented case, the disease was encountered in a 4-month-old female Pit Bull. Clinical signs of the disease

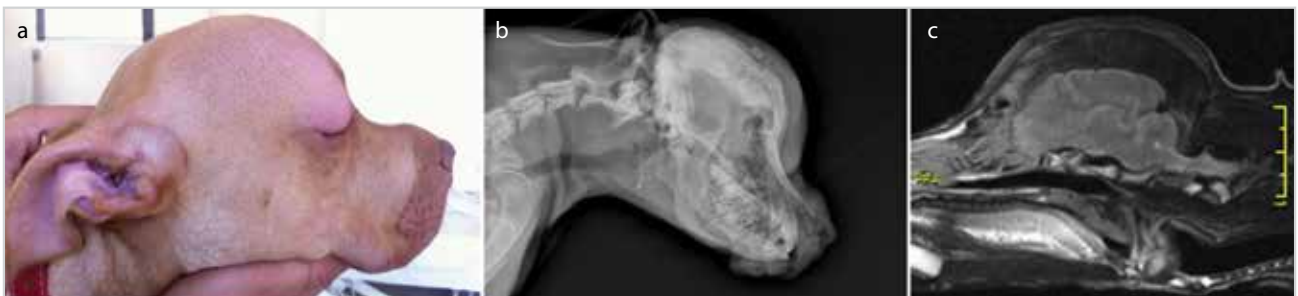

Figure 1. a-c. (a) Calvarial swelling with hyperemia on the forehead and edema on the right upper eyelid. Firm asymmetrical swelling on the frontal and parietal bones of the skull. (b) Lateral radiograph of the skull. Diffuse sclerotic areas, cortical thickening, loss of trabecular structure and irregular periosteal reaction on the dorsal region of the calvaria. (c) Sagittal T2 weighted MR imaging scan of the skull. An enlarged diploe due to regular thickening of the trabecular bone tissue

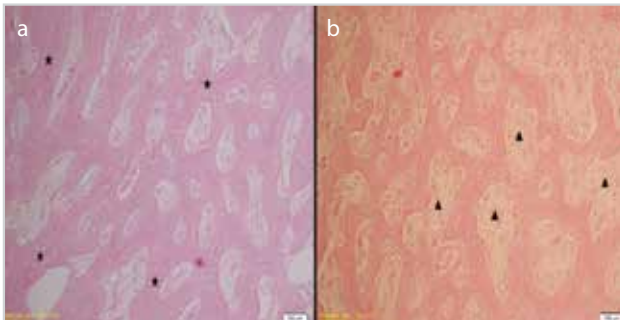


Figure 2. a, b. (a) Bone tissue composed of thickened trabeculae (star). H. E. Bar=100µm. (b) Intermediate fibrosis (arrow head) within the medullary spaces and a few osteoblastic and osteoclastic cells. H.E. Bar=100µm.

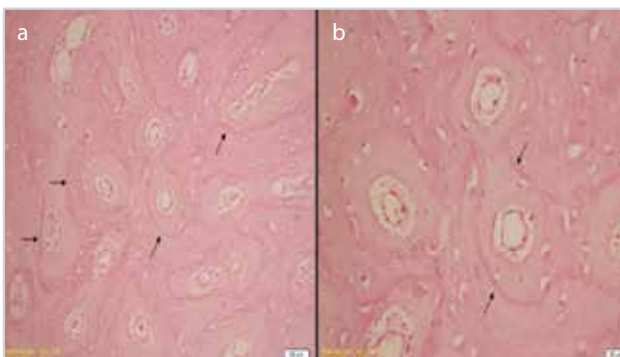


Figure 3. a, b. Prominent basophilic cementing lines (arrows) between mature and immature bone tissue. H.E. Bar=A.50 µm B.20 µm

included painful swelling of the skull bones, lymphadenopathy, eosinophilia and fever (Muir et al., 1996; Pastor et al., 2000; Thompson et al., 2011). Hydrocephalus, lameness and purulent osteomyelitis were also reported (Pastor et al., 2000; Thompson et al., 2011; Mathes et al., 2012). No other symptoms except for bilateral swelling of the parietal and frontal bones of the skull and fever were detected in the presented case.

Calvarial Hyperostosis Syndrome is a rare condition in dogs and it has been most commonly reported in young Bullmastiff dogs (Pastor et al., 2000; McConnell et al., 2006). The clinical and histopathological traits of the syndrome resemble those of canine craniomandibular osteopathy (Alexander, 1983; Gülanber et al., 2001; Huchkowsky, 2002) and human infantile cortical hyperostosis (Kamoun-Goldrat and Le Merrer, 2008). The anatomic location of the lesion is of great importance in the differential diagnosis (McConnell et al., 2006; Mathes et al., 2012). In the presented case, the lesion was diagnosed as calvarial hyperostosis since the lesion developed bilaterally in the parietal and frontal regions of the skull and there was no evidence of mandibular involvement on the basis of clinical and radiographic findings.

It has been reported that there was prominent periosteal and subperiosteal inflammation in the bone tissue in the cases of

calvarial hyperostosis (Pastor et al., 2000; Thompson et al., 2011; Mathes et al., 2012). No signs of inflammation were detected in the presented case. After the initial referral to the clinic, the patient was administered 2 mg/kg methylprednisolone sodium succinate (Prednol, Mustafa Nevzat Drug Industry, Turkey) and 2 mg/kg carprofen (Rimadyl, Zoetis) twice a day in view of the fact that the painful swelling on the head might have resulted from the inflammatory response in the soft tissues and temporary pain relief was achieved with this treatment. However, radiography and a bone tissue biopsy confirmed that the condition was hyperostosis. The lack of inflammatory reaction in the biopsy sample was associated with the long-term use of steroid and nonsteroidal anti-inflammatory drugs. De Heer et al. (2015) reported that inflammatory changes correlated with the phase of the disease at the time of the biopsy. Histopathologically, calvarial hyperostosis is characterized by periosteal proliferation of the parietal and frontal bones and correspondingly thickening of these bones. (Pastor et al., 2000; McConnell et al., 2006; Thompson et al., 2011; Mathes et al., 2012). In the presented case, radiography and magnetic resonance imaging revealed asymmetrical calvarial thickening. Characteristic microscopic findings in hyperostosis included the development of new bone tissue, which appeared as marked thickening of the trabecular structures in the zone, and correspondingly, the narrowing of centrally located bone marrow spaces replaced by a highly vascular fibrous tissue and the presence of prominent basophilic cement lines between these thick, newly formed trabeculae and the mature bone tissue (McConnell et al., 2006; Thompson et al., 2011). Our findings were compatible with those of the above-mentioned reports. Clinically and histopathologically, calvarial hyperostosis may occasionally be confused with osteoma since it is a localized bone growth. It is usually easy to differentiate the entity by careful microscopic evaluation. In osteomas, the spaces between the trabeculae are larger with the occasional presence of bone marrow elements and there is very scanty fibrous tissue (Milli and Hazıroğlu, 1997). In contrast, in hyperostosis, these spaces are narrow and contain large amounts of highly vascular fibrous tissue. Newly formed trabeculae appear thickened and basophilic cement lines are prominent (McConnell et al., 2006; Thompson et al., 2011). However, in osteomas, newly formed bone trabeculae are thin and cementing lines are not visible.

The etiology of calvarial hyperostosis is still unknown. Possible roles of Prostaglandin E1 and E2 have been suggested in some studies, in which elevated levels of serum prostaglandin E was detected in some children with infantile cortical hyperostosis, which is a similar disease to that found in humans in terms of clinical and histopathological aspects. It was reported in the same studies that collagen disorders might also have played a role in the onset of the disease (Gensure et al., 2005; Glorieux, 2005). Therefore, we consider that further detailed studies should be carried out to elucidate the causes in the etiology of canine calvarial hyperostosis.

Most cases of calvarial hyperostosis appear to be of a self-limiting nature. Once the bone tissue reaches maturity, the lesions may regress. Therefore, no specific treatment has been indicated.

In some incidents, the lesions were grossly and histopathologically confused with osteomyelitis and, thus, antibiotics were prescribed (Thompson et al., 2011). Nonsteroidal anti-inflammatory drugs were administered in some cases to inhibit inflammation and to relieve pain (De Heer et al., 2015). In the presented case, pain relief and resolution of edema were achieved using steroids and nonsteroidal antiinflammatory drugs. However, no regression was observed and the lesion continued to grow.

References

- Alexander, J.W., 1983.** Selected skeletal dysplasias: craniomandibular osteopathy, multiple cartilaginous exostoses and hypertrophic osteodystrophy. *Veterinary Clinics of North America: Small Animal Practice* 13, 55-70. [\[CrossRef\]](#)
- De Heer, N., Maltha, J.H.J., Van Garderen, E., 2015.** Calvarial hyperostosis syndrome in a young Weimaraner dog. *Vlaams Diergeneeskundig Tijdschrift* 84, 154-157.
- Gensure, R.C., Makite, O., Barclay, C., 2005.** A novel COL1A1 mutation in infantile cortical hyperostosis (Caffey disease) expands the spectrum of collagen-related disorders. *Journal of Clinical Investigation* 115, 1250-1257. [\[CrossRef\]](#)
- Glorieux, F.H., 2005.** Caffey disease: an unlikely collagenopathy. *Journal of Clinical Investigation* 115, 1142-1144. [\[CrossRef\]](#)
- Gülenber, E.G., Özer, K., Gürel, A., 2001.** Doberman Irkı Bir Köpekte KranioMandibular Osteopati. *İstanbul Üniversitesi Veteriner Fakültesi Dergisi* 27(2), 393-400.
- Huchkowsky, S.L., 2002.** Craniomandibular osteopathy in a bullmastiff. *The Canadian Veterinary Journal* 43(11), 883-885.
- Kamoun-Goldrat, A., Le Merrer, M., 2008.** Infantile cortical hiperostosis (Caffey disease): a review. *Journal of Oral and Maxillofacial Surgery* 66, 2145-2150. [\[CrossRef\]](#)
- Mathes, R.L., Holmes, S.P., Coleman, K.D., Radlinsky, M.A., Moore, P.A., 2012.** Calvarial hyperostosis presenting as unilateral exophthalmos in a female English Springer Spaniel. *Veterinary Ophthalmology* 15(4), 263-270. [\[CrossRef\]](#)
- McConnell, J.F., Hayes A., Platt S.R., Smith K.C., 2006.** Calvarial Hyperostosis syndrome in two bullmastiffs. *Veterinary Radiology and Ultrasound* 47(1), 72-77. [\[CrossRef\]](#)
- Milli, Ü., Hazıroğlu, R., 1997.** Veteriner Patoloji 1. Cilt; 3. Bölüm, Kemik hastalıkları, Sayfa; 399-403., Tamer Matbaacılık, DemetEvler, Ankara
- Muir, P., Dubielzig, R.R., Johnson, K.A., Shelton, G.D., 1996.** Hypertrophic osteodystrophy and calvarial hyperostosis. *Compendium on Continuing Education for the Practicing Veterinarian* 18, 143-151.
- Pastor, K.F., Boulay, J.P., Schelling S.H., Carpenter, J.L., 2000.** Idiopathic hyperostosis of the calvaria in five young bullmastiffs. *Journal of the American Animal Hospital Association* 36(5), 439-445. [\[CrossRef\]](#)
- Thompson, D.J., Rogers, W., Owen, M.C., Thompson, K.G., 2011.** Idiopathic canine juvenile cranial hyperostosis in a Pit Bull Terrier. *New Zealand Veterinary Journal* 59(4), 201-205. [\[CrossRef\]](#)
- Varallo, G.R., Lima, B.R., Raposo, T.M.M., Daleck, C.R., 2012.** Craniomandibular osteopathy in English Bulldog. *Arsive Veterinaria, Jaboticabal, SP* 28(4), 218-221.