

Single Incision Laparoscopic Splenectomy: Our First Experiences

Umut Barbaros¹, Aziz Sümer², Ahmet Dinççağ², Burçin Batman¹, Selçuk Mercan¹, Ridvan Seven¹, Budak Demir¹

¹Department of General Surgery, Faculty of Medicine, İstanbul University, İstanbul, Turkey

²Department of General Surgery, Kaş State Hospital, Antalya, Turkey

ABSTRACT

Objective: Most laparoscopic surgeons have attempted to reduce incisional morbidity and improve cosmetic outcomes by using less and smaller trocars. Single incision laparoscopic splenectomy is a new laparoscopic procedure. Herein we would like to present our experiences.

Material and Methods: Between January 2009 and June 2009, data of the 7 patients who underwent single incision laparoscopic splenectomy were evaluated retrospectively.

Results: There were 7 patients (5 females and 2 males) with a mean age of 29.9 years. The most common splenectomy indication was idiopathic thrombocytopenic purpura. Single incision laparoscopic splenectomy was performed successfully in 6 patients. In one patient the operation was converted to an open procedure.

Conclusion: With surgeons experienced in minimally invasive surgery, single incision laparoscopic splenectomy could be performed successfully. However, in order to demonstrate the differences between standard laparoscopic splenectomy and SILS splenectomy, prospective randomized comparative studies are required.

Key Words: Single incision, laparoscopy, splenectomy

Received: 08.07.2009

Accepted: 15.10.2009

Introduction

Beginning with the first laparoscopic appendectomy performed by K. Semm (1) in 1983, advanced laparoscopic surgery has become an increasingly common practice as a result of technological developments, surgical curiosity, and medical ambition (2-4). In the past 30 years, laparoscopic interventions have been used in various fields for treatment of many malignant and benign diseases (4). Currently, laparoscopy is preferred as an alternative to open surgery due to its low complication rates, less postoperative pain, achievement of better cosmetic results, and quicker return of patients to their daily lives (4, 5).

Efforts aiming to reduce the morbidity of laparoscopic surgery have recently been gaining speed. Therefore, investigators have begun to perform the procedures via natural orifices or by single incision laparoscopic surgery instead of using the conventional laparoscopic surgery. In our clinic, the first transvaginal colecystectomy practices (NOTES: Natural orifice transluminal endoscopic surgery) have been conducted by Seven and Barbaros (6). Moreover, since 2009, single incision laparoscopic surgery (SILS) practice has been performed in our clinic. The single incision laparoscopic splenectomy (SILSp) technique was first described by Barbaros and Dinçcag (7).

The aim of this study is to present the experiences of our clinic in single incision laparoscopic splenectomy and share the initial results.

Materials and Methods

We retrospectively evaluated the data of seven patients who had been exposed to SILSp between January and June 2009 in the Department of General Surgery, Faculty of Medicine, İstanbul University. The parameters of the study included age, gender, spleen size, operation length (from the first incision to the closure), blood loss, transfusion level, indications for conversion to open surgery, pain score, complications, and length of hospital stay. Complications were classified as intraoperative and postoperative. During their hospital stay, pain of all the patients were scored based on the Visual Analog Scale. All patients were vaccinated with Pneumovax 23 (Merck&Co. Inc., Whitehouse Station, NJ, USA) 2 weeks prior to the operation and antibiotic prophylaxis (1g intravenous ampicillin-sulbactam) was applied. The patients were operated on under general anesthesia. The entire series of operations were conducted by the same team led by UB. Postoperative analgesia was established with PCA (patient controlled analgesia). All the patients received the same nonsteroid antiinflammatory agents (8 mg intravenous lornoxicam, twice a day) and narcotic analgesics (50 mg intramuscular pethidine, twice a day).

Surgical Technique

Patients were placed in a semilateral position while elevating the left side 30°. The surgeon and the assistant using the camera stood at the patient's side. The operation was begun with a skin incision of approximately 2 cm size through the umbilicus. 12 mmHg CO₂ pneumoperitoneum was established by CO₂ insufflation with a Verres needle. In the first 4 cases, 3 ports with 5mm size were placed and finally at the stapler stage in the splenic hilum, one of the ports was replaced with a 15mm port and the operation was resumed (Fig. 1). In the last three cases, operations were conducted with a special SILS™ port (Covidien, Mansfield, MA), specifically designed for SILS (Fig. 2). A 5mm telescope with a 30° angle was used. The patient was placed in the reverse Trendelenburg position towards the right side. Firstly, abdominal exploration was carried out to determine the accessory spleen. Following placement of instruments into the abdomen, the basic mechanism is similar to that in 3-port laparoscopic procedures. The most difficult part of this technique is to work with roticulated instruments crossing each other. Ligasure™ (Valleylab division of Tyco Healthcare, Mansfield, MA) was used during most of the dissection. The inferior pole and medial splenogastric ligament dissection was followed by splenorenal and superior pole dissection. Splenic artery and splenic vein were ligated with Ligasure™ or endovascular stapler (Fig. 3), and cut. The liberated spleen was placed into a special sterile nylon bag (endobag) and morcellated before removal. An aspirative drain was placed in splenectomy lodge routinely.

Results

Mean age of the patients was 29.9 years, and the male/female ratio was 5/2. The most common splenectomy indication was idiopathic thrombocytopenic purpura. None of the cases showed mortality. In one case, we were forced to convert to open surgery due to hemorrhage in the splenic artery as a result of failure to fire the stapler. Spleen sizes varied between 11.7-15 cm. Blood loss between 50-200 cc occurred. While the shortest operation duration was 60 minutes, the longest was 125 minutes. Splenectomy indications and demographic characteristics are shown in Table 1, and intraoperative blood loss, pain scores on day 1 and 3, hospital stay length, daily drainage levels, and drain removal times of the cases are shown in Table 2. No wound infection was observed in the abdomen postoperatively and there was perfect cosmetic appearance (Fig. 4).

Discussion

While the practice of the first laparoscopic cholecystectomy by Philippe Mouret (6) in 1987 has been recognized as a breakthrough in surgery in its time, today, less than 20 years after this historical achievement, laparoscopic surgery methods performed through a single incision or natural orifices have begun to replace it. SILS and NOTES are novelties that herald the beginning of a new era in surgery (8, 9).

Although SILS practice is relatively new, it has already been applied in many surgical procedures by ambitious surgeons who always look for the best option. Many procedures such as

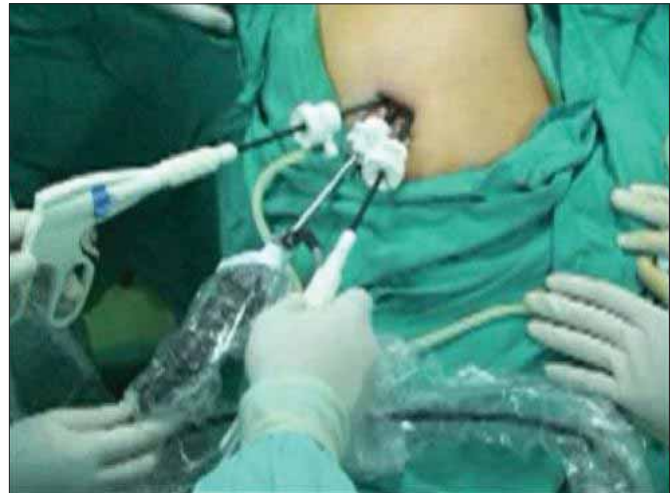

Figure 1. Transumbilical three 5 mm trocars

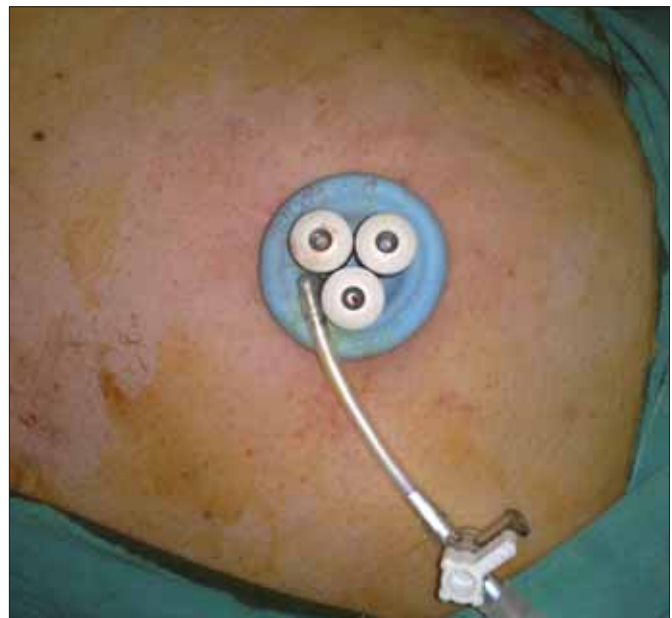

Figure 2. Special SILS trocar

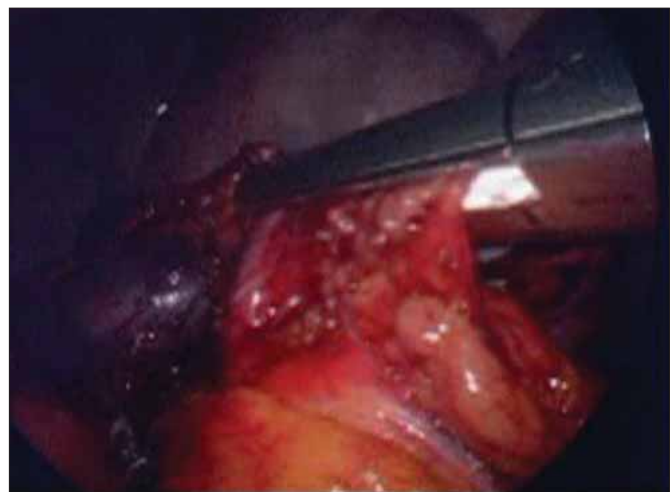


Figure 3. Hilum ligation with an endoscopic vascular stapler

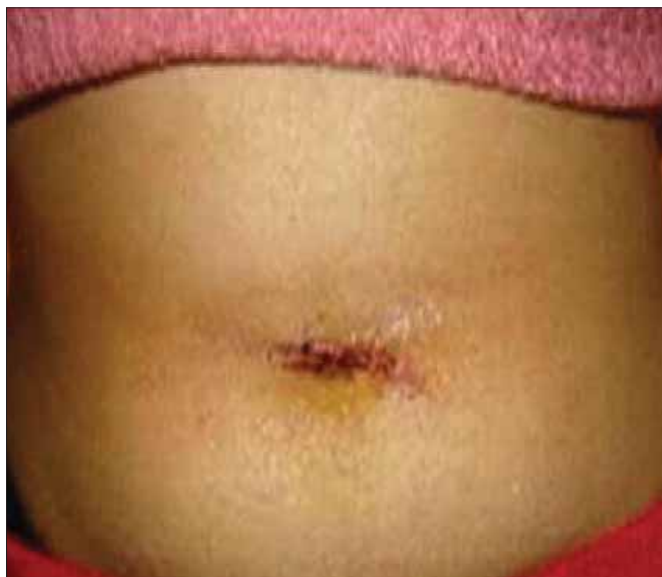

Figure 4. View of the umbilicus postoperatively

Table 1. Demographic characteristics and diagnoses of the splenectomized cases

No	A/S	SS	Diagnosis
1	28/K	11.9	ITP
2	40/E	15	TTP
3	28/E	11.9	ITP
4	32/K	11.7	ITP
5	22/K	11.9	ITP
6	31/K	12.1	ITP
7	28/K	13.4	ITP

cholecystectomy, adrenalectomy, laparoscopic total extraperitoneal inguinal hernia repair, right hemicolectomy, left hemicolectomy, rectal operations, sleeve gastrectomy, gastrojejunostomy, and nephrectomy have been performed through single incision and reported in the world literature (2, 10-14). The first SILS practice in the world has been performed in our clinic (7). The most important question about SILS procedures is whether or not they have any superiority over three-port practices other than the better cosmetic results.

Hodgett et al. (15) recommended single incision cholecystectomy in cases having a normal anatomy and uncomplicated gall bladder pathologies. They conducted a study in which 29 cases subjected to multiport laparoscopic cholecystectomy were compared with 29 cases subjected to single incision laparoscopic cholecystectomy, and single incision laparoscopic cholecystectomy was found to be a safe alternative for standard laparoscopic cholecystectomy. Apart from the reliability and practicability, this technique has further advantages such as less postoperative pain, patient satisfaction, and fine cosmetic appearance.

The practice of minimally invasive splenectomy history started with Delaitre in 1991 and the range of application widened to include massive splenomegaly cases (16). Regarding minimally invasive surgeries, operations performed with three trocars have been thought to be the best achievable practice. Together with our laparoscopic splenectomy experience, use of SILS on solid organs such as in nephrectomy led to the concept that we could employ this method in splenectomy. Consequently, we performed the technique and reported the first SILS cases in the world (7). Single incision laparoscopy presents several advantages over standard laparoscopy. It is certain that although SILS uses angled instruments, it is a harder practice compared with the standard laparoscopic techniques. However, we are at the beginning of a new road

Table 2. Surgical data of the splenectomized cases

No	LO	BL	Transfusion	LS	D	C	COA	VAS
1	85	200	2 U PSA	4	F:200 S:25 T:10	No	No	F:2 T:1
2	120	Abundant	2 U PSA + 2 U ES	5	0	Hemorrhage	Yes	F:5 T:2
3	105	50	2 U PSA	2	F:75	No	No	F:2
4	115	50	2 U PSA	4	F:200 S:50 T:20	No	No	F:2 T:1
5	100	70	2 U PSA	3	F:80 S:40	No	No	F:2 T:1
6	125	75	2 U PSA	3	F:90 S:30	No	No	F:2 T:2
7	60	50	2 U PSA	2	F:70	No	No	F:2 T:1

Abbreviations: A/S: age and sex, SS: spleen size (cm), LO: length of operation (minutes), BL: blood loss (cc), PSA: platelet suspension prepared by method of apheresis ES: erythrocyte suspension LS: length of hospital stay (day), D: drain volume (cc), F: first day, S: second day, T: third day, C: complications, COA: conversion to open approach, VAS: visual Analog Scale

and have to learn many things. We believe, as our experiences accumulate, practices will be easier and the technological advances will increase the comfort of surgeons. In the current study, operation durations were reduced as a result of our higher experience level and use of SILS-specific ports in the last cases. The longest duration of operation was 125 minutes, whereas the operation length in our last case was 60 minutes.

In conclusion, we believe that SILS is as effective as conventional laparoscopic splenectomy in the hands of surgical teams with adequate experience in minimally invasive surgery. Although SILS yields a better cosmetic outcome, further prospective randomized studies are required in order to reveal the superiority of SILS over multiport standard laparoscopic splenectomy.

Conflict of Interest

No conflict of interest was declared by the authors.

References

1. Semm K. Endoscopic appendectomy. *Endoscopy* 1983;2:59-64. [\[CrossRef\]](#)
2. Langwieler TE, Nimmesgern T, Back M. Single-port access in laparoscopic cholecystectomy. *Surg Endosc* 2009;5:1138-41. [\[CrossRef\]](#)
3. Brodsky JA, Brody FJ, Walsh RM, Malm JA, Ponsky JL. Laparoscopic splenectomy. *Surg Endosc* 2002;5:851-4. [\[CrossRef\]](#)
4. Maartense S, Bemelman WA, Gerritsen van der Hoop A, Meijer DW, Gouma DJ. Hand-assisted laparoscopic surgery (HALS): a report of 150 procedures. *Surg Endosc* 2004;3:397-401. [\[CrossRef\]](#)
5. Irwin BH, Rao PP, Stein RJ, Desai MM. Laparoendoscopic single site surgery in urology. *Urol Clin North Am* 2009;2:223-35. [\[CrossRef\]](#)
6. Seven R, Barbaros U. Needloskopi yardımlı transvaginal kolelistektomi: İlk Ulusal N.O.T.E.S deneyimi. *Ulusal Cerrahi Dergisi* 2009;1:29-32.
7. Barbaros U, Dinççağ A. Single Incision Laparoscopic Splenectomy: The First Two Cases. *J Gastrointest Surg* 2009. [Epub ahead of print] [\[CrossRef\]](#)
8. Chamberlain RS, Sakpal SV. A Comprehensive Review of Single-Incision Laparoscopic Surgery (SILS) and Natural Orifice Transluminal Endoscopic Surgery (NOTES) Techniques for Cholecystectomy. *J Gastrointest Surg* 2009. [Epub ahead of print] [\[CrossRef\]](#)
9. Mouret P. How I developed laparoscopic cholecystectomy? *Ann Acad Med Singapore* 1996;25:744-7.
10. Filipovic-Cugura J, Kirac I, Kulis T, Jankovic J, Bekavac-Beslin M. Single-incision laparoscopic surgery (SILS) for totally extraperitoneal (TEP) inguinal hernia repair: first case. *Surg Endosc* 2009;4:920-1. [\[CrossRef\]](#)
11. Merchant AM, Cook MW, White BC, Davis SS, Sweeney JF, Lin E. Transumbilical Gelpport access technique for performing single incision laparoscopic surgery (SILS). *J Gastrointest Surg* 2009;1:159-62. [\[CrossRef\]](#)
12. Bucher P, Pugin F, Morel P. Transumbilical single-incision laparoscopic intracorporeal anastomosis for gastrojejunostomy: case report. *Surg Endosc* 2009;7:1667-70. [\[CrossRef\]](#)
13. Reavis KM, Hinojosa MW, Smith BR, Nguyen NT. Single-laparoscopic incision transabdominal surgery sleeve gastrectomy. *Obes Surg* 2008;11:1492-4. [\[CrossRef\]](#)
14. Bucher P, Pugin F, Morel P. Single port access laparoscopic right hemicolectomy. *Int J Colorectal Dis* 2008;10:1013-6. [\[CrossRef\]](#)
15. Hodgett SE, Hernandez JM, Morton CA, Ross SB, Albrink M, Rosemurgy AS. Laparoendoscopic single site (LESS) cholecystectomy. *J Gastrointest Surg* 2009;2:188-92. [\[CrossRef\]](#)
16. Delaitre B, Bonnichon P, Barthes T, Dousset B. Laparoscopic splenectomy. The "hanging spleen technique" in a series of nineteen cases. *Ann Chir* 1995;6:471-476. French.