

# Morphometric Development of Sphincter of Oddi in Human Fetuses During Fetal Period: Microscopic Study

Kadir Desdicioğlu<sup>1</sup>, Kemal K. Bozkurt<sup>2</sup>, Ceren Uğuz<sup>3</sup>, E. Hilal Evcil<sup>4</sup>, Mehmet A. Malas<sup>1</sup>

<sup>1</sup>Department of Anatomy, Faculty of Medicine, İzmir Katip Çelebi University, İzmir, Turkey

<sup>2</sup>Department of Pathology, Faculty of Medicine, Süleyman Demirel University, Isparta, Turkey

<sup>3</sup>Department of Anatomy, Faculty of Medicine, Süleyman Demirel University, Isparta, Turkey

<sup>4</sup>Vocational School of Health, Mehmet Akif Ersoy University, Burdur, Turkey

## ABSTRACT

**Objective:** In this study, morphometric developments of the sphincter of Oddi in human fetuses were observed.

**Material and Methods:** We observed 113 human fetuses consisting of 67 male and 46 female subjects, whose ages varied between 14 to 40 weeks who showed no signs of any pathology or anomaly externally. The common external measurements of fetuses were carried out, followed by abdominal dissection to determine where the sphincters of Oddi were localized within the duodenum and pancreas. Histological specimens of tissue samples were gathered from the inner wall of the duodenum where it was assumed that the sphincters of Oddi had been localized. The parameters of total external diameters, lumen diameters, wall thickness, diameters of ductus choledochus and ductus pancreaticus, and the distance between these two structures, which are also known as the origins of the sphincter of Oddi, were measured by using a light microscope. The standard deviations of the measurements were calculated for each gestational week and trimester.

**Results:** The calculations suggested that there were statistically significant correlations between gestational age and all of the other parameters with the exception of the ductus choledochus ( $p < 0.001$ ). It was observed that the wall thickness of the ductus choledochus increased at the first half of the fetal stage and decreased at the second half, as the lumen diameter increased through the 40th week. The gender difference was not statistically significant ( $p > 0.05$ ).

**Conclusion:** The data we collected in our study were considered as useful for the evaluation of the development of the sphincter of Oddi area and fetal stage.

**Key Words:** Sphincter of Oddi, human fetus, morphometry, microscopy, fetal development

Received: 14.11.2012

Accepted: 15.02.2012

## Introduction

The sphincter of Oddi is derived from its location between the ductus choledochus and the ductus pancreaticus anatomically (1-4). Oddi in 1887 and Dardinski in 1935 mentioned this fact in their studies (2, 3). Additionally, Bosch et al. (2) confirmed that in 1930, while Boyden also pointed out the sphincter of Oddi belonged to the ductus choledochus and ductus pancreaticus in fetal materials. Moreover, it was noted that the sphincter of Oddi that belonged to ductus choledochus and the ductus pancreaticus developed at the ventral wall of the anterior intestine 5 weeks after the development of the muscle tissue of the duodenum (2, 5).

Studies on adults suggested that the length of the ductus choledochus and ductus pancreaticus were 10 mm. and 6 mm. respectively, while the thickness of the ductus choledochus sphincter was 6 mm (6). Mahour et al. (7) noted that the diameter of the ductus choledochus within the duodenum was 7.39 mm, its radius was 14.99 mm and its thickness was 1.1 mm in length in adults. Dowdy et al. (8) also measured the length of the ductus choledochus as 4.4 mm and its diameter as 2.6 mm within the duodenum.

Ishibashi et al. (3) pointed out that Boyden divided the sphincter of Oddi histologically into four groups: sphincter of Choledochus superior, sphincter of Choledochus inferior, sphincter of the Ampulla and sphincter of Pancreaticus. Additionally, they also suggested that the sphincters might be divided into three topographical groups, as extramucosal, intramucosal, and submucosal sphincters. Topographical classification was proven to be useful in endoscopic sphincterotomy and in endoscopic papillar balloon dilatation operations in clinical researches (3, 9, 10). Moreover, it was noted that endoscopic operations were considered as being easier at the submucosal region, whereas the operations on the sphincters at any other area would cause complications (3, 9-11).

The function of the sphincter of Oddi is described as a regulator of bile and pancreatic enzyme ingredient, to enable bile to be stored in the gall bladder and to keep duodenal contents within it (3, 4, 12). It is known that there are both pathological effects such as papillary stenosis, sclerosing papillitis, biliary spasm and congenital anomalies like double bile duct which cause dysfunction of the sphincter of Oddi (3, 4, 13). Additionally, dysfunctions in the sphincter of Oddi are obser-

ved more frequently among women compared to men and it is also noted that both biliary and pancreatic systems may fail as a result of the dysfunctions in the sphincter of Oddi (3, 4, 13).

In this study, we aimed to obtain more detailed morphometric data about both the ductus choledochus and the ductus pancreaticus, which give rise to the sphincter of Oddi, by retrieving histological tissue samples and observing them under the light microscope on a wider scale.

## Material and Methods

### Subject

The study comprised of 113 fetuses (67 males, 46 females) at a gestational age of 14-40 weeks; the fetuses were obtained from the prenatal period or after abortion. All were spontaneous abortions or stillbirths and neonatal deaths (died because of premature or prenatal asphyxia) obtained from Isparta Maternity and Paediatric Hospital during 1996-2005 period. In order to use the fetuses as experimental materials, the signed consents were obtained from the families; the experimental procedures were ethically appropriate in terms of the official laws and regulations imposed by the Turkish Ministry of Health. The fetuses with external pathology or anomalies and those cases with anomalies (omphalocele, gastroschisis, diaphragm hernia, Meckel diverticulum, colon malposition, renal agenesis, ectopic kidneys, agenesis of external genitalia, etc.) discovered on dissection were excluded from the study. Approval from the Ethics Board of the School of Medicine, Suleyman Demirel University, was obtained prior to the commencement of the study.

### Including and Excluding Criteria

The fetal ages were determined based on the crown-rump length (CRL), bi-parietal diameter (BPD), head circumference (HC), femur length (FL), and foot length (14). Fetal stage was divided into three groups: the fetuses whose ages were 14-25 weeks as group 1 (second trimester), 26-37 weeks as group 2 (third trimester), and 38-40 weeks as group 3 (full term).

The macroscopic measurements in this study were taken with a measuring cylinder, a plastic ruler, a composing stick, a silk suture, a miter and scaled compasses.

First, all of the fetal materials were dissected by anatomic abdomen dissection from the umbilicus through to linea axillaris media with a transverse incision, followed by the incision on the linea axillaris media through to arcus costarius and crista iliaca level with a ventral incision. The stomach, liver and transverse colon were also dissected to visualize the pancreas and duodenum.

### Microscopic Examination of Tissue Specimens

The sphincters of Oddi locations were determined at the duodenum, where the histological samples were gathered for light microscopy observation. Each sample was buried in paraffin blocks which their surface connected to the duodenum duct facing downward after the routine histological sample retrieval methods had been done. The tissue sample sections of 5 micrometer in thickness were produced from the inner wall of the duodenum to the pancreas. There were 7 to 10 slides

taken randomly from each paraffin block for visualization and they were stained with hematoxylin-eosin, and then observed under the light microscope (Olympus CX41RF) (15, 16).

We measured the parameters of total external diameters, lumen diameters, wall thickness diameters of ductus choledochus and ductus pancreaticus including tunica serosa, tunica muscularis, and tunica mucosa as well as the distance between these two structures under the microscope in the value of the ocular micrometer for each fetus (Table 1, Figure 1). The measurements were assessed both horizontally and vertically by an ocular micrometer similar to the protocol followed in the previous studies (15, 16).

### Statistical analysis

The means and standard deviations of the parameters were calculated for each gender, gestational age, and the groups mentioned earlier, by using SPSS. The nominal alpha level for the statistical significance was set at  $p < 0.05$ . The calculated values for each group were shown as means  $\pm$  standard deviations. Since the sample size was not large enough in some groups, some related non-parametric tests were performed. First, the Kruskal-Wallis analysis of variance test was done.

The groups that indicated statistically meaningful results were analyzed with Mann-Whitney U test in pair-wise comparisons. After the determination of their significance level, the comparisons were made based on the nominal alpha level with Bonferroni correction. The linear association between the parameters and the gestational age was investigated by computing Pearson's correlation coefficients. Next, Student's t-tests and Mann-Whitney U tests, where applicable, were performed to make pair-wise comparisons of the groups. The calculated p values and other findings are shown in tables.

## Results

The abdomen of each fetal material was dissected utilizing the anatomic dissection technique. The duodenum and pancreas were visualized. Then, the locations of the sphincter of Oddi at the duodenum were determined. The samples taken from 113 fetuses were observed after the histological sampling techniques had been completed. It was noted that the samples from 26 fetuses were not adequate for observations, leaving us with 87 of fetuses to work with. The parameters of total external diameters, lumen diameters, wall thickness diameters of ductus choledochus and ductus pancreaticus including tunica serosa, tunica muscularis and tunica mucosa and the distance between these two structures were measured (Table 1). The means and standard deviations for gestational weeks were shown in Table 1 and Table 2, respectively. It was observed that the association between the groups and gestational age was statistically significant ( $p < 0.001$ ) with the exception of ductus choledochus wall thickness. The gender groups indicated no statistically significant difference ( $p > 0.05$ ). Although the ductus choledochus total diameter and the distance between ductus choledochus and ductus pancreaticus in group 2 (third trimester) and group 3 (full term) were not significantly different from each other, the other groups were found to be significantly different ( $p < 0.05$ , Table 2).

Table 1. The mean parameters obtained from microscopic images of sphincter of Oddi, by gestational weeks ( $\mu\text{m}$ )

Week	n	Ductus choledochus total external diameter	Ductus choledochus lumen diameter	Ductus pancreaticus total external diameter	Duct pancreaticus lumen diameter	Ductus choledochus total wall thickness	Ductus pancreaticus total wall thickness	Distance between ductus choledochus and ductus pancreaticus
14	2	1552	687	556	256	864	299	975
15	2	1712	716	610	290	996	320	1050
16	6	1833	824	663	312	1009	350	1178
17	5	2000	963	698	343	1036	354	1369
18	2	2058	1002	724	367	1056	356	1440
19	4	2193	1085	755	396	1108	359	1553
20	4	2301	1143	787	426	1158	361	1638
21	2	2337	1174	827	454	1163	373	1737
22	3	2380	1208	868	484	1172	383	1824
23	4	2394	1262	901	513	1132	387	1868
24	6	2434	1340	941	544	1093	396	1919
25	7	2461	1398	985	577	1063	407	1967
26	4	2481	1437	1022	610	1043	412	1993
27	7	2509	1481	1063	647	1027	415	2028
28	2	2528	1509	1107	673	1018	434	2087
29	1	2543	1533	1145	702	1010	442	2125
30	5	2563	1563	1179	733	1000	446	2154
31	4	2584	1593	1220	764	991	455	2192
32	2	2601	1620	1265	796	981	469	2232
33	1	2613	1659	1303	814	954	488	2250
34	2	2625	1677	1344	844	947	499	2277
35	1	2639	1700	1387	867	939	519	2300
36	2	2647	1727	1426	896	920	530	2323
37	2	2668	1763	1474	922	905	551	2348
38	2	2680	1790	1513	950	890	563	2375
39	2	2711	2002	1545	977	709	567	2394
40	3	2720	2015	1583	1004	705	578	2413

Table 2. The mean parameters ( $\mu\text{m}$ ) and standard deviations obtained from microscopic images of sphincter of Oddi with respect to groups

Group (Trimester)	n	Ductus choledochus total external diameter	Ductus choledochus lumen diameter	Ductus pancreaticus total external diameter	Ductus pancreaticus lumen diameter	Ductus choledochus wall thickness	Ductus pancreaticus wall thickness	Distance between ductus choledochus and ductus pancreaticus
1. group (weeks 14-25)	47	2188±275	1113±226	804±131	434±104	1074±71	370±28	1602±323
2. group (weeks 26-37)	33	2563±58	1569±99	1193±140	737±97	993±42	455±43	2149±116
3. group (weeks 38-40)	7	2706±18	1947±107	1552±32	981±24	759±89	571±10	2397±17
Total (weeks 14-40)	87	2372±289	1353±331	1012±276	593±208	1018±106	418±69	1873±390

$p < 0.05$ : assumed for all differences among all groups (exceptions: Ductus choledochus total external diameter, Distance between ductus choledochus and ductus pancreaticus groups: 2.-3.)

## Discussion

The sphincter of Oddi has the function of regulating bile in the digestive system (3, 4). It is known that there are both pathological effects such as papillary stenosis, sclerosing papillitis, biliary spasm, and congenital anomalies like double bile duct which cause dysfunction of the sphincter of Oddi (3, 4, 13). It is also known that both biliary and pancreatic systems may fail as a result of the dysfunctions in the sphincter of Oddi and the dysfunction occurs more frequently among women compared to men (3, 4, 13). Thus, it is crucial to know the emergence of the sphincter of Oddi for early diagnosis of any pathological or anatomical anomalies.

There has been no detailed description found about the morphometry of the sphincter of Oddi at the fetal stage. The studies provided us the parameters of the ductus choledochus and ductus pancreaticus lengths, wall thicknesses and diameters in adults (6-8). In this study, we produced histological samples of the sphincter of Oddi and observed them under the light microscope. However the muscle formation and thickness of the ductus choledochus and ductus pancreaticus could not be observed because of the undetermined borders

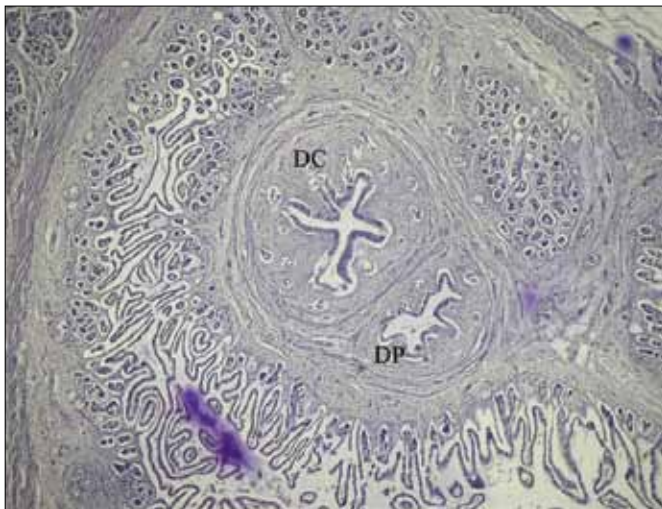


Figure 1. The sphincter of Oddi sample taken from a 26 week old female fetus

DC: Ductus choledochus, DP: Ductus pancreaticus, (H&Ex120)

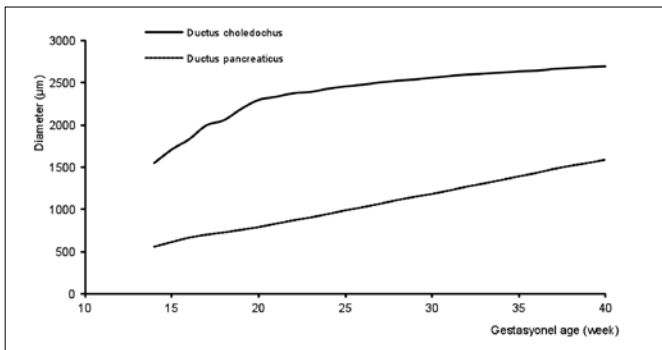


Figure 2. The development of total external diameters of the ductus choledochus and the ductus pancreaticus during fetal stage

of these areas. In this study, we measured the parameters of total external diameters, lumen diameters, wall thickness diameters of ductus choledochus, and ductus pancreaticus as well as the distance between these two structures under the microscope for each gestational week during the fetal stage (Figure 1, Table 1 and 2).

We observed that the total external diameter of the ductus choledochus had increased until the third trimester and it almost stopped at full term. Based on the aforementioned observation, we can confidently say that the development of the ductus choledochus continues until the end of the third trimester. We observed that the total external diameter of the ductus pancreaticus increased constantly in the fetal stage (Figure 2). Accordingly, we concluded that the development of the ductus pancreaticus continued at the postnatal stage. The lumen diameter of the ductus choledochus increased from the third trimester to full term (Figure 3). Therefore, it was thought that the ductus choledochus lumen diameter had increased after the third trimester, depending on the start of bile production at the 12<sup>th</sup> week and the bile flow to the duodenum after the 13<sup>th</sup> week (17, 18). The lumen diameter of the ductus pancreaticus increased during the fetal stage (Figure 3). As a result, we concluded that the lumen diameter of the ductus pancreaticus increased during the postnatal stage. The wall thickness of the ductus choledochus increased until the third trimester, then started to decrease through to full term (Figure 4). The reason for the decrease was believed to be the continuing increase of the total external diameter of the ductus choledochus until the third trimester and increase in the lumen of the ductus choledochus depending on the beginning of bile flow. The wall thickness of the ductus pancreaticus increased constantly during the fetal stage (Figure 4). As a result we thought that the wall thickness of ductus pancreaticus increased during the postnatal stage. The distance between ducts increased up to the start of the third trimester. However, we cannot say that the increase in question kept a statistically meaningful level after the third trimester (Figure 5).

It is crucial to know the pathological and anatomical issues about the sphincter of Oddi for early diagnosis and treatment at the fetal stage. Therefore, knowledge of the anatomy of the sphincters provides us with great advantage for clinical issues. Apart from previous studies on the sphincter of Oddi, we utilized anatomical dissection and histological section gathering

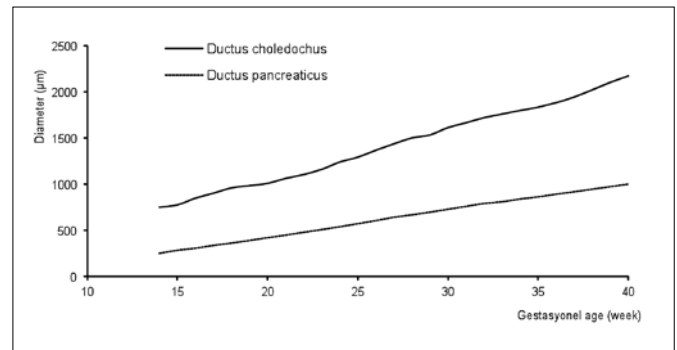
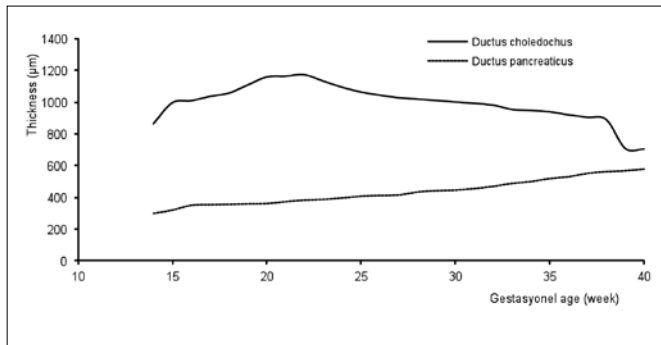
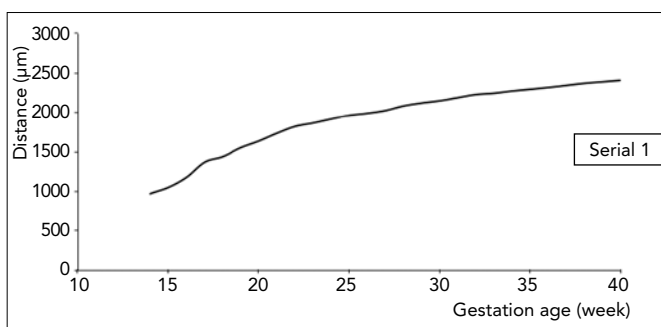


Figure 3. The development of the lumen diameter of the ductus choledochus and the ductus pancreaticus during fetal stage



**Figure 4.** The development of the wall thickness of the ductus choledochus and the ductus pancreaticus during the fetal stage



**Figure 5.** The development of the distance of the ductus choledochus and the ductus pancreaticus during the fetal stage

methods, which had been used for larger scale observations. The findings of this study should be used prior to observation with obstetric ultrasonography at the intrauterine stage. We assume that the early diagnosis and treatment of anomalies that occurred at the sphincter of Oddi will be easier if the morphometric measurements of the sphincter of Oddi are more detailed.

## Conclusion

Consequently, we believe that the data we gathered would help in describing the variations, anomalies and pathological issues during the fetal stage, as well as contributing to the information for the scientific community of obstetrics, perinatology, forensics and fetal pathology.

## Conflict of Interest

No conflict of interest was declared by the authors.

## References

1. Avisse C, Flament JB, Delattre JF. Ampulla of Vater. Anatomic, embryologic, and surgical aspects. *Surg Clin N Am* 2000;80:201-12. [\[CrossRef\]](#)
2. Bosch A, Peña LR. The sphincter of oddi. *Dig Dis Sci* 2007;52:1211-8. [\[CrossRef\]](#)
3. Ishibashi Y, Murakami G, Honma T, Sato TJ, Takahashi M. Morphometric study of the sphincter of oddi (hepatopancreatic) and configuration of the submucosal portion of the sphincteric muscle mass. *Clin Anat* 2000;13:159-67. [\[CrossRef\]](#)
4. Woods CM, Mawe GM, Toouli J, Saccone GT. The sphincter of Oddi: understanding its control and function. *Neurogastroenterol Motil* 2005;17 Suppl 1:31-40. [\[CrossRef\]](#)
5. Ando H. Embryology of the biliary tract. *Dig Surg* 2010;27:87-9. [\[CrossRef\]](#)
6. Papamiliades M, Rettori R. Muscular structure of choledochopancreato-duodenal juncture. *Acta Anat (Basel)* 1957;30:575-600. [\[CrossRef\]](#)
7. Mahour GH, Wakim KG, Ferris DO. The common bile duct in man: its diameter and circumference. *Ann Surg* 1967;165:415-9. [\[CrossRef\]](#)
8. Dowdy GS Jr, Waldron GW, Brown WG. Surgical anatomy of the pancreatobiliary ductal system. Observations. *Arch Surg* 1962;84: 229-46. [\[CrossRef\]](#)
9. Mathuna PM, White P, Clarke E, Merriman R, Lennon JR, Crowe J. Endoscopic balloon sphincteroplasty (papillary dilation) for bile duct stones: efficacy, safety, and follow-up in 100 patients. *Gastrointest Endosc* 1995;42:468-74. [\[CrossRef\]](#)
10. Minami A, Nakatsu T, Uchida N, Hirabayashi S, Fukuma H, Morshed SA, et al. Papillary dilation vs sphincterotomy in endoscopic removal of bile duct stones. A randomized trial with manometric function. *Dig Dis Sci* 1995;40:2550-4. [\[CrossRef\]](#)
11. Bergman JJ, Rauws EA, Fockens P, Van Berkel AM, Bossuyt PM, Tijssen JG, et al. Randomised trial of endoscopic balloon dilation versus endoscopic sphincterotomy for removal of bile duct stones. *Lancet* 1997;349:1124-9. [\[CrossRef\]](#)
12. Horiguchi S, Kamisawa T. Major duodenal papilla and its normal anatomy. *Dig Surg* 2010;27:90-3. [\[CrossRef\]](#)
13. Djuranovic SP, Ugljesic MB, Mijalkovic NS, Korneti VA, Kovacevic NV, Alempijevic TM, et al. Double common bile duct: a case report. *World J Gastroenterol* 2007;13:3770-2.
14. Moore KL, Persaud TVN. *The Developing Human (Clinically Oriented Embryology)*, 7th edn. WB Saunders Company, Philadelphia, 2003; pp 264-6.
15. Howard CV, Reed MG. *Unbiased Stereology, Three-Dimensional Measurement in Microscopy*. BIOS Scientific Publisher, Oxford, 1998; pp 39-68.
16. Koyuncu E, Malas MA, Albay S, Cankara N, Karahan N. The development of fetal pylorus during the fetal period. *Surg Radiol Anat* 2009;31:335-41. [\[CrossRef\]](#)
17. Albay S, Malas MA, Koyuncu E, Evcil EH. Morphometry of the gallbladder during the fetal period. *Surg Radiol Anat* 2010;32:363-9. [\[CrossRef\]](#)
18. Sadler TW. *Langman's Medical Embryology*. 11th edn. Lippincott Williams & Wilkins, 2010; p 220.