

## A two-headed accessory muscle on the sole of the foot

Hatice EFEKAN<sup>1</sup>, Elif ZEREN<sup>2</sup>, Nermin YASINOGLU<sup>2</sup>, Ural VERIMLI<sup>2</sup>, Yasin ARIFOGLU<sup>3</sup>, Ozlem KIRAZLI<sup>2</sup>

<sup>1</sup> Department of Anatomy, School of Medicine, Eastem Mediterranean University Mersin, Turkey

<sup>2</sup> Department of Anatomy, School of Medicine, Marmara University, Istanbul, Turkey

<sup>3</sup> Department of Anatomy, School of Medicine, Bezmialem Foundation University, Istanbul, Turkey

**Corresponding Author:** Ozlem KIRAZLI

**E-mail:** ozlemsarioz@gmail.com

**Submitted:** 22.07.2024

**Accepted:** 26.09.2024

### ABSTRACT

Anatomical variations include the absence of a muscle or tendon or its presence as an accessory muscle or tendon. Clinically, anatomic variations play an important role in diagnosis and therapy.

In anatomy dissection laboratory, during routine dissection for educational purposes, a 83 -year- old male cadaver was dissected and a two-headed accessory muscle was observed on the plantar surface of the left foot.

The medial and lateral heads of the muscle were observed close to the medial and lateral plantar neurovascular bundles. The accessory muscle was pierced by the tendon of the flexor digitorum longus muscle and both muscles were inserted to the distal phalanx of the fifth toe.

The variations of the accessory muscles should be taken into consideration in surgical interventions, since, they may change the course of the intervention or as in the case of abductor hallucis muscle, they may be used in reconstructive procedures as grafts. Therefore, it is crucial for surgeons, orthopedic physicians, and anatomists to have a detailed knowledge of the intrinsic muscles of the foot.

**Keywords:** Accessory muscle, Variation, Plantar surface

### 1. INTRODUCTION

The general anatomy of the plantar region muscles is well known and well-studied in the literature. Apart from the general muscular layer divisions, plantar muscle groups may be divided into central and peripheral muscle groups to clarify surgical approaches. In the peripheral group of muscles, there are medial and lateral groups, and these muscles insert into the proximal phalanges [1]. On the other hand, the central group comprises numerous muscles such as flexor digitorum brevis (FDB), quadratus plantae (QP), lumbricals, plantar interossei, and dorsal interossei. Additionally, the central group is divided into a superficial layer, which inserts into the middle phalanges, and a deep layer which inserts into the distal phalanges [2,3].

Flexor digitorum brevis splits into four tendons that run to the lateral four toes; the flexor digitorum longus (FDL) tendons

lay deep to the tendons when they enter the digital tendinous sheaths. Each tendon splits around the matching FDL tendon at the bases of the proximal phalanges. The two slip then reconnect and partially decussate, generating a tunnel through which the FDL tendon passes to reach the distal phalanges. The FDB tendon splits again and joins to the middle phalanx's shaft on both sides [2]. The common variations in the literature are related to the lumbricals, dorsal interossei, FDB, and extensor digitorum brevis (EDB) muscle and the presence of accessory muscles. These variations may raise questions about the functional effects on the gait and tarsometatarsal joint. A study focused on the variable attachments of the plantar interosseus muscles on a female cadaver's sole [4].

**How to cite this article:** Efehan H, Zeren E, Yasinoglu N, Verimli U, Arifoglu Y, Kirazli O. A two-headed accessory muscle on the sole of the foot. *Marmara Med J* 2024; 37(3):389-392. doi: 10.5472/marumj.1572334

<http://doi.org/10.5472/marumj.1572334>  
**Marmara Med J** 2024;37(3): 389-392

The intrinsic muscle variations of the sole of the foot are rarely encountered [5], but the presence of these variations may provide crucial information for clinical interventions such as flat foot reconstructions in the plantar region of the foot since, the variative anatomy would impact the clinical approach.

The variations of the intrinsic muscles of the foot, particularly those associated with the medial longitudinal arch, may influence the function and stability of the foot. For instance, the cross-sectional areas of abductor hallucis longus and the flexor hallucis brevis medial part can affect the muscle strength and postural balance [6].

Additionally, these variations may be related to nerve entrapments such as the medial plantar nerve entrapment observed in the variations of abductor hallucis and adductor hallucis muscles [7].

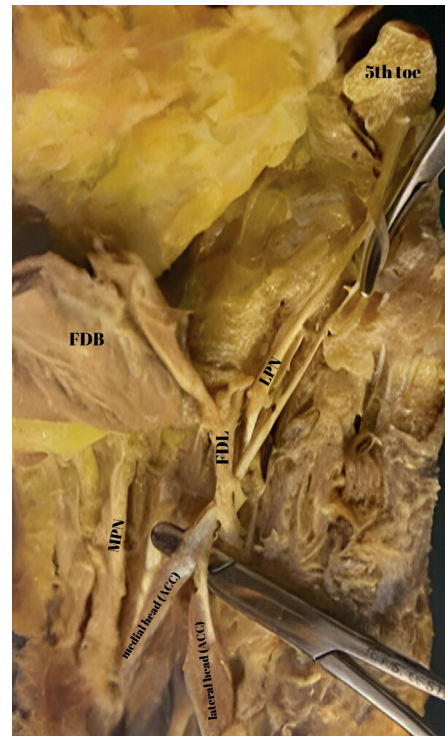
In this case report, a two-headed accessory muscle observed on the plantar surface of the foot during cadaver dissection and its relationship with the neuromuscular bundle is presented. To the best of our knowledge, this report is the first presentation of such a variation.

## 2. CASE-REPORT

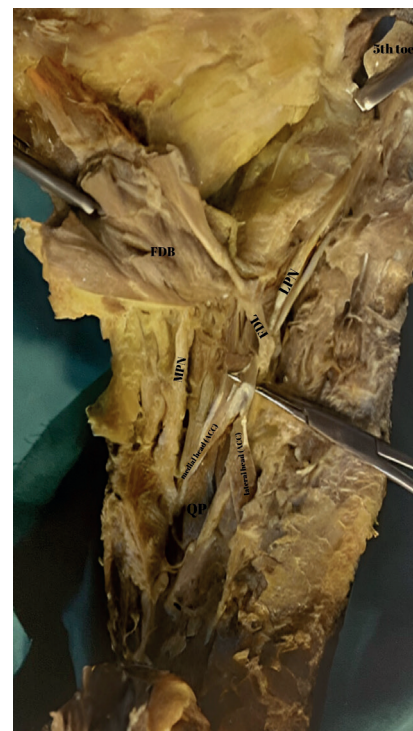
An unusual variation in the intrinsic muscles of the foot was coincidentally discovered in an 83-year-old male, 10% formalin embalmed cadaver, during a demonstrational foot dissection session for undergraduate and postgraduate studies in the cadaver dissection laboratories of the institution.

During routine cadaver dissection, a two-headed accessory muscle was observed on the plantar surface of the left foot. Each dissection process was carried out in accordance with Grant's Dissector [8]. The skin, superficial fascia, plantar aponeurosis and FDB, were dissected, in that order. Detailed observations and measurements were made for the accessory muscle, including its origin, course, and insertion.

The medial head of the accessory muscle was observed to be originating from the FDL muscle, whereas the lateral head from the flexor digiti minimi brevis muscle (Figures 1,2). Both medial and lateral heads of the muscle were coursing close to the medial and lateral plantar neurovascular bundles. The accessory muscle was pierced by the tendon of the FDL muscle. Both muscles were inserted into the distal phalanx of the fifth toe (Figure 2). The length of the muscle and its tendon was approximately 108.85 mm and 67.18 mm, respectively.



**Figure 1.** ACC: Accessory muscle, MPN: Medial plantar nerve, LPN: Lateral plantar nerve, FDB: Flexor digitorum brevis muscle FDL: Flexor digitorum longus muscle



**Figure 2.** QP: Quadratus plantae muscle, ACC: Accessory muscle, MPN: Medial plantar nerve, LPN: Lateral plantar nerve, FDB: Flexor digitorum brevis muscle FDL: Flexor digitorum longus muscle

### 3. DISCUSSION

Accessory muscles have been identified as a possible source of clinical complaints, although, they are usually asymptomatic and discovered coincidentally [5]. Examples of accessory muscles in literature have anthropological significance as well as the ability to strengthen the parent muscle and be used as replacement flaps in tendon injuries. Tendon transfer of the FDL or flexor hallucis longus on the plantar surface of the foot is necessary to treat both Achilles tendon rupture and dysfunction of the posterior tibial tendon. To execute this surgical technique as effectively as possible, foot surgeons must thoroughly understand and assess the differences and relationships within the sole of the foot [9]. Symptomatic clawing of the fifth toe is a common presentation in clinical practice. Surgery is indicated when this condition does not respond to conservative treatment. However, if the tendon of an accessory muscle also inserts into the fifth distal phalanx, lengthening the FDL tendon may not result in satisfactory correction to clawing. In such cases, both tendons (FDL and accessory muscle tendon) must be lengthened to completely relax the clawed toe and allow definitive correction [10]. Holzmann et al., found an accessory muscle in the region and identified it as the flexor digitorum accessorius longus muscle [11]. Furthermore, Athavale et al., revealed that the medial head of the quadratus plantae muscle may possess distinct attachments [12]. Regarding the distinct attachments of the quadratus plantae muscle, Reeser et al., described that the variable insertion points might aggravate the symptoms of the tibial nerve lesions and the tarsal tunnel syndrome [13]. Recent studies emphasize that the accessory muscles may have close anatomical relations with the neurovascular bundles of the region, and this relationship may cause neuropathies and vascular insufficiencies due to entrapments or compressions of these bundles. For instance, the medial plantar nerve generally passes between the flexor hallucis and FDB, but rarely is observed to be coursing superficial to the FDB, provoking a nerve compression [14]. Hypertrophied abductor hallucis muscles may induce increased pressure on the medial plantar nerve, leading to pain and dysfunction [13]. Furthermore, variations and distinct insertions of the quadratus plantae may cause nerve entrapments and potentially contribute to tarsal tunnel syndrome [15].

#### Conclusion

The presence of accessory muscles and variations in the plantar region of the foot may have close anatomical relations with the neurovascular bundles. Such relations may cause neuropathies and vascular insufficiencies due to entrapments or compressions to the bundles. According to the results of the current study, the described accessory muscle may significantly contribute to the flexion of the toes and may alter the mechanics of walking. Furthermore, the variations of the accessory muscles should be taken into consideration in surgical interventions since, they may shape the course of the intervention. Finally, accessory muscles can be used as grafts for surgeries, such as the abductor hallucis muscle is frequently used in reconstructive surgeries.

#### Compliance with Ethical Standards

This research was conducted ethically in accordance with the principles of Helsinki World Medical Association Declaration.

**Conflict of interest statement:** The authors have no conflict of interest to declare.

**Funding sources:** This research did not receive any specific grant from funding agencies in the public, commercial, or notfor-profit sectors.

**Authors contributions:** The authors confirm contribution to the paper as follows: OK: Research idea, UV: Design of the study, EZ: Acquisition of data for the study, HE: Analysis of data for the study and drafting the manuscript, NY: Interpretation of data for the study, YA: Revising the manuscript critically for important intellectual content. All authors reviewed the results and approved the final version. OK: Final approval of the version to be published.

#### REFERENCES

- [1] Raviteja P, Chandrupatla M, Harshitha R, et al. Anatomical variation of quadratus plantae in relation with flexor digitorum brevis. *Anat Cell Biol* 2023;56:562-5. doi: 10.5115/ACB.23.102
- [2] Standring S, Gray H. *Gray's anatomy : the anatomical basis of clinical practice*. London: Churchill Livingstone/Elsevier, 2008.
- [3] Ger R. The clinical anatomy of the intrinsic muscles of the sole of the foot. *Am Surg* 1986;52:284-5.
- [4] Chandrupatla M, Kaliappan A, Subramanya H, Vishwajeet Lande V, Gupta N, Munda R. A rare variation of plantar interossei muscles of the foot – A case report. *Maedica* 2023;18:153-6. doi: 10.26574/maedica.2023.18.1.153
- [5] Motwani R, Garapati S. Unilateral extra muscle in the sole of the foot: A case report and its embryological review. *Indian J Anat* 2018;7:637-9. doi: 10.21088/ija.2320.0022.7618.11
- [6] Latey PJ, Burns J, Nightingale EJ, Clarke JL, Hiller CE. Reliability and correlates of cross-sectional area of abductor hallucis and the medial belly of the flexor hallucis brevis measured by ultrasound. *J Foot Ankle Res* 2018;11:28. doi: 10.1186/s13047.018.0259-0
- [7] Aland RC, Sharp AC. Anomalous plantar intrinsic foot muscle attaching to the medial longitudinal arch: possible mechanism for medial nerve entrapment: a case report. *J Med Case Rep* 2021;15:58. doi: 10.1186/s13256.021.02676-x
- [8] Detton AJ. *Grant's Dissector*. 17<sup>th</sup> edition. Lippincot Williams and Wilkins, A Wolters Kluwer Business, 2021.
- [9] Haratizadeh S, Seyyedini S, Nematollahi-Mahani SN. Anatomical variation of quadratus plantae in relation to flexor hallucis longus and flexor digitorum longus: a rare case. *Folia Morphologica (Poland)* 2023;82:412-5. doi: 10.5603/FM.a2022.0034
- [10] Stimec B V, Dash J, Assal M, et al. Additional muscular slip of the flexor digitorum longus muscle to the fifth toe. *Surg Radiol Anat* 2018;40:533-5. doi: 10.1007/s00276.018.1991-7

- [11] Holzmann M, Almodallal N, Rohlck K, et al. Identification of a flexor digitorum accessorius longus muscle with unique distal attachments. *The Foot* 2009;19:224-6. doi: 10.1016/j.foot.2009.03.002
- [12] Athavale SA, Geetha GN, Swathi. Morphology of flexor digitorum accessorius muscle. *Surg Radiol Anat* 2012;34:367-72. doi: 10.1007/s00276.011.0909-4
- [13] Reeser LA, Susman RL, Stern JT. Electromyographic studies of the human foot: experimental approaches to hominid evolution. *Foot Ankle* 1983;3:391-407. doi: 10.1177/107.110.078300300607
- [14] Stecco C, Corradin M, Macchi V, et al. Plantar fascia anatomy and its relationship with Achilles tendon and paratenon. *J Anat* 2013;223:665-76. doi: 10.1111/joa.12111
- [15] Öztürk B, Angın E, Güçhan Z, Yurt Y, Malkoç M. Assessment of the plantar pressure, muscle strength and balance in patients with type 2 diabetes mellitus in cyprus. *Open J Endocr Metab Dis* 2016;06:151-8. doi: 10.4236/ojemd.2016.65020