

# ÜST EKSTREMİTENİN PRİMER VENÖZ ANEVİRİZMASI

## Primary Venous Aneurysm Of Upper Extremity

Sedat Özcan<sup>1</sup>, Buğra Destan<sup>2</sup>

### ÖZET

Venöz sistemin tüm bölgeleri için venöz anevrizmalar nadir görülen malformasyonlardır. Genellikle, alt ekstremitelerde bulunurlar. Bu yazıda nadir görülen bir bazilik ven anevrizmasını sunmaktayız. Kardiyoloji kliniğimizde sol aksiyel fossa medial yüzünde hareketli kitlesi olan 21 yaşında bir erkek hasta değerlendirildi. Doppler ultrasonografi (USG) görüntülemesi aksilla yakınında bazilik venin anevrizmatik bir segmentini ortaya çıkardı. Genel anestezi altında lezyonun cerrahi eksizyonu gerçekleştirildi. Eksize edilen vasküler lezyonun bazilik vende primer anevrizmatik dilatasyon olduğu gösterildi. Venöz anevrizmalar nadir vasküler malformasyonlardır. Yüzeysel venöz anevrizmaların ayırıcı tanısının yapılması gerekir. Üst ekstremitede ise bu lezyonun nadiren gözlemlendiği bir bölgedir ve bu tip bir venöz bozukluk nadiren hayatı tehdit eder, ya da nadiren üst ekstremitede işlevsel sorunlara yol açar.

**Anahtar kelimeler:** Venöz Anevrizma, Üst Ekstremitede, Bazilik Ven

### ABSTRACT

Venous aneurysms are rare malformations in any region of the venous system. Usually it's found in lower extremity. In this report we present a basilic vein aneurysm which is a rare case of this kind. A 21-year-old man with a mobile mass in the medial aspect of the left axillary fossa is consulted in cardiology clinic. Doppler ultrasound imaging revealed an aneurysmatic segment of basilic vein near the axilla. Surgical excision was performed under general anaesthesia. Excised vascular lesion proved to be a primary aneurysmatic dilation of the basilic vein. Venous aneurysms are rare vascular malformations. Superficial venous aneurysms should always be considered in the differential diagnosis of a subcutaneous mass. Upper extremity is an unusual location of this lesion. Fortunately, this type of venous disease is rarely life threatening or cause functional problems to the upper limb of a patient.

**Key words:** Venous Aneurysm, Upper Extremity, Basilic Vein.

<sup>1</sup>Rize Eğitim Araştırma Hastanesi  
Kardiyo Vasküler Cerrahi Kliniği,  
RİZE

<sup>2</sup>Balıkesir Devlet Hastanesi  
Kardiyo Vasküler Cerrahi Kliniği,  
BALIKESİR

Sedat Özcan, Uzm. Dr.  
Buğra Destan, Uzm. Dr.

#### İletişim:

Uzm. Dr. Sedat Özcan  
Rize Eğitim Araştırma Hastanesi  
Kardiyo Vasküler Cerrahi Kliniği,  
Rize

Tel: (0354) 212 11 90/133

e-mail:  
sedatozcan@hotmail.com

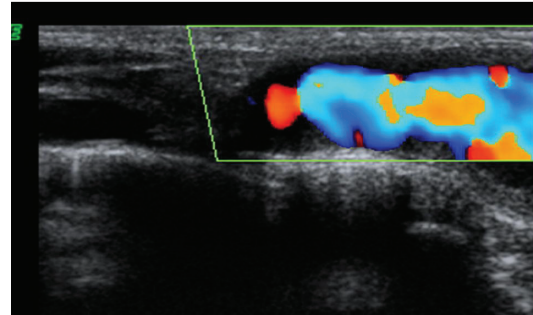
## INTRODUCTION

Venous aneurysms are regarded as rare malformations that may appear in any region of the venous system(1-6). Venous aneurysms are roughly classified as primary, congenital in origin or secondary to trauma (1-2). Connective tissue diseases or a local inflammation may also cause degenerative changes in the venous wall(2). A limited number of cases involving the upper extremity venous aneurysms have been published in the literature (3-21). We recently operated a male patient with a primary aneurysm of the basilic vein near the axillary fossa. This report contains description of the case and a review of the literature about venous aneurysms.

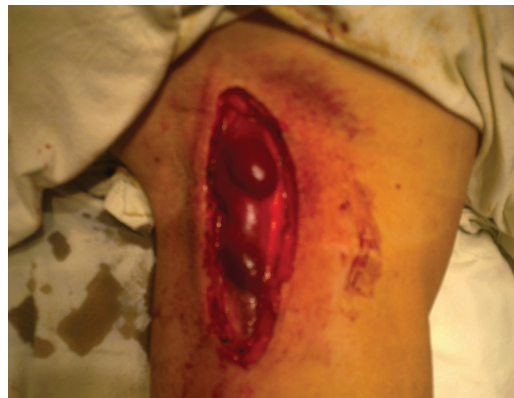## CASE PRESENTATION

A 21-year-old man presented to our cardiology outpatient clinic with a mobile mass in the medial aspect of the left axillary fossa. The mass had increased in size progressively in two years. It was a pulseless ,soft, subcutaneous mass that caused both a cosmetic concern and left arm pain. However, it resembled the appearance of a lipoma. There was no history of trauma in the left arm and axillary fossa. He had also no history of a systemic disease or a major operation. Doppler ultrasound imaging revealed an aneurysmatic segment of basilic vein near the axilla (Picture 1). Thus, he is consulted with cardiovascular surgery department for an elective surgical intervention. The excision of the mass was done under general anaesthesia. After a transverse incision of the skin and the subcutaneous tissues, a cystic venous lesion was revealed. The lesion was an aneurysmal dilatation of the basilic vein (Picture 2). The lesion was totally dissected from the surrounding tissues and excised (Picture 3). The distal venous stump was ligated and the basilic vein wall was sutured proximally with a fine prolene stitch. He was discharged on the second day after surgery. The excised mass was a distended vein measuring 7.2x2.8x1.8 cm, macroscopically. In the microscopic evaluation, the specimen was consistent with a primary aneurysm with irregular masses

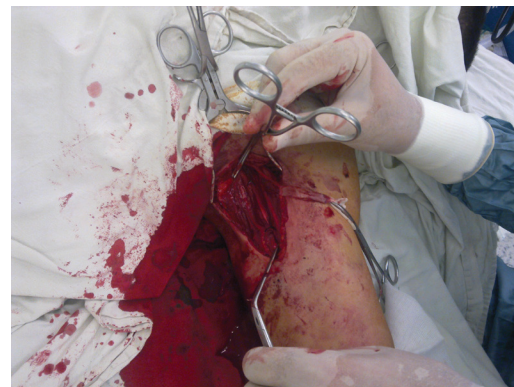of smooth muscle embedded in mature fibrous tissue.



Picture 1: Doppler US imaging of the lesion



Picture 2: Aneurysm of the basilic vein



Picture 3: After the excision of the aneurysmal segment

## DISCUSSION

Venous aneurysms are known as rare venous malformations that ensue equally between the sexes and are reported at any age and race. They may develop in all parts of the venous system. Lower extremities seem to be the most common location of vein aneurysms; there have been several reports, mainly of popliteal aneurysms (6).

On the other hand, only a few cases involving the upper extremity veins have been previously published (3-15). To the best of our knowledge, this is the 4th case of basilic vein aneurysms to be reported in the literature (16-18). This type of lesion is usually recognized either as a painful or painless subcutaneous mass if they are thrombosed. Our patient presented with a mobile, soft, subcutaneous mass that caused both cosmetic concern and a mild pain during the joint movement.

Serious complications have been rarely reported from upper extremity venous aneurysms even after thrombi formation(19). Surgical intervention is undertaken mainly for cosmetic reasons. However, they should also be operated if they cause pain or discomfort.

Exact causes of venous aneurysms remain unknown, although several theories have been proposed such as endophleboscrosis, inflammation and trauma. When trauma or concomitant arteriovenous fistulae are excluded, these aneurysms are considered primary and probably congenital. Histologically, these lesions include a flattened layer of endothelium and a significant decrease in the number and the size of muscle and elastic fibres (6). A fragmented internal elastic lamella and its replacement by fibrous connective tissue has been detected as well (1).

Venous aneurysms of upper extremity are mostly asymptomatic and should be considered in the differential diagnosis of subcutaneous masses of the axilla and upper extremities. Most venous aneurysms in the superficial venous system are palpable

and easily compressed. Color doppler ultrasonography and venography are useful imaging modalities to demonstrate the lesion, if an aneurysm is suspected. However, one should note that not all venous aneurysms have a benign behaviour. Abdominal and popliteal venous aneurysms have caused pulmonary embolisms and may require surgical management to prevent complications (4-5).

Venous aneurysms are rare vascular malformations. Their presentation and natural history depends on their location. Superficial venous aneurysms should always be considered in the differential diagnosis of a subcutaneous mass. Upper extremity is an unusual location of this lesion. Fortunately, this type of venous disease is rarely life threatening or cause functional problems.

## KAYNAKLAR

1. Zomboni P, Co u A, Arpanese L, Imoneni G, Massarelli G, Liboni A. The so-called primary venous aneurysms. *Phlebology* 1990; 5: 45-50.
2. Pearce WH, Winchester OJ, Yao T. Venous aneurysms. In: *Aneurysms. ew Findings and Treatments*, ed. by Yao J, Pearce WH. orwalk, CT: Appleton and Lange, 1994, pp 379-3.
3. Ritter H, Weber J, Loose DA. Venose aneurysaem. *VASA* 1993; 22: 105-12.
4. Calligaro KD, Ahmad • Dandora R, Dougherty MJ, Savarese RP, Doerr KJ, McAlfe S, DcLaurcnti DA. Venous aneurysm . *Smgery* 1995; II 7: 1-6.

5. Gillespie DL, Villavicencio JL, Gallagher , Chang A, Hamelink JK, Fiala LA, O'Oonell O, Jackson MR, Pikoulis E, Rich M. Presentation and management of venous aneurysms. *J Vase Surg* 1997; 26(5): 845-52.
6. Uernatsu M, Okada M. Primary venous aneurym m case reports. *Angiology* 1999; 50(3): 239-44
7. Buckberg GO, McReynolds DO. Venous aneurym m of upper extremity: a case report. *Am Surg* 1971; 37(2): 83-86.
8. Sarap MD, Wheeler WE. Venous an uryms. *J Vase Surg* 1988;8(2): 182-3.
9. Perler BA. Venous aneurysm. An unusual upper extremity mass. *Arch Surg* 1990; 125(1): 124.
10. Friedman SG, Kri hnasastry KV, Doscher W, Dcckolf L. Primary venous aneurym ms. *Surgery* 1990; 108(1): 92-5.
11. ishida K, Miyazawa Y, Matsumoto K, Okinaga K, Imamura T. Primary venous aneurym m of the forearm in a child. *Jpn J Surg* 1991; 21(2): 241-3.
12. Paes T, Andrews S, Wyatt A. HI" *J Sports Med* 1991; 25(3): 149-150.
13. Ekim H, Gelen T, Karpuzoglu G. Multiple aneurysms of the cephalic vein. *Angiology* 1995; 46(3): 265-7.
14. Morrison J, Rubin DA, Tomaino MM. Venous aneurysm of the distal forearm MR imaging findings. *AJR* 1996; 167(6): 15524.
15. Goto Y, Sakurada T, anjo H, Masuda H. Venous aneutylom of cephalic vein: a case report. *Surg Today* 199 ; 28(9): 964-6.
16. Keith D. Calligaro, MD, Syed Ahmad, MD, Rahul Dandora, Matthew J. Dougherty, MD, Ronald P. Savarese, MD, Kevin J. Doerr, Venous aneurysms: Surgical indications and review of the literature, *Surgery*, January 1995, 117-1.
17. Masahisa Uematsu, Masayoshi Okada, Multiple Venous Aneurysm of a Basilic Vein, *Annals of Vascular Surgery*, Volume 15, Issue 4, July 2001, Pages 485-487.
18. I.E. Katsoulis, S. Jader, H.A. Bradpiece, Primaty anemysm ofthe basilic vein, *Surg J R Coil Surg Edinb Irel.*, 1 October 2003, 299-301.
19. S.P. Joseph and J. Sathianathan, Thrombophlebitis of Aneurysmal Antecubital Vein causing Pulmonary Embolism: A Case Report, *EJVES Extra Vol* 13, March 2007.