

■ Original Article

Comparison of Elastane Fiber with Polypropylene and Polyglycaprone 25 used as Surgical Suture Material: an experimental preliminary study

Elastan Lif ile Polipropilen ve Poliglekapron 25'in Cerrahi Sütür Malzemesi Olarak Karşılaştırılması: Deneysel Ön Çalışma

Mehmet KABALCI^{1*}, Nesimi GUNAL², Yasemin DERE GUNAL³, Mahi BALCI⁴, Berkant OZPOLAT², Koray DURAL², Serap YORUBULUT⁵, Erdinc EROGLU⁶, Alptekin YASIM⁶

¹ Department of Cardiovascular Surgery, Medicine Faculty of Kirikkale University, Kirikkale, Turkey

² Department of Thoracic Surgery, Medicine Faculty of Kirikkale University, Kirikkale, Turkey

³ Department of Pediatric Surgery, Medicine Faculty of Kirikkale University, Kirikkale, Turkey

⁴ Department of Pathology, Medicine Faculty of Kirikkale University, Kirikkale, Turkey

⁵ Department of Statistics, Faculty of Science and Letters, Kirikkale University, Kirikkale, Turkey

⁶ Department of Cardiovascular Surgery, Medicine Faculty of Kahramanmaraş Sutcuimam University, Kahramanmaraş, Turkey

ABSTRACT

Aim: Elastane fiber is a synthetic monofilament polymer which is durable and highly flexible. In this preliminary study we compared Elastane fiber with polypropylene and polyglycaprone 25, surching the inflammatory reaction in the rat soft tissue, considering that it could be used for sternal closure because of its properties.

Material and Methods: Elastane fiber, polypropylene and polyglycaprone25 sutures were placed in 3 separate areas at 2 cm intervals in the subcutaneous tissue of each 8 male wistar albino rats without any incision, using the seldinger method. After two weeks, the rats were sacrificed and tissue specimens, including the suture fragments, were resected. Histopathological scoring in terms of inflammation, vascularization, fibrosis and histiocytic reaction were achieved semiquantitatively.

Results: There was no statistically significant difference between three suture materials in terms of inflammation ($p=0.513$), vascularization ($p=0.065$), fibrosis ($p=0.108$) and histiocytic reaction ($p=0.630$).

Conclusion: As a conclusion elastane fiber showed similar inflammatory changes with other suture materials in the rat soft tissue which is thought to be useful for sternal closure due to its high flexibilityand durability.

Keywords: Suture material, inflammation, polypropylene, animal experiment,

Corresponding Author*: Mehmet Kabalci, Department of Cardiovascular Surgery, Medicine Faculty of Kirikkale University, Kirikkale, Turkey
E-Mail: kabalci@hotmail.com

Received 15.02.2018 accepted 28.02.2012

Doi: 10.18663/tjcl.395200

ÖZ

Amaç: Elastan lif, dayanıklı ve esnek sentetik bir monofilament polimerdir. Bu ön çalışmada sternum kapatılması için uygun nitelikte olduğunu düşündüğümüz elastan lif ile polipropilen ve poliglekapron 25'i rat yumuşak dokusunda oluşturdukları inflamatuvar cevaplar açısından karşılaştırdık.

Gereç ve Yöntemler: Elastan lif, polipropilen ve poliglekapron 25 dikişler 8 adet erkek wistar albino ratın subkutan dokusuna 2 cm aralıklarla 3 ayrı alana herhangi bir kesi yapılmadan seldinger yöntemi ile yerleştirildi. İki hafta sonra ratlar sakrifiye edilerek sütür parçalarını içerecek şekilde doku örnekleri alındı. Enflamasyon, vaskülarizasyon, fibrozis ve histiyositik reaksiyon açısından yarı kantitatif histopatolojik skorlama yapıldı.

Bulgular: Her üç sütür materyali arasında inflamasyon ($p = 0.513$), vaskülarizasyon ($p = 0.065$), fibrozis ($p = 0.108$) ve histiyositik reaksiyon ($p = 0.630$) açısından istatistiksel olarak anlamlı fark yoktu.

Sonuç: Yüksek esneklik ve dayanıklılığından dolayı sternum kapatılması için faydalı olacağını düşündüğümüz elastan lif, rat yumuşak dokusunda diğer dikiş materyalleri ile benzer inflamatuvar değişiklikler gösterdi.

Anahtar Sözcükler: Sütür materyali, inflamasyon, polipropilen, deneysel hayvan çalışması,

Introduction

Median sternotomy is the most popular technique to reach the mediastinum [1]. Postoperative sternal dehiscence and associated mediastinitis are important sources of morbidity and can be seen in 0.5 to 5% of cases [2,3]. There is still a search for the ideal closure technique and suture material to overcome this problem [4-9]. Even if sutures provide sufficient stability, recurrent motion pressure such as lying on side or coughing, can damage the bone tissue or even break the steel wire [10].

We planned a study to investigate if sternum dehiscence could be prevented by using a flexible suture material. Lycra® was discovered many years ago and has not been included in almost any research in the last 40 years so we had to test tissue compatibility comparatively before testing the durability of the material.

Monofilament sutures are the most appropriate stitches for contaminated and traumatic injuries due to their resistance to infection, high elasticity, and low inflammatory reaction, slippery, easy to pass through the tissue [11].

Polypropylene suture is a synthetic, monofilament, highly slippery and non-absorbable suture causing minimal acute inflammation in the tissue. It is highly resistant to contamination and infection [12,13]. Polyglycaprone 25 suture is a similar butan absorbable surgical suture [12]. The lowest tissue reaction occurs with stainless steel sutures, followed by polypropylene, polyglactin 910 and polyglycaprone [11].

Lycra® is a synthetic, monofilament, highly slippery, non-absorbable elastane fiber which is commonly used today in textile industry. Owing its strong, durable and highly flexible structure, it was thought that it could be used in surgery as a suture and prosthetic material after the discovery in 1959. However, a suitable area of use was not found [14,15].

Based on our hypothesis that due to the elastic properties of Lycra® during sternal closure, the material may stretch when there is a sudden stress, so not only that the bone damage can be avoided but the suture breakage might be prevented as well. Hence this preliminary study was done to compare the material with the well-known polypropylene and polyglycaprone 25 and to determine the inflammatory tissue response before testing that Lycra® provided the desired strength and stability.

Material and Methods

This in vivo experimental study was approved by the Ethics Committee of the Local Animal Experiments of the University (15 / 57,2015) and carried out at the animal research laboratory (Kırıkkale University, Kırıkkale, Turkey) between 3 and 17 October 2015.

Lycra®(Lycra, Invista, Maydon, Ireland), was compared with sutures known to be histopathologically compatible with tissues: Polypropylene (Polypropylene tie, Temalar Ltd, Ankara, Turkey) and polyglycaprone 25 (Monocryl®, Ethicon, San Lorenzo, Puerto Rico) which are now routinely used as suture material in a variety of surgical procedures.

A polypropylene tie (Polypropylene tie, Temalar Ltd, Ankara, Turkey) which is also planned to be used for sternal closure was used instead of a polypropylene suture, so polypropylene suture was not preferred to evaluate more real reactions. The material used for sternal closure and also referred to as plastic tie in the literature is compared with Lycra® suture because it does not require a knot, it is locked onto itself and is more elastic than steel sutures [16]. The elastane fiber and polypropylene tie were sterilized with ethylene oxide.

To avoid contact with other suture materials that may occur during skin closure, it was preferred to place the material by seldinger method instead of cutting the abdominal region in the rats. In order to standardize the reactions, it was preferred to place every 3 materials in each rat.

Animal model

In this randomized, controlled, experimental study, healthy, 300-350g weight, adult (aged>5 months) male Wistar Albino eight rats were used. After the rats were transferred to the laboratory, they were kept for a week as an adaptation period before surgery. During the entire study, the animals were kept at the Animal Research Laboratory (Kırıkkale University, Kırıkkale, Turkey) under veterinary supervision.

Eight randomly selected Wistar Albino male rats were anesthetized with ketamine (50mg / kg) (ketalar, Pfizer, Turkey) /xylazine (10mg / kg) (rompun, Bayer, Germany) administered intramuscularly. The abdominal region of the rats was shaved and antiseptis was performed with povidone iodine (Batticon, Adeka, Istanbul, Turkey). All of the materials were placed by seldinger method to the abdominal region of rats, subcutaneously. Lycra®, polypropylene and polyglycaprone 25 fragments of 1 cm length and two cm spacing, were placed by seldinger method to the abdominal region of rats, subcutaneously (Figure 1).

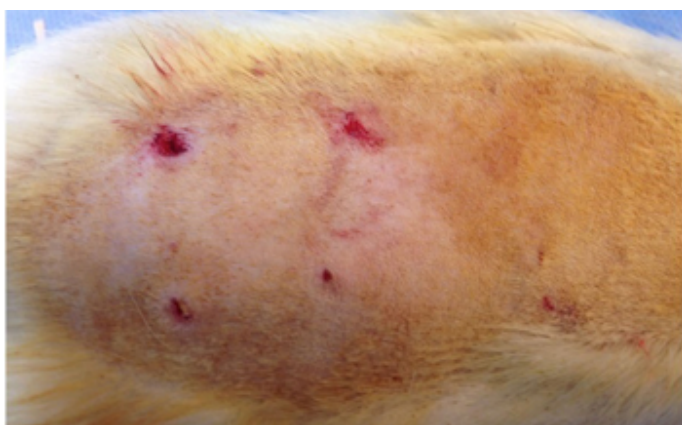

Figure 1. Suture pieces of 1 cm length, at intervals of 2 cm, placed on the anterior wall of the abdomen of the rat, subcutaneously.

The rats were followed for 2 weeks in at a room temperature of 25°C ± 1. 9°C and humidity of 52% ± 6%, and received a standard dietas well as water ad libitum during the follow up period. After sacrification full-thickness tissue samples containing each suture material were obtained (Figure 2).

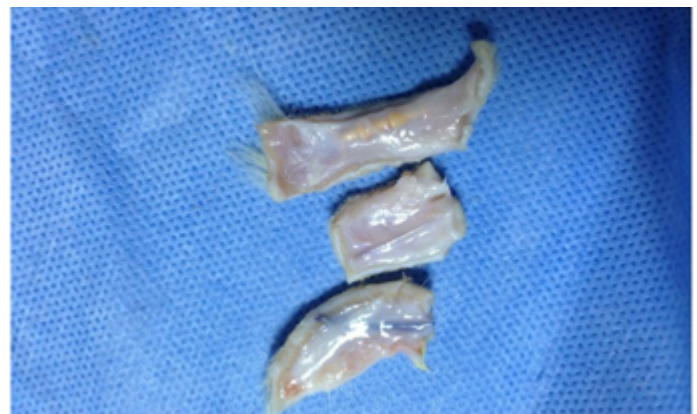

Figure 2. Three full-thickness tissue samples were obtained to contain each suture material separately

Histopatological Examination

Samples were examined by light microscope (Leica DMI 4000 B, Wetzlar, Germany) and classified semiquantitatively between grade 0 to grade 3 in terms of inflammation, vascularisation, fibrosis and histiocytic reactionas proposed by Hernandez- Richter et al. (Table 1)

Table 1. Evaluation of tissue repair response				
	0	1	2	3
Inflammatory	No	Edema	Intense polymorphonuclear leukocyte and cell infiltration	Intensive mixed inflammatory cell infiltration and tissue necrosis
Vascularisation	No	Mild vasodilatation	Severe congestion	Hemorrhage + neovascularization
Fibrosis	No	Few fibroblasts	Fibroblastic proliferation and increased collagen	Fibrosis, collagen bundles
Histiosis	No	Rare macrophage	High amounts of histiocytes, rare multinucleated giant cells	Granuloma formation

Statistical Analysis

The obtained data were analyzed by in SPSS (Version 20.0, IBM, New York, USA) programme.

The Kruskal-Wallis test was used for nonparametric double-over-group comparisons as the number of observations was not quantified (scale) whether the individual parameters of inflammatory, vascularisation, fibrosis and histiosis differed in the Lycra®, polypropylene and polyglycaprone25 groups. A p value less than 0.05 was considered statistically significant.

Results

No mortality and local effects such as anorexia, nausea, vomiting, diarrhea or behavioral disturbances were not observed in any group. Macroscopically none of the rats had an abscess or infection findings in the skin and subcutaneous tissue where the sutures were placed. There were no significant differences in the parameters of inflammation, vascularisation, fibrosis and histiocytic reaction examined in Lycra®, polypropylene and polyglycaprone25 materials ($p > 0,05$ for each parameter) (Table 2) (Figure 3-6).

Table 2. Evaluation of tissue repair response to suture materials

Number of rats and ratio within group	Inflammatory ($p=0.649$)	0	1	2	3	Total				
	Lycra	3	37.5%	5	62.5%	0	0.0%	0	0.0%	8
Polypropylene	2	25.0%	5	62.5%	1	12.5%	0	0.0%	8	100.0%
Polyglycaprone 25	2	25.0%	5	62.5%	1	12.5%	0	0.0%	8	100.0%

Number of rats and ratio within group	Vascularisation ($p=0.073$)	0	1	2	3	Total				
	Lycra	0	0.0%	3	37.5%	3	37.5%	2	25.0%	8
Polypropylene	0	0.0%	1	12.5%	6	75%	1	12.5%	8	100.0%
Polyglycaprone 25	0	0.0%	0	0.0%	3	37.5%	5	62.5%	8	100.0%

Number of rats and ratio within group	Fibrosis ($p=0.104$)	0	1	2	3	Total				
	Lycra	0	0.0%	2	25.0%	1	12.5%	5	62.5%	8
Polypropylene	0	0.0%	3	37.5%	5	62.5%	0	0.0%	8	100.0%
Polyglycaprone 25	0	0.0%	1	12.5%	4	50.0%	3	37.5%	8	100.0%

Number of rats and ratio within group	Histiosis ($p=0.562$)	0	1	2	3	Total				
	Lycra	1	12.5%	2	25.0%	4	50%	1	12.5%	8
Polypropylene	0	0.0%	2	25.0%	3	37.5%	3	37.5%	8	100.0%
Polyglycaprone 25	0	0.0%	3	37.5%	3	37.5%	2	25.0%	8	100.0%

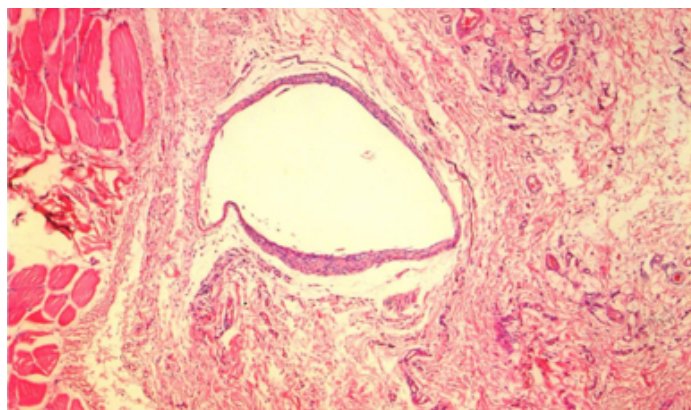


Figure 3. Cavitation induced by Lycra® and minimal fibroplasia and angiogenesis around it (Hemotoxylin Eosin x 40).

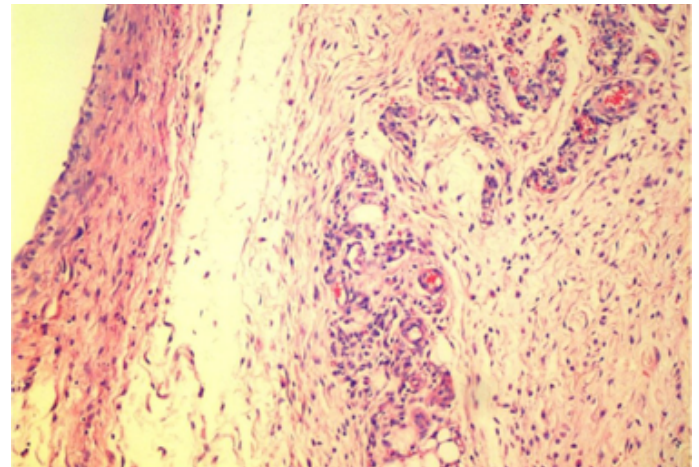


Figure 4. Moderate vascularization and fibroblastic response in cavity and surrounding tissue induced by Lycra® (Hemotoxylin Eosin x 40).

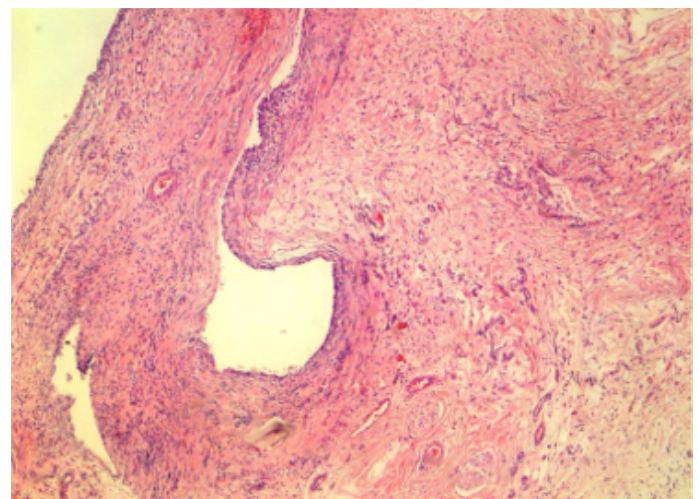


Figure 5. Moderate vascularization, fibroblastic and inflammatory response in cavity and surrounding tissue induced by polypropylene. (Hemotoxylin Eosin x 40).

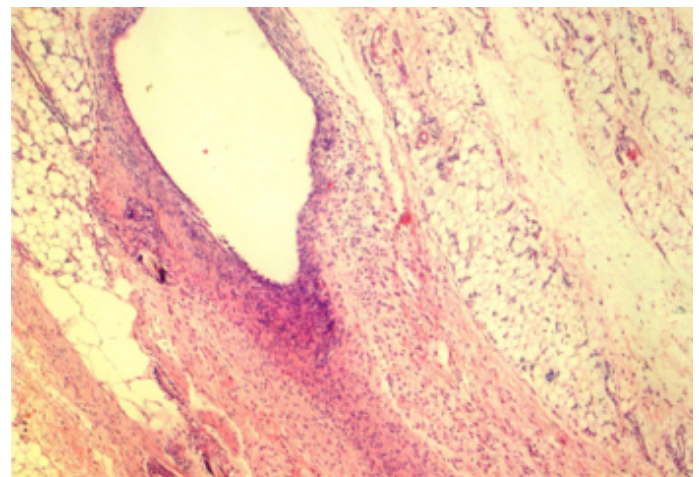


Figure 6. Moderate vascularization, fibroblastic and inflammatory response in cavity and surrounding tissue induced by Monocryl®. (Hemotoxylin Eosin x 40).



The result of "intensive mixed inflammatory cell infiltration and tissue necrosis", which is determined as the most severe inflammatory response level, was not observed in any suture material. Most number of rats at the "0" level, where no inflammatory response was detected, was in the Lycra® group. Inflammatory response was not significant among the groups ($p = 0.513$).

In the "Hemorrhage + Neovascularization" phase, which was the most inappropriate level for vascularization, Polyglecaprone 25 group had the worst results with 67.5% (5/8 rat). The difference was not significant ($p = 0.065$). In the response to fibrosis 67.5% (5 of 8) of the rats in the Lycra® group were at the "Fibrosis, collagen bundles" level, defined as the level in which the worst result was obtained, while none of the rats in the polypropylene group even reached this level. However, this difference was not significant in terms of fibrosis ($p = 0.108$). At the level where no changes were observed in terms of histiocytic reaction, only Lycra® group was present. There were three rats (37.5%) in the polypropylene group at the level of granuloma formation, the most undesirable level. The difference was not significant ($p = 0.630$).

Discussion

Various methods and materials have been investigated to prevent the sternal dehiscence after cardiac surgery and may cause severe mortality and morbidity [4-9]. Sutures are still the most appropriate and effective products used for apposition of tissues after a surgical incision is made. Synthetic or organic adhesives and cements mainly developed for dental and orthopedic applications have not been widely used in sternal closure [17]. The recommended method of use for cement and adhesives is an additional reinforcement to routine sternal closure with steel sutures [18]. Although today's technology has developed a wide variety of new alternative materials in the surgical field, new suture materials with flexibility as well as durability for certain specialized tissues and surgical techniques is not yet available.

Although the strength of the steel sutures used for the closure of the routine sternotomy in cardiothoracic surgery is sufficient, various uncontrolled movements of the patients, mainly coughing in the postoperative period, can cause both bone fractures and even suture breakage [10,19]. The search for new techniques and materials concerning the closure of sternum is still ongoing. [20]. The in vitro stability tests of the material we were working on were the subject of another study and positive results

were obtained. At this stage, the biocompatibility and tissue response of this material were examined.

For this purpose, we examined the tissue compatibility of Lycra® and found that the cellular changes caused by Lycra® were similar to polyglecaprone 25 and polypropylene.

Shirazi M. et al reported that more intense vascularization was observed with polyglecaprone 25 than other monofilament and absorbable polydioxanone, polyglactin acid, and polyglactin 910 sutures [21]. Polypropylene and polyglecaprone 25 sutures have been reported to cause low inflammation both in the literature and in our study [12]. The recovery phase in all tissues was consistent with histopathological findings between 1 and 2 weeks.

The major limitation of this study is polypropylene tie and Lycra® used in our work is not a medical product. It has been developed by chemists as a material with superior elastic properties than rubber and used extensively in the textile industry because it is highly elastic as well as oxidation and heat resistant, and does not easily lose this property [15]. However, it is thought that it can be used as a suture and prosthetic material due to these superior features and the possible effects of disinfection and sterilization processes have been studied for this purpose, but no suitable area were found for the medical field in the following years [14, 15].

Although in a few experimental studies where Lycra® was used as a suture material, superior features such as approximating the tissues without applying the tension, self-locking during the knotting and no tendency to open the first knot as opposed to other rigid sutures, were emphasized [14].

Studies have shown that multifilament sutures cause more inflammatory reactions than monofilament [22]. Yaltirik et al showed that polyglactin 910 (Vicryl, Ethicon, New Jersey, USA) was found as the least suture material causing tissue reaction [22]. Gartti-Jardim EC et al examined the effects of different polyglactin derivatives on healing process in rats' skin tissues, polyglecaprone 25 (Monocryl®) was found to have the best biological response [23]. In our study, the lowest inflammatory response was found in the "polyglecaprone 25" suture material, as noted in the literature.

In 1968, Wagner reported that Lycra® sutures were used on skin, intestines and liver, and almost no foreign body reaction was developed [14].

These limited studies of the medical use of Lycra® indicate

that further work is needed in this regard. We have planned in vitro and in vivo studies to test the endurance and prove that they can be used in practice, there is also a need for studies on the field of use.

Conclusion

Lycra® which is thought to be used as a suture material for sternal closure due to its flexible property, showed similar inflammatory changes with polypropylene and polyglycaprone 25 in the rat soft tissue.

Declaration of conflicting interests

The author(s) declared no potential conflicts of interest with respect to the research, authorship, and/or publication of this article.

References

1. Danter MR, Saari A, Gao, M, Cheung A, Lichtenstein SV, Abel JG. A New Device for Securing Sternal Wires After Median Sternotomy: Biomechanical Study and Retrospective Clinical Assessment. *Innovations (Phila)* 2018.
2. Schmid C, Akhter SA. Postoperative Sternal Complications. In *Cardiac Surgery* Springer, Berlin, Heidelberg 2017; 1129-35.
3. Schimmer C, Sommer SP, Bensch M, Bohrer T, Aleksic I, Leyh R. Sternal closure techniques and postoperative sternal wound complications in elderly patients. *Eur J Cardiothorac Surg* 2008; 34: 132-8.
4. Casha AR, Camilleri L, Manché A, Gauci M, Magri CJ, Agius A, Yang L. Effect of sternal wire twisting on sternotomy closure rigidity. *Indian J Thorac Cardiovasc Surg* 2018; 34: 25-30.
5. Abbas S, Gul S, Abbas A, Iqbal M, Khan T, Khan JS. Figure-of-8 sternal closure vs simple interrupted sternal closure in reducing sternal dehiscence in patients with coronary artery bypass grafting (CABG). *Pakistan Heart J* 2017; 50.
6. Park JS, Kuo JH, Young JN, Wong MS. Rigid sternal fixation versus modified wire technique for poststernotomy closures: a retrospective cost analysis. *Ann Plast Surg* 2017; 78: 537-42.
7. Motomatsu Y, Imasaka KI, Tayama E, Tomita Y. Midterm results of sternal band closure in open heart surgery and risk analysis of sternal band removal. *Artif Organs*. 2016; 40: 153-8.
8. Allen KB, Thourani VH, Naka Y, Grubb KJ, Grehan J, Patel N, Cohen DJ. Rigid Plate Fixation vs Wire Cerclage: Patient Reported and Economic Outcomes from a Randomized Trial. *Ann Thorac Surg* 2018.
9. Hashim S, Chin LY, Krishnasamy S, Sthaneswar P, Mokhtar RAR. Effect of sternal closure with biological bone adhesive on pain visual analogue score and serum cytokine. *J Cardiothor Surg*. 2015; 10: 32.
10. Wilson RM, Ghareeb PA, McClellan WT, Boustany AN. Biomechanical analysis of the FlatWire Figure 8 sternal fixation device. *Plast Surg*. 2014; 22: 188-90.
11. Celik F, Kaya MA. "Scientific criterias for surgical suture and needle selection" in Turkish. *Ulusal Cerr Derg*. 2006; 22: 153-57.
12. Dunn DL. *Wound closure manual*. Somerville, NJ: Ethicon inc. ; 2007; 97-102.
13. Birolini C, De Miranda JS, Utiyama EM, Rasslan S. A retrospective review and observations over a 16-year clinical experience on the surgical treatment of chronic mesh infection. What about replacing a synthetic mesh on the infected surgical field?. *Hernia* 2015; 19: 239-46.
14. Wagner M, Reul G, Teresi J, Kayser KL. Experimental observations on a new and inherently elastic material for sutures and vascular prostheses: Lycra. *Am J Surg* 1966; 111: 838-41.
15. Boretos JW, Pierce WS. Segmented polyurethane: A polyether polymer. An initial evaluation for biomedical applications. *J Biomed Mater Res* 1968; 2: 121-30.
16. Losanoff JE, Jones JW, Richman BW. Primary closure of median sternotomy: Techniques and principles. *Cardiovasc Surg* 2002; 10: 102-10.
17. Santos TdeS, Abuna RP, Almedia AL, Beloti MM, Rosa AL. Effect of collagen sponge and fibrin glue on bone repair. *J Appl Oral Sci* 2015; 23: 623-28.
18. Alhalawani AM, Towler MR. A review of sternal closure techniques. *J Biomater Appl* 2013; 28: 483-97.
19. Levin LS, Miller AS, Gajjar AH, Bremer KD, Spann J, Milano CA et al. An innovative approach for sternal closure. *Ann Thorac Surg* 2010; 89: 1995-99.
20. Orhan SN, Ozyazicioglu MH, Colak A. A biomechanical study of 4 different sternum closure techniques under different deformation modes. *Interact Cardiovasc Thorac Surg* 2017; 25: 750-756.
21. Shirazi M, Noorafshan A, Serhan A. Effects of different suture materials used for the repair of hypospadias: A stereological study in a rat model. *Urol Int* 2012; 89: 395-401.
22. Yaltirik M, Dedeoglu K, Bilgic B, Koray M, Ersev H, Issever H, et al. Comparison of four different suture materials in soft tissues of rats. *Oral Dis* 2003; 9: 284-86.
23. Carvalho AC, de Souza AP, de Souza CA, Pereira CC, Okamoto R, Magro FO. Comparative study of the healing process when using Vicryl®, Vicryl Rapid, Vicryl Plus®, and Monocryl® sutures in the rat dermal tissue. *Oral Maxillofac Surg* 2013; 17: 293-98.
24. Willsallen H, Heller J, Kark L, Hilbert BJ. In vitro mechanical testing of braided polyurethane elastic fiber and braided polyester for equine laryngoplasty. *Vet Surg* 2015; 44: 223-30.