



Identification Of *Acinetobacter Baumannii* As *Alcaligenes Faecalis* In A Case Of Posttraumatic Lower Extremity Osteomyelitis

Travma Sonrası Alt Ekstremitte Osteomiyeliti Olgusunda *Acinetobacter baumannii*'nin *Alcaligenes faecalis* Olarak Tanımlanması

Hakan Şenoğlu^{1*}, Barış Aladağ², Zeynep Nazlıkaya Erdem¹, Semra Kurutepe¹

¹ Department of Medical Microbiology, Manisa Celal Bayar University Faculty of Medicine, Manisa, Turkey.

² Department of Plastic Reconstructive and Aesthetic Surgery, Manisa Celal Bayar University Faculty of Medicine, Manisa, Turkey.

e-mail: hakansenoglu35@gmail.com, barisaladag25@gmail.com, zeynepnazlikaya1997@gmail.com,
semrakurutepe@yahoo.com
ORCID: 0000-0001-7429-9998
ORCID: 0009-0000-4297-2682
ORCID:0009-0009-1415-1903
ORCID:0000-0003-4031-8956

*Sorumlu Yazar / Corresponding Author: Hakan Şenoğlu

Gönderim Tarihi / Received:06.01.2025

Kabul Tarihi / Accepted: 20.02.2025

DOI: 10.34087/cbusbed.1614485.

Öz

Alcaligenes faecalis (*A. faecalis*), toprakta veya suda yaşayan gram negatif, çubuk şeklinde, oksidaz pozitif, katalaz pozitif, zorunlu aerob bir bakteridir. İnsanların bağırsak florasında ve nadir olarak hastane ortamlarında saptanmıştır. Genelde fırsatçı enfeksiyonlarla ilişkilidir. Giderek artan oranda antibiyotik direnci geliştirdiği görülmektedir. Bu çalışmanın amacı tanımlama yaparken dikkat edilmesi gereken yönleri, bu enfeksiyonun klinik ve mikrobiyolojik özelliklerini ön plana çıkarmaktır. Vakamız *A. baumannii*'nin tanımlanmasında mevcut VITEK 2 sisteminin sınırlılığını ortaya koymuştur. Yüksekten düşmeye bağlı kalkaneus fraktürü gelişen hastanın ameliyatı sonrası nadir görülen bir kronik osteomiyelit olgusunu sunuyoruz.

Anahtar kelimeler: *Alcaligenes*; Osteomiyelit; *Acinetobacter*; Kalkaneus; Tanımlama

Abstract

Alcaligenes faecalis (*A. faecalis*) is a gram-negative, rod-shaped, oxidase-positive, catalase-positive, obligate aerobic bacteria living in soil or water. It has been found in the intestinal flora of humans and rarely in hospital settings. It is usually associated with opportunistic infections. It seems to develop antibiotic resistance at an increasing rate. The aim of this study is to highlight the clinical and microbiologic features of this infection and the aspects that should be considered when identifying it. Our case demonstrated the limitations of the current VITEK 2 system in the identification of *A. baumannii*. We report a rare case of chronic osteomyelitis following surgery of a patient with calcaneal fracture due to a fall from a height.

Keywords: *Alcaligenes*; Osteomyelitis; *Acinetobacter*; Calcaneus; Identification

1. Introduction

Alcaligenes faecalis (*A. faecalis*) is a flagellated gram-negative bacillus belonging to the family Alcaligenaceae. It is a non-fermentative, aerobic, non-encapsulated, oxidase-positive bacterium and is named after its ability to produce alkaline reactions in certain media [1]. Nosocomial infections caused by *A. faecalis* are particularly common in immunocompromised patients and contamination by this pathogen occurs through hospital equipment, direct contact and fluids [2,3]. *A. faecalis*-associated infections such as endocarditis, meningitis, peritonitis, chronic otitis, abscess, pyelonephritis, sepsis, skin and soft tissue infections and endophthalmitis have rarely been detected in both hospital and community settings [1-3].

Acinetobacter baumannii (*A. baumannii*) is a common nosocomial pathogen causing healthcare-associated infections, including bloodstream infection, respiratory tract infection and meningitis. *A. baumannii* colonization is frequently seen in patients hospitalized in intensive care unit, surgical drainage or patients with indwelling urinary catheters [4].

In this case report, we aimed to give information about a case of chronic osteomyelitis thought to be due to *A. faecalis*, which was detected after hospitalization in a 55-year-old, immunocompetent, adult male patient who was admitted to Manisa Celal Bayar University Hafsa Sultan Hospital due to discharge and persistent foot pain.

2. CASE REPORT

In 2022, the fracture of the left calcaneus of a 55-year-old male patient, who suffered a fall from a height, was repaired with the plate-screw method by the orthopedic clinic. Approximately 3 months after the operation, the patient presented to Manisa Celal Bayar University Hafsa Sultan Hospital Plastic Reconstructive and Aesthetic Surgery Clinic with a tissue defect of approximately 4x4 cm in the posterior left heel with the plate and bone exposed (Figure 1).

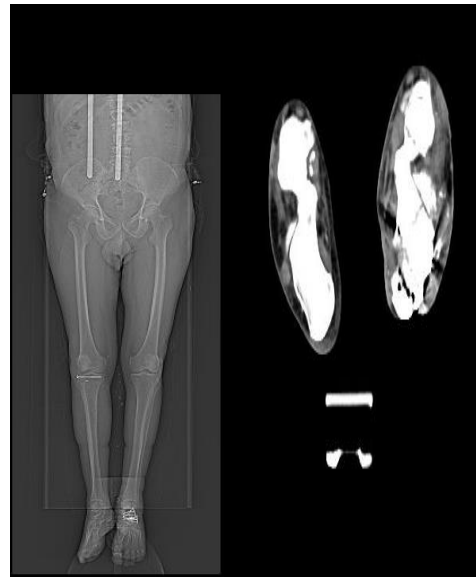


Figure 1. Lower extremity CT topogram (left) and lower extremity angio-CT (right) images of the patient taken in 2022

After the growth of *E. coli* in the wound culture material, the patient who had resistant *Acinetobacter baumannii* growth in the wound culture taken again was followed up as an outpatient for approximately 5 months with crystallized solution and appropriate antibiotic therapy followed by rifampin dressing. Then, he was admitted to the Plastic Reconstructive and Aesthetic Surgery Department and followed up with vacuum-assisted closure dressing until the day of surgery. The left foot MRI was evaluated as significant in terms of chronic osteomyelitis findings and the defect was repaired with a sural artery flap. In the postoperative examination, there was discharge from the wound site of the patient and resistant *Acinetobacter baumannii* growth continued. The existing wound lips were brought together and sutured with a second operation. In the following process, a wound culture sample was taken from the operation area and sent to Manisa Celal Bayar University Hafsa Sultan Hospital Medical Microbiology Laboratory. The wound sample of the patient was inoculated on 5% sheep blood agar (BD, USA) and EMB agar (BD, USA) media and incubated at 37°C for 18-20 hours. After incubation, opaque, non-hemolyzing, colorless and round shaped colonies were observed on blood agar; immobile, catalase positive, oxidase negative colonies forming transparent colonies were observed on EMB agar. Gram negative stained bacilli were identified as *Alcaligenes faecalis* in VITEK 2 Compact (BioMerieux, France) identification system using VITEK 2 GN ID (BioMerieux, France) card (Figure 2).

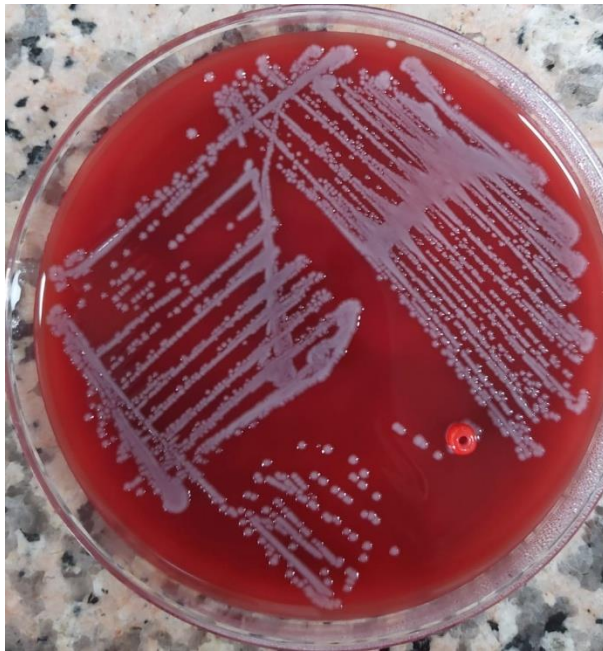

Figure 2. Opaque, non-hemolyzing, colorless and round shaped colonies were observed on blood agar.

A. faecalis is a rarely isolated pathogen in our hospital and is an oxidase positive bacterium. Due to the incompatibility of conventional methods, the strain was also identified by MALDI-TOF MS. All isolates were identified as *Acinetobacter baumannii* by MALDI-TOF MS and remarkably as *A. faecalis* by VITEK 2.

VITEK 2 AST (BioMerieux, France) card was used to determine the antibiotic susceptibility of the agent. The agent was highly susceptible to cefepime (16 µg/mL), trimethoprim sulfamethoxazole (≥ 320 µg/mL), ciprofloxacin (≥ 4 µg/mL), amikacin (≥ 64 µg/mL), meropenem (≥ 16 µg/mL), imipenem (≥ 16 µg/mL), piperacillin tazobactam (≥ 128 µg/mL) and aztreonam (≥ 64 µg/mL). Antibiotic susceptibilities of the causative agents were determined according to EUCAST standards [5].

Antimicrobial susceptibility test results were evaluated and meropenem and trimethoprim-sulfamethoxazole (TMP-SMX) treatment was started. The culture of the wound sample taken from the patient was evaluated with VITEK 2 and identified as *A. faecalis*. The patient was readmitted and antibiotic treatment with cefepime and vancomycin was started. The result of the wound culture obtained from the patient intraoperatively and then on the fourth postoperative day was identified as *A. faecalis*. In consultation with the Infectious Diseases unit, the patient was started on oral TMP-SMX and oral amoxicillin/clavulanic acid (Table 1). It should be noted that the isolated *A. faecalis* had only intermediate susceptibility to cefepime. With this antibiotic regimen, the patient showed clinical improvement and leukocytosis regressed and was discharged with appropriate follow-up recommendations. Approximately two weeks after discharge, the patient showed no signs of systemic infection at the office visit (Figure 3).

Table 1. Antibiogram Results of *A. faecalis* Isolated from Wound Culture*

Antimicrobial Agent	<i>Alcaligenes faecalis</i>
Piperacillin/Tazobactam	*R: ≥ 128
Sefepim	I: 16
Aztreonam	R: ≥ 64
Imipenem	R: ≥ 16
Meropenem	R: ≥ 16
Amikacin	R: ≥ 64
Ciprofloxacin	R: ≥ 4
Trimethoprim\Sulfamethaxazole	R: ≥ 320
Colistin	S= 0,19 (MIC \leq 2)
Tigecycline	MIC: 6

(*S: Susceptible, I: Highly susceptible, R: Resistant)

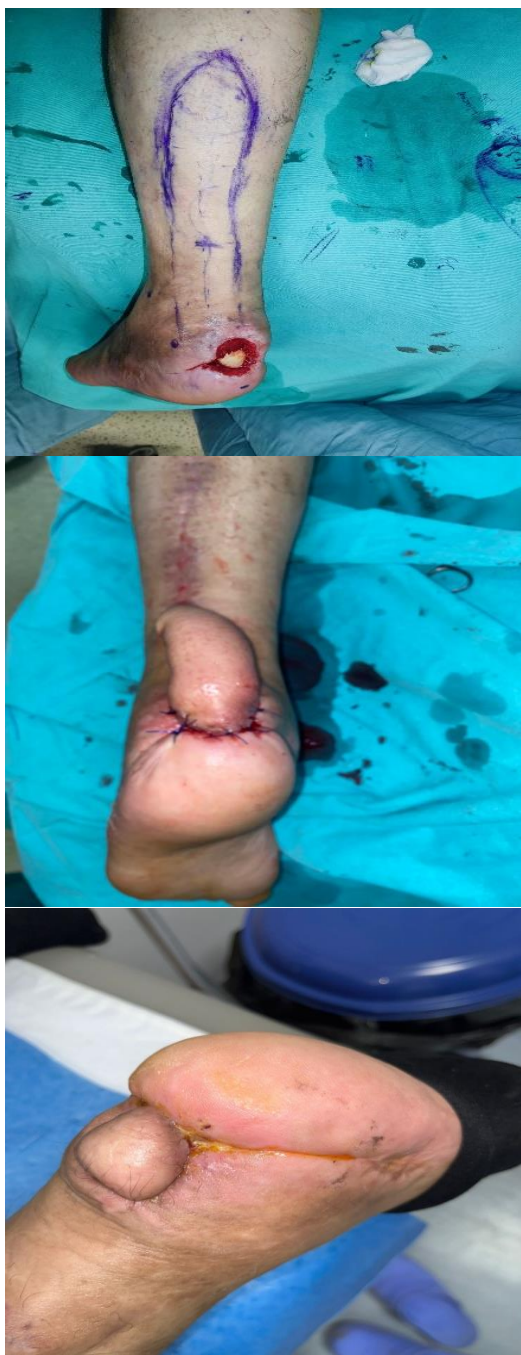

Figure 3. Preoperative (left), postoperative (middle) and control (right) view of the wound site on the heel of the left foot after surgery.

3. Discussion

Alcaligenes faecalis is an etiologic agent rarely described as the cause of systemic infection in adults. Cases of meningitis and pneumonia associated with *A. faecalis* infection have rarely been reported in the literature; however, cases in Turkey regarding the association of *A. faecalis* grown at the wound site with chronic osteomyelitis are rare [3]. Different cases of chronic osteomyelitis with antibiotic resistance beyond that typically reported for *A. faecalis* are presented. The current literature on *A. faecalis* emphasizes that antibiotic

resistance should be considered [6]. Our study is valuable in terms of optimal treatment of wound site infections, follow-up after trauma surgery and prevention of infection with antimicrobial drug treatment without the need for invasive interventions such as limb amputation. When planning antibiotic treatment for *A. faecalis*, treatment should be initiated immediately based on antimicrobial resistance report, microbiologic culture results and susceptibility data.

Kim et al. identified *A. faecalis* by VITEK 2 from clinical samples (two sputum and two urine) of four different patients reported. However, when confirmed by MALDI-TOF MS and 16S rRNA, they found that all isolates were *A. Baumannii* [7]. Hasan et al. described a rare case of bloodstream infection caused by *A. faecalis*, which was resistant to all drugs including polymyxins and tigecycline and was successfully treated with double dose tigecycline therapy [8]. Skin and soft tissue infections caused by *A. faecalis*, including infections associated with diabetic foot ulcers, have been described previously, and even the reported cases of *A. faecalis* osteomyelitis were patients who also had diabetic foot ulcers [1,9]. In our case, our patient did not have a diagnosis of diabetes mellitus.

In a study conducted on one hundred and eighty-eight patients, it was found that all *A. faecalis* isolates were susceptible to colistin, amikacin and all cephalosporins, 75% were susceptible to sulfamethoxazole/trimethoprim, 90% were susceptible to tobramycin, tazobactam/piperacillin and gentamicin. It was found that 82.6% of *A. faecalis* isolates were resistant to levofloxacin and all of them were resistant to ciprofloxacin [10]. Antibiogram tests of our case revealed that our patient was sensitive to colistin, moderately sensitive to cefepime, resistant to sulfamethoxazole/trimethoprim, tazobactam/piperacillin and ciprofloxacin.

Our case is one of the few cases in Turkey and in the world when universal data are analyzed. However, it should be taken into consideration that *A. faecalis* may be a contaminant in some cases, especially in those who recover despite the absence of active treatment. Accurate identification of this multidrug-resistant microorganism and reporting antimicrobial susceptibility results to clinicians is important to provide the most appropriate treatment to the patient. In line with all these results, quinolone group antibiotics and trimethoprim-sulfamethoxazole may be appropriate in the treatment of *A. faecalis*, but further studies are needed to determine the antibiotic susceptibility profile of the agent.

While there is a case in the literature in which *A. baumannii* was misidentified as *A. faecalis* in urine and sputum samples, our study is important as it is

the first case in which this error was detected in wound culture. In conclusion, the results obtained with automated identification systems, including VITEK 2, should be interpreted with caution and additional methods such as MALDI-TOF MS or 16S rRNA sequencing should be used to increase the reliability of the diagnosis. The widespread use of next-generation molecular sequencing methods that can detect subspecies, such as the rRNA sequencing method, may contribute to the accurate and rapid identification of bacteria in the clinical microbiology laboratories of hospitals and may provide a large qualified scientific field in the management of a large number of patients in the clinic.

4. Acknowledgments

We would like to thank Prof. Dr. Alper TÜNGER, Ege University, Department of Medical Microbiology, for his support during the confirmation phase with MALDI-TOF MS.

5. References

1. Tena D, Fernández C, et al. *Alcaligenes faecalis*: an unusual cause of skin and soft tissue infection. *Jpn J Infect Dis*, 2015, 68(2), 128–130.
2. Aisenberg G, Rolston KV, et al. Bacteremia caused by *Achromobacter* and *Alcaligenes* species in 46 patients with cancer (1989–2003). *Cancer*, 2004, 101(9), 2134–2140.
3. Kavuncuoglu F, Unal A, et al. First reported case of *Alcaligenes faecalis* peritonitis. *Perit Dial Int*, 2010, 30(1), 118–119.
4. Sundar S, Rani TKP, Vijayalakshmi B, et al. Isolation and 16S rRNA sequencing of clinical isolates of *Acinetobacter baumannii*. *Int J Curr Microbiol App Sci*, 2014, 3, 855–8.
5. European Committee on Antimicrobial Susceptibility Testing (EUCAST). Clinical Breakpoint Tables for Interpretation of MICs and Zone Diameters Version 13.0. https://www.eucast.org/fileadmin/src/media/PDFs/EUCAST_files/Breakpoint_tables/v_13.0/Breakpoint_Tables.pdf (accessed 19.06.2024).
6. Avcu G, Erci EA, et al. A Very Rare Pathogen of Osteomyelitis: *Alcaligenes faecalis*. *The Pediatric Infectious Disease Journal*, 2023, 42(9), 362–363.
7. Kim S, Kim MH, et al. Misidentification of *Acinetobacter baumannii* as *Alcaligenes faecalis* by VITEK 2 System; Case Report. *Laboratory Medicine*, 2018, Volume 49, Issue 1, 14–17.
8. Hasan MJ, Nizhu LN, et al. Bloodstream infection with pandrug-resistant *Alcaligenes faecalis* treated with double-dose of tigecycline. *IDCases*. 2019, 18, e00600.
9. Huang C. Diabetic foot ulcer with *Alcaligenes faecalis* infection. *Dubai Diabetes and Endocrinology Journal*, 2020, 26, 128–133.
10. Filipe M, Reimer A, et al. Fluoroquinolone-resistant *Alcaligenes faecalis* related to chronic suppurative otitis media, Angola. *Emerg Infect Dis*, 2017, 23, 1740–1742.

<http://edergi.cbu.edu.tr/ojs/index.php/cbusbed> isimli yazarın CBU-SBED başlıklı eseri bu Creative Commons Atıf-Gayriticari 4.0 Uluslararası Lisansı ile lisanslanmıştır.

