

Journal of Surgery and Medicine

e-ISSN: 2602-2079

Recurrent unilateral gonadoblastoma: A rare histopathological presentation

Tekrarlayan unilateral gonadoblastom: Nadir bir histopatolojik sunum

Sadaf Haiyat ¹, Kafil Akhtar ¹, Durre Aden ¹, Mohammed Naim ¹

¹ Department of Pathology, Jawaharlal Nehru Medical College, Aligarh Muslim University, Aligarh, India

Abstract

Gonadoblastoma is a rare benign tumor that has the potential for malignant transformation and affects patients with disorders of sexual development. The exact prevalence of gonadoblastoma is not known. The association of gonadoblastomas with dysgerminoma is seen in 50-60% of cases and with other malignant germ cell tumours like yolk sac tumour, embryonal carcinoma and choriocarcinoma in 10% of cases. We herewith report a rare case of recurrent unilateral gonadoblastoma in a 10 year old Indian male who presented with abnormal passage of urine since birth. Physical examination showed a phenotypic male with undescended right testis and ambiguous external genitalia. Computed tomography scan reported mixed density solid cystic mass in pelvis with peripherally enhancing solid component and a few punctuate foci of calcification. Histo-pathological examination showed a heterogeneous tumor comprising of malignant seminomatous, sertoli and leydig cell tumor along with yolk cell tumor component. Serum alpha fetoprotein was raised to 1210 ng/ml.

Keywords: Gonadoblastoma, Seminoma, Yolk sac tumor, Ambiguous genitalia

Öz

Gonadoblastom, malign transformasyon potansiyeli olan ve cinsel gelişim bozukluğu olan hastaları etkileyen nadir bir benign tümördür. Gonadoblastomun kesin prevalansı bilinmemektedir. Gonadoblastomaların dysgerminoma ile ilişkisi olguların %50-60'ında ve vakaların %10'unda yolk kesesi tümörü, embriyonal karsinom ve koriokarsinom gibi diğer malign germ hücreli tümörlerde görülür. Bu yazıda, doğumdan beri idrarın anormal geçişi ile başvuran 10 yaşındaki bir Hintli erkeğin nadir bir tekrarlayan tek taraflı gonadoblastoma vakasını sunduk. Fizik muayenede inmemiş sağ testis ve belirsiz dış genital bölgede fenotipik bir erkek vardı. Bilgisayarlı tomografi taraması, pelviste periferik olarak gelişen katı bileşen ve birkaç noktalama kalsifikasyon odakları ile karışık yoğunluktaki katı kistik kitleyi bildirdi. Histo-patolojik inceleme, yumurta hücresi tümör bileşeniyle birlikte malign seminomatöz, sertoli ve leydig hücresi tümörünü içeren heterojen bir tümör gösterdi. Serum alfa fetoprotein 1210 ng/ml düzeyine çıktı.

Anahtar kelimeler: Gonadoblastoma, Seminom, Yolk sak tümörü, Belirsiz genitaliya

Introduction

Gonadoblastoma is a rare neoplasm, first described by Scully in 1953, comprising of mixed germ-cell and sex-cord derivatives usually occurring in dysgenetic gonads [1,2]. About 80% of the gonadoblastoma cases are phenotypically females while 20% are males [1,3]. Highest incidence of gonadoblastoma is observed in the second decade followed by third and first decades of life respectively [3]. Patients of gonadoblastoma usually present with primary amenorrhoea, virilization and abnormal genitalia [2,3].

About 50% of the cases of gonadoblastoma are found to be associated with dysgerminoma and about 10% cases of gonadoblastoma present with other malignant germ-cell tumours like teratoma, embryonal carcinoma and choriocarcinoma [3,4]. Only 2 cases of gonadoblastoma have been reported in normal male patients with scrotal testicles [5]. Gonadoblastoma coexistent with yolk sac tumour has been reported in a patient having female phenotype [6]. Esin S et al., have reported only 7 cases of gonadoblastoma in women with normal karyotype in 17 years of their study, with youngest being 10 years and the oldest 27 years [6]. Gorosito et al have also reported gonadoblastomas in pregnant women [3].

Corresponding author / Sorumlu yazar:
Kafil Akhtar

Address / Adres: Department of Pathology,
Jawaharlal Nehru Medical College, Aligarh
Muslim University, Aligarh (U.P), India
e-Mail: drkafilakhtar@gmail.com

Informed Consent: The author stated that the written consent was obtained from the parent of the patient presented in the study.

Hasta Onamı: Yazar çalışmada sunulan hastanın ebeveyninden yazılı onam alındığını ifade etmiştir.

Conflict of Interest: No conflict of interest was declared by the authors.

Çıkar Çatışması: Yazarlar çıkar çatışması bildirmemişlerdir.

Financial Disclosure: The authors declared that this study has received no financial support.

Finansal Destek: Yazarlar bu çalışma için finansal destek almadıklarını beyan etmişlerdir.

Received / Geliş tarihi: 17.03.2018

Accepted / Kabul tarihi: 23.03.2018

Published / Yayın tarihi: 23.03.2018

Copyright © 2018 The Author(s)

Published by JOSAM

This is an open access article distributed under the terms of the Creative Commons Attribution-NonCommercial-NoDerivatives License 4.0 (CC BY-NC-ND 4.0) where it is permissible to download, share, remix, transform, and buildup the work provided it is properly cited. The work cannot be used commercially without permission from the journal.



Disorders of sex development occur with an estimated incidence of 1:5000 [1]. Here, we report a rare case of recurrent unilateral gonadoblastoma with yolk sac tumor in a male phenotype child with ambiguous intra-pelvic genitalia.

Case presentation

A 10 year old Indian child with ambiguous external genitalia, reported to the Paediatric Surgery Outpatients Department in September 2014, with complaints of abnormal passage of urine since birth. On examination patient had ambiguous external genitalia with rudimentary phallus and normal appearing left testis. Right testis was not palpable in the scrotum. Face, breast, abdomen and gluteal region had normal male appearance. Per abdominal examination revealed a firm mass of about 5 x 4 x 4 cm in the right iliac fosse. Ultrasound examination showed a heterogeneous mass with cystic and focal calcified areas located between the urinary bladder and upper sacrum. CT scan reported mixed density solid cystic mass in pelvis with peripherally enhancing solid component and a few punctuate foci of calcification (Figure 1). The right ureter was dilated and tortuous with ectopic insertion below the neck of urinary bladder possibly in the prostate. Serum LDH was raised (575U/L), with a gross elevation of beta hCG and testosterone levels. Serum alpha-feto protein was also high (1210 ng/ml). Y chromosome was detected on karyotyping. The tumour was excised and submitted for histo-pathological diagnosis.

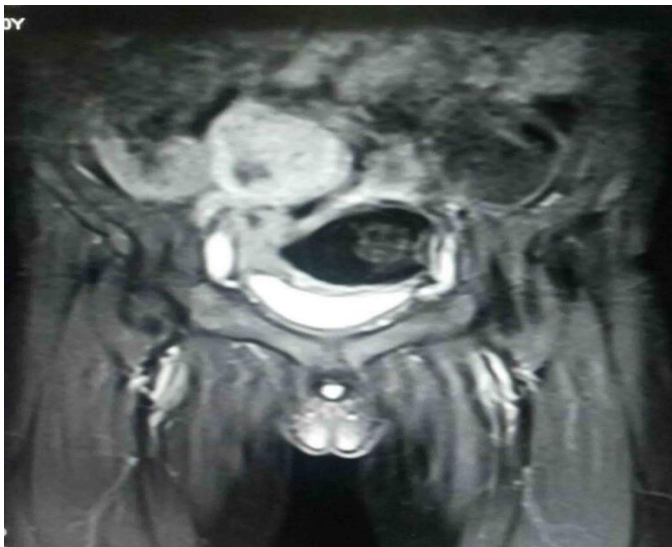

Figure 1: Computed tomography scan reported mixed density solid cystic mass in pelvis with peripherally enhancing solid component and a few punctuate foci of calcification.

On gross examination, tumour had an irregular surface measuring 12 x 9.5 x 8 cm. The cut surface was fleshy grey white with necrotic areas and foci of haemorrhage. Haematoxylin and Eosin (H&E) stained paraffin sections showed tubular seminiferous structures with proliferation of the germinal cells and small cells with round to oval nuclei and inconspicuous cytoplasm resembling immature sertoli cells (Figures 2 & 3). Summation of the above histopathological findings suggested a final diagnosis of gonadoblastoma. The differential diagnosis considered were germ cell tumors like dysgerminoma, teratomas, embryonal carcinoma, yolk sac tumor and choriocarcinoma. Patient's recovery after surgery was uneventful without any complaints in follow up period after 6 months. The level of

alpha-fetoprotein analysis done after 1 month of surgery was 13ng/ml.

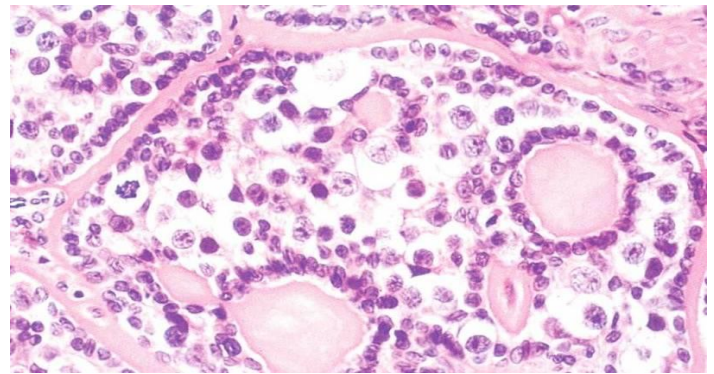


Figure 2: Microphotograph showing blastogenic tissue poorly differentiating into large polygonal germ cells and elongated sex-cord elements. Haematoxylin and Eosin x 40X

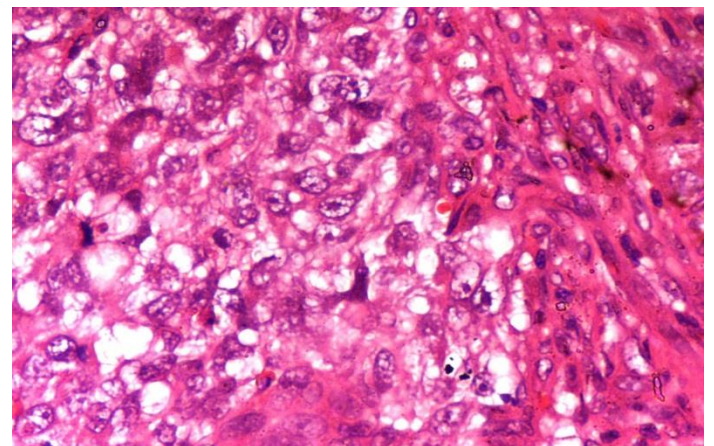


Figure 3: Section showing differentiation of tumor cells into sex-cord and germinal tubular elements. Haematoxylin and Eosin x 40X

Subsequently in January 2015, the patient presented with complaints of discomfort in the abdomen. On per-abdomen examination, a firm non-tender mass of about 4 cm size was palpable in the right lower abdomen. Contrast enhanced MRI showed altered signal intensity mass of about 3.5x3.8x3.8cm in the pelvis in front of S1 to L5 vertebra with intense heterogeneous post contrast enhancement and few centrally placed areas of necrosis (Figure 4). Fine needle aspiration cytology smears showed large tumour cells exhibiting nuclear pleomorphism, hyperchromasia, increased nuclear-cytoplasmic ratio with prominent nucleoli and numerous mitotic figures consistent with gonado-blast cells.

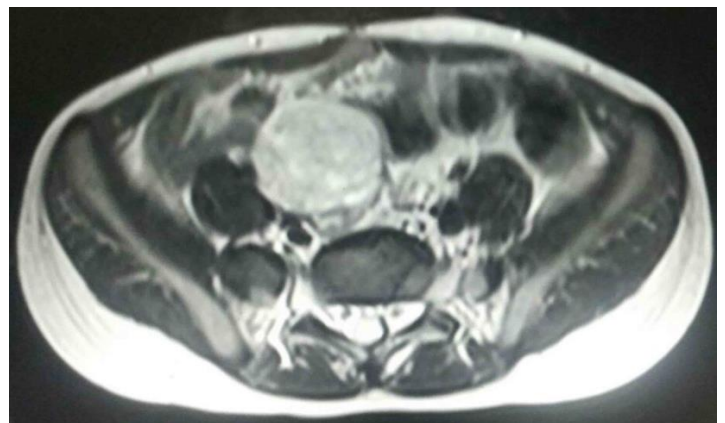

Figure 4: Contrast enhanced MRI showed altered signal intensity mass of about 3.5x3.8x3.8cm in the pelvis in front of S1 to L5 vertebra with intense heterogeneous post contrast enhancement and few centrally placed areas of necrosis.

The mass was excised and submitted for histopathological diagnosis. Macroscopically tumor was 4.5 x 3.5 x 1.5 cm in size with grey white cut surface, with focal areas of hemorrhage and necrosis. H&E stained sections showed seminiferous tubules filled with proliferating large seminoblastic germ cells and proliferating Sertoli and Leydig cells. In some areas Schiller-dual bodies lined by large gynandro-blastic cells were seen with hyaline globules (Figure 5). The germ cells were positive for OCT3/4 (Figure 6). Serum alpha-fetoprotein level was estimated to be 225ng/ml. Our patient was administered six cycles of combination chemotherapy of bleomycin (15 units), etoposide (100µg/m²) and cisplatin (33µg/m²) and is fine after 6 months of follow up period.

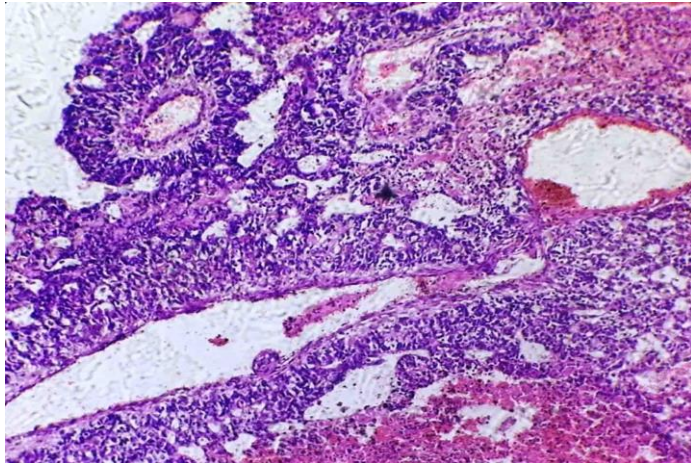


Figure 5: Section from the tumor area shows seminiferous tubules filled with proliferating large seminoblastic germ cells and proliferating Sertoli and Leydig cells with a foci of Schiller-dual body lined by large gynandro-blastic tumor cells. Haematoxylin and Eosin x 40X

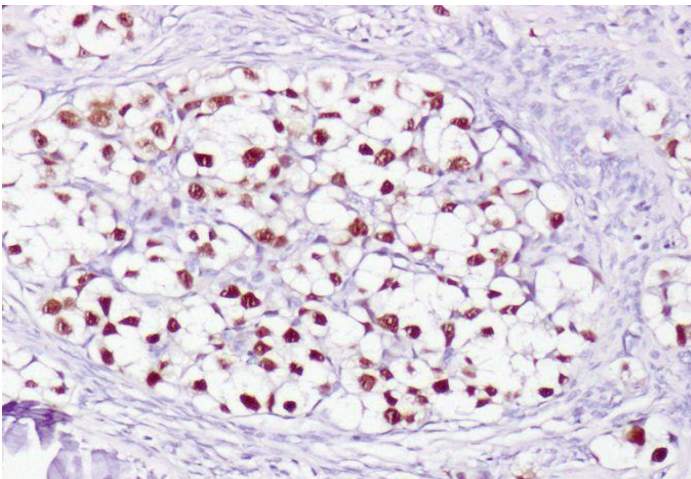


Figure 6: Microphotograph shows positivity for OCT 3/4 in the germ cells. Immunostain OCT 3/4 x 40X

Discussion

Gonadoblastoma is a rare neoplasm of mixed origin from the sex cord and germ cells reported in the earlier literature from sites of dysgenetic streak ovaries or abdominal testes [4]. They are found in 25%-30% cases of XY gonadal dysgenesis and in 15%-20% cases of 45X/46XY anomaly [1,3]. A very small number of gonadoblastomas develop in 46XX females with no evidence of Y chromosome [4]. Majority (60%) of the phenotypically female patients are virilised and the rest 40% appear exhibits poor genital development [7]. The patient in the present case had one descended testis and male phenotype suggestive of XY genotype, although further genetic testing in

the form of chromosomal analysis including karyotype and array CGH is warranted. Radiological examination showed tumour in front of the sacrum along the path of descending gonad. Histopathological examination showed a heterogeneous tumour comprising of malignant seminomatous and sertoli and leydig cell tumour along with yolk cell tumour component. Serum alpha fetoprotein was raised to 1210 ng/ml, diagnostic of yolk sac tumour. The findings of heterogeneous malignant hybrid androgynandro-blastic tumour were found to be consistent with gonadoblastoma. Gonadoblastoma with male seminomatous and gynecomatous yolk sac tumour has not been reported in earlier literatures.

About 50% of the cases of gonadoblastoma reported in the earlier literatures presented with dysgerminoma tumor component [3,5]. The incidence of yolk sac elements with gonadoblastoma is found to be 10% of all the cases of malignant germ cell tumours associated with gonadoblastoma [5]. Gelincik et al [7] described one case of bilateral gonadoblastoma coexistent with dysgerminoma on one side and dysgerminoma and yolk sac tumour on the other side in a 10 year old girl with 46XX karyotype. Only a single report has been found of gonadoblastoma with seminomatous tumour component in a male genotype child with ambiguous genitalia [8]. Sertoli cell tumour proliferation with gonadoblastoma has been reported in a 19 year old phenotypic female with gonadal dysgenesis [9].

The phenotype of the gonad in which the gonadoblastoma originated is usually indetermined due to presence of other germ cell tumor components, most likely a dysgerminoma [10]. Robert Scully [1] described 2 cases of gonadoblastoma located at the site where ovaries are normally situated, but normal ovarian tissue was not detected and the exact phenotype of the gonads in which the tumors originated could not be ascertained. The tumor was termed gonadoblastoma because it developed at ovarian site apparently recapitulating development of gonads in the individuals having abnormal development of the genitalia [1,7]. In another case a gonadoblastoma presented at left inguinal region suggestive of testicular phenotype, and with seminomatous component in a 43 year old patient with other genitalia appearing phenotypically female [9]. Our case had one descended scrotal testis and presented with unilateral gonadoblastoma with both the male germ-cell seminomatous and female yolk sac tumor components at a site common for un-descended testis and ovary. These findings suggested that an un-descended gonad may present ambiguous hermaphrodite or bisexual pheno-type giving rise to gonadoblastoma with both the male and female germ cell components together. These findings have not been reported in the earlier literatures till date.

Germ cell tumors frequently produce serum markers such as hCG, LDH and AFP. Elevated serum hCG levels are present in 3% of dysgerminomas [10]. The peptide hormones inhibin and Antimullerian Hormone (AMH) both produced by the granulosa cells are potential candidates for diagnosis and follow up of granulosa cell tumors [11]. A highly informative marker for the presence of gonadoblastoma and their invasive counterparts (dysgerminoma and seminoma as well as embryonal carcinoma) is the transcription factor OCT3/4, also known as POU5F1 [12,13].

Patients with a pure gonadoblastoma without other germ cell components are known to have an excellent prognosis provided both side gonads were excised [14,15]. The prognosis of patients of gonadoblastoma associated with dysgerminoma is also good. Presence of other germ cell tumors like yolk sac tumor makes the prognosis unfavourable and chemotherapy may be needed after surgery [13,14]. For the patients having dysgenetic gonads, bilateral oophorectomy and hysterectomy was recommended as treatment of choice. In the case of a 46 XX karyotype, the necessity of bilateral gonadectomy is less clear and rareness of the situation makes it difficult to decide the appropriate treatment [14]. Chromosomal analysis is useful to diagnose androgen insensitivity/male pseudohermaphroditism (46,XY) and Turner syndrome (45,XO) [14,15]. In the present case, the recurrent tumor after 6 months was apparently more aggressive cyto-morphologically and was given adjuvant chemotherapy. Our patient had an uneventful recovery and is without any remarkable complaints after 6 months of follow up.

This rare case of gonadoblastoma in a phenotypically male child with abnormal gonads should prompt us to perform a genitourinary exam to assess for phallic size, hypospadias, presence of palpable gonads either in the scrotal fold or inguinal region and for other dysmorphic features/malformations that may indicate an underlying syndrome. Basal hormone and tumor marker levels with imaging like pelvic ultrasound or MRI to look for internal genital anatomy and gonad position should be employed and gonadal biopsy performed with chromosomal analysis and FISH, if possible.

Acknowledgements

The technicians of Histopathology Lab.

References

1. Scully RE. Gonadoblastoma. A review of 74 cases. *Cancer*. 1970; 25:1340-56.
2. Scully R, Young R, Clement R Tumors of the ovary, mal-developed gonads, fallopian tube, and broad ligament. *Atlas of tumour pathology, Armed Forces Institute of Pathology, Washington, DC, 2010; Vol 4, Fascicle. 23:287-99.*
3. Gorosito M, Pancera B, Sarancone S, Nocito AL. Gonadoblastoma: an unusual ovarian tumour. *Ann Diagn Pathol*. 2010; 14(4):247-50.
4. Talerman A. Germ cell tumours of the ovary. In: Kurman RJ, editors. *Blaustein's Pathology of the female genital tract. 7 th ed. New York, Springer-Verlag; 2010:967-1033.*
5. Bonnie MCrosby, Roshanak M, Jennifer ED, Laurence BM, V RS, Elise GA, et al. State of the art review in gonadal dysgenesis: challenges in diagnosis and management. *Int J Pediatr Endocrinol*. 2014;20(14):4-14.
6. Esin S, Baser E, Kucukozkan T, Magden HA. Ovarian gonadoblastoma with dysgerminoma in a 15-year old girl with 46, XX karyotype: case report and review of the literature. *Arch Gynecol Obstet*. 2012;285:447-51.
7. Gelincik I, Ozen S, Bayram I. Left ovarian gonadoblastoma with yolk sac tumour in a young woman. *Ind J Pathol Microbiol*. 2010;53:345-46.
8. Hughes IA, Houk C, Ahmed SF, Lee PA, Group LC. Consensus statement on management of intersex disorders. *Arch Dis Child*. 2011;91:554-63.
9. Hersmus R, Vander ZYG, Stoop H, Bernard P, Sreenivasan R, Wolter OJ, et al. A 46,XY Female DSD Patient with Bilateral Gonadoblastoma, a Novel SRY Missense Mutation Combined with a WT1 KTS Splice-Site Mutation. *PLoS ONE*. 2012;7(7):40-8.
10. Deepa VK, Kishan P, Aparna R, Rohan GK, Sara C, Harish S, et al. Gonadoblastoma with Dysgerminoma in a Young Girl with 46, XX Karyotype: A Case Report. *Journal of Clinical and Diagnostic Research*. 2013;7(9):2021-2.
11. Geerts I, Vergote I, Neven P, Billen J. The role of inhibins B and antimullerian hormone for diagnosis and follow-up of granulosa cell tumours. *Int J Gynecol Cancer*. 2012;19(5):847-55.
12. Barros BA, Moraes SG, Coeli FB, Assumpção JG, De Mello MP, Maciel-Guerra AT, et al. OCT4 immunohistochemistry may be necessary to identify the real risk of gonadal tumors in patients with Turner syndrome and Y chromosome sequences. *Hum Reprod*. 2011;26:3450-5.
13. Looijenga LH, Stoop H, de Leeuw HP, de Gouveia Brazao CA, Gillis AJ. POU5F1 (OCT3/4) identifies cells with pluripotent potential in human germ cell tumors. *Cancer Res*. 2013;63:2244-50.
14. Knauer-Fischer S, Besikoglu B, Inta I, Kneppo C, Vogt PH, Bet-tendorf M. Analyses of gonadoblastoma Y (GBY)-locus and of Y centromere in Turner syndrome patients. *Exp Clin Endocrinol Diabetes*. 2015;123:61-5.
15. Alessandra BT, Roseane L Silva, Marly A, Spadotto B. Prevalence of Y-chromosome sequences and gonadoblastoma in Turner syndrome. *Rev Paul Pediatr*. 2016;34(1):114-21.