



Metastatic Invasive Lobular Breast Carcinoma Mimicking Synchronous Breast and Gastric Cancers

Senkron Meme ve Mide Kanserlerini Taklit Eden Metastatik İnvazif Lobüler Meme Karsinomu

Gökhan Tazegül¹, Melek Karakurt Eryılmaz², Fatma Yalçın Müsri², Betül Ünal³, Gülsüm Özlem Elpek³, Hasan Şenol Coşkun²

¹Department of Internal Medicine, ²Division of Medical Oncology, Department of Internal Medicine, ³Department of Pathology, Akdeniz University Faculty of Medicine, Antalya, Turkey

ABSTRACT

Metastatic lobular carcinoma to stomach is seen as small round cells in linear cords within the normal tissue and it is not easily differentiated from signet cell adenocarcinoma of the stomach. Differentiating synchronous primary gastric carcinoma from metastatic involvement is vital in accurately planning treatment. Herein, we report a case of gastric metastatic invasive lobular breast carcinoma initially misdiagnosed as synchronous gastric and breast carcinoma and discuss the diagnostic and therapeutic challenges.

Key words: breast neoplasms; second primary; stomach neoplasms

ÖZET

Memenin lobüler karsinomunun mide metastazı küçük yuvarlak hücreler olarak gözlenir, lineer kordonlar yapar ve midenin taşlı yüzük hücreli kanserinden ayrımı zordur. Bu ayıncı tanı hastanın tedavisini uygun şekilde planlamada hayati öneme sahiptir. Bu vakada başlangıçta senkron gastrik ve meme karsinomu tanısı konulan, sonrasında metastatik invazif lobüler karsinom tanısı alan olgunun seyri ve bu konuda tanı ve tedavi yaklaşımlarının literatür tartışması sunulmuştur.

Anahtar kelimeler: meme kanseri; ikinci primer; mide kanseri

Introduction

Breast cancer is the most common malignancy in women excluding skin cancers, and it is the second most common cause of cancer related deaths in women. Common metastatic sites of breast carcinoma are liver, bone, lung and brain. Gastrointestinal metastases from breast carcinomas are rare. Herein, we report a case of gastric metastatic invasive lobular breast

carcinoma initially misdiagnosed as synchronous gastric and breast carcinoma and discuss the diagnostic and therapeutic challenges.

Case

A fifty one years old female patient was admitted to general surgery outpatient clinic with dyspeptic complaints. Her symptoms progressively worsened over 6 months. She had hypertension and was on an angiotensin receptor blocker. Family history was positive for colon cancer in her grandfather. Physical examination and routine blood tests were unremarkable. Abdominal ultrasonography revealed multiple gallstones. On upper GI endoscopy, multiple lesions along the lesser curvature of the stomach were seen, biopsy from the lesions showed poorly differentiated adenocarcinoma. Positron emission tomography-computed tomography (PET-CT) revealed multiple hypermetabolic nodular lesions on the upper outer quadrant of the right breast, amassing to a total of 3x1.5 centimeters (SUVmax: 4.1) and multiple gastric lesions were seen along lesser curvature of stomach (SUVmax: 7.1). Breast ultrasound revealed multiple lesions; the most prominent lesion was 12x9x7 millimeters in size. Biopsies from breast demonstrated invasive lobular carcinoma (ER:% 100 3+, PR:% 50 2+, c-erbB2 negative, Grade 3, no lymphovascular or perineural invasion). Patient was diagnosed as synchronous breast and gastric cancer. Biopsy results and PET-CT were both taken into consideration while planning the treatment: since gastric cancer was assessed as locally advanced and would be the main determinant of prognosis, patient was treated with paclitaxel-carboplatin-capecitabine (175 mg/m²

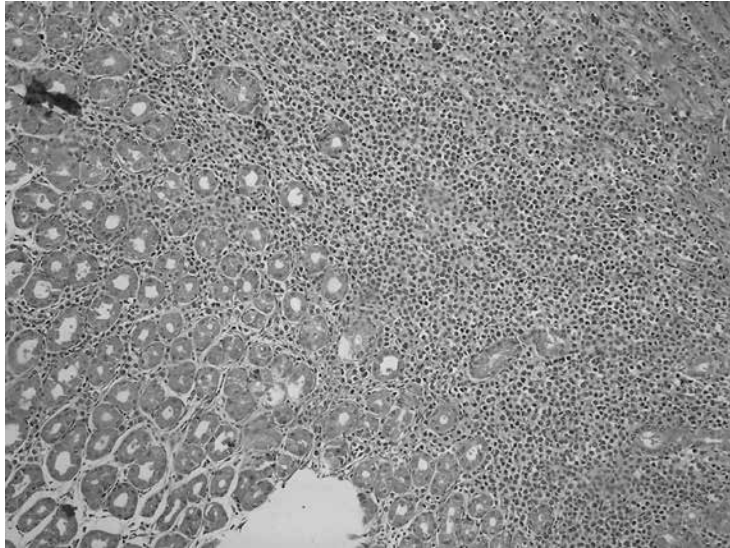


Figure 1. There is a neoplastic infiltration between gastric glandular structures and in lamina propria. (H&E)

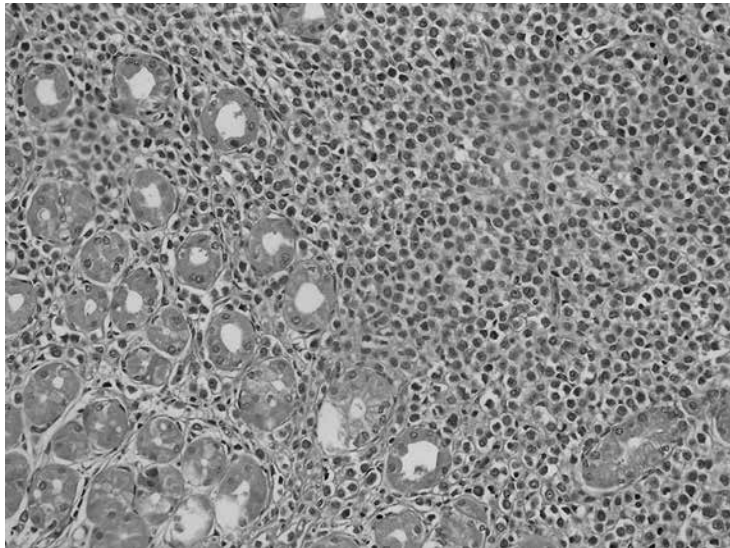


Figure 2. Infiltrative tumor composed of clusters and sheets of tumor cells. (H&E)

paclitaxel D1, 5AUC carboplatin D1, capecitabine 2000 mg/m²/day, D1–14, 21-day cycles) for 3 cycles. After cycle 3, PET-CT showed partial remission on both primaries. Breast mass was reduced to 2x1.5 centimeters (SUV_{max}: 2.5), and only one focus of FDG positivity remained on stomach (SUV_{max}: 7). After cycle 6, PET-CT showed stable disease on breast and gastric cancer showed complete remission. We planned curative surgery for both primary tumors. Firstly, total gastrectomy was performed. Pathological examination of the stomach displayed patchy distribution of poorly differentiated adenocarcinoma foci along the gastric

epithelium, surgical margins were negative for tumor infiltration, tumor cells were prominently located on serosa and muscularis propria rather than mucosa and there were no macroscopic lesions seen on epithelial surface. Twenty lymph nodes out of 26 along the lesser curvature and 6 lymph nodes of out 12 along the greater curvature were positive for metastases. Tumor cells were mucin and mammoglobin negative, they were ER (nuclear strong, 1+) and PR (% 10 nuclear, 2+), CK 7 (+), c-erbB2 (less than% 10 +) positive (Figures 1–3). Immunohistochemistry and pathological appearance of the tumor changed the diagnosis of

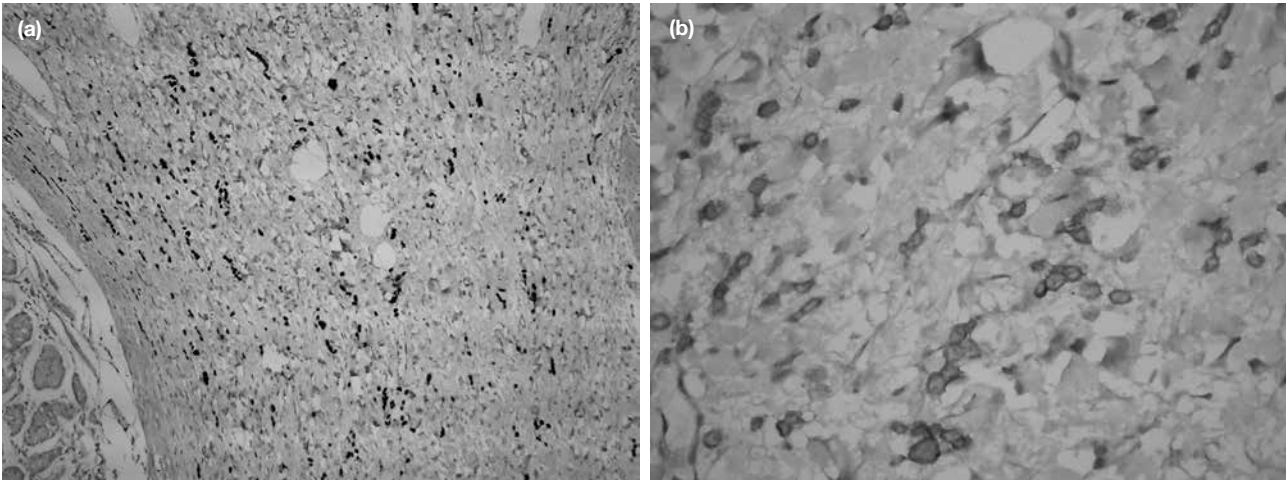


Figure 3. a–b. ER and PR are nuclear positive in tumor cells (a). There are membranous positivity with CK7 and c-erbB2 within the tumor cells (b).

the tumor as metastatic breast cancer rather than primary gastric adenocarcinoma. Patient was re-assessed as metastatic breast cancer and curative surgery of the breast was carried out. Histopathology of the breast revealed MUC-5AC, e-cadherin, mamoglobin and GCDFP-15 negative, CK-18 positive invasive lobular carcinoma (ER:% 95 3+, PR:% 55 3+, c-erbB2 negative, Grade 3). She is now in complete remission 6 months postoperatively.

Discussion

Breast cancer is the most common malignancy in women excluding skin cancers, and it is the second most common cause of cancer related deaths in women. Common metastatic sites of breast carcinoma are liver, bone, lung and brain. Nearly half of patients with breast carcinomas will develop metastases during the disease course. Gastrointestinal metastases from breast carcinomas are rare¹. Although in autopsy studies, presence of gastrointestinal lesions is shown to be 11% of all breast cancer metastases, the overall clinical incidence of gastrointestinal metastases is estimated to be as low as 0.5%. In approximately 1% of cases, gastrointestinal lesions may be the first metastasis². However, isolated gastrointestinal metastases of breast carcinomas are seen less often; in this case, we reported an isolated gastric metastasis of breast carcinoma.

The interval between the diagnosis of the breast lesion and the lesion in the stomach has ranges from simultaneous to 30 years³. Although most cases presented in the literature are consequent diagnoses of breast

carcinomas and gastric metastases, the opposite sequence (gastric metastasis as the first diagnosis) was presented as a case report as well⁴. Synchronous metastasis of lobular breast cancer to the stomach and colon without liver metastasis or peritoneal dissemination is extremely rare, with only five reported cases⁵. This is the sixth case report, to the best of our knowledge, of a synchronous gastric metastasis of breast cancer without other organ involvement.

Gastrointestinal metastases may be asymptomatic; they may present with nausea, vomiting or abdominal pain. They may be seen as an obstructing mass, linitis plastica pattern, a bleeding ulcer or simply a nodule⁶. Cases of simultaneous breast carcinoma with intestinal obstruction was previously reported⁷; however, it is extremely uncommon that invasive breast carcinoma presents with gastric metastatic complaints without any other organ involvement⁸. Our patient was one of the rare patients presenting with dyspeptic complaints rather than primary complaints regarding breasts.

Metastatic lobular carcinoma to stomach is seen as small round cells in linear cords within the normal tissue and it is not easily differentiated from signet cell adenocarcinoma of the stomach¹. In our case, first gastroscopic biopsy showed poorly differentiated adenocarcinoma; however, after surgery, immunohistochemistry and pathological appearance of the tumor changed the diagnosis of the tumor as metastatic breast cancer rather than primary gastric adenocarcinoma. Similar diagnostic challenges have

been discussed in the literature. Schwarz et al.⁷ recommended histopathologic and immunohistochemical comparison of breast cancer and the gastrointestinal (GI) tumor for differentiating second primary or metastatic involvement. Estrogen receptor, progesterone receptor and c-erbB2 status can help distinguish primary gastric carcinoma from metastatic involvement. However, even if the primary breast tumor is positive for estrogen receptor, progesterone receptor or c-erbB2; some primary gastric cancers may be estrogen receptor, progesterone receptor and c-erbB2 positive as well. In one study with gastric cancer patients, estrogen receptor positivity was 27.7% for males and 31.0% for females, while progesterone receptor positivity was 9.2% for males and 11.9% for females⁹. In HER-EAGLE Study including a total of 4949 patients¹⁰, overall HER2 positivity for gastric cancer was 12.9%. If the primary breast cancer is negative for these markers, it cannot be used as a marker⁷.

Differentiating synchronous primary gastric carcinoma from metastatic involvement is vital in accurately planning treatment. Literature states that a second primary tumor could be offered surgery on curative aim; however, metastatic disease requires systemic chemotherapy and is associated with poor prognosis¹¹. However, treatment of gastric metastases of primary breast carcinoma is hormone therapy or chemotherapy. It is recommended that surgery in such metastatic patients should only be reserved for palliation of obstruction, bleeding or perforation¹. In this case, due to the diagnostic challenge, we treated the patient as synchronous gastric and breast carcinomas initially, which had a good response to chemotherapy. It was revealed only after surgery that the initial diagnosis was wrong, regardless, patient had a curative surgery of her metastatic site. After surgery, primary tumor was resected as well and patient had complete remission afterwards.

In conclusion, synchronous gastric metastasis of invasive lobular carcinoma is very rare. Patients may present with dyspeptic complaints rather than primary breast complaints. Diagnosis of such patients requires exhaustive immunohistochemistry analysis and tissue samples to differentiate synchronous primary gastric carcinomas from metastatic involvement, since it is mainstay of the treatment plan. Chemotherapy is recommended for patients with metastatic involvement; however, curative surgery may be planned in patients with a single metastatic area as well.

References

1. Rachan Shetty KS, Challa VR, Lakshmaiah KC, Champaka G, Babu KG. Gastric metastases from breast cancer: A report of two cases and review of literature. *J Cancer Res Ther* 2015;11:660.
2. Zhang B, Copur-Dahi N, Kalmaz D, Boland BS. Gastrointestinal manifestations of breast cancer metastasis. *Dig Dis Sci* 2014;59:2344–6.
3. Ellis MC, Mason T, Barnett J, Kiesow LL, Vetto JT. Gastric malignancies in breast cancer survivors: pathology and outcomes. *Am J Surg* 2009;197:633–636.
4. Buka D, Dvořák J, Richter I, Hadzi ND, Cyrany J. Gastric and Colorectal Metastases of Lobular Breast Carcinoma: A Case Report. *Acta Medica (Hradec Kralove)* 2016;59:18–21.
5. Takeuchi H, Hiroshige S, Yoshikawa Y, Kusumoto T, Muto Y. A case of synchronous metastasis of breast cancer to stomach and colon. *Anticancer Res* 2012;32:4051–5.
6. Ambroggi M, Stroppa EM, Mordenti P, Biasini C, Zangrandi A, Michieletti E, et al. Metastatic breast cancer to the gastrointestinal tract: Report of five cases and review of the literature. *Int J Breast Cancer* 2012;2012:439023.
7. Schwarz RE, Klimstra DS, Turnbull ADM. Metastatic breast cancer masquerading as gastrointestinal primary. *Am J Gastroenterol* 1998;93:111–114.
8. Zuhair AR, Maron AR. Occult bilateral invasive lobular carcinoma of the breast presenting as gastroduodenal metastases: a case report. *Breast Dis* 2015;35:63–5.
9. Matsui M, Kojima O, Kawakami S, Uehara Y, Takahashi T. The prognosis of patients with gastric cancer possessing sex hormone receptors. *Surg Today* 1992;22:421–5.
10. Kim WH, Gomez-Izquierdo L, Vilardell F, Chu KM, Soucy G, Dos Santos LV, et al. HER2 Status in Gastric and Gastroesophageal Junction Cancer: Results of the Large, Multinational HER-EAGLE Study. *Appl Immunohistochem Mol Morphol*. Epub 2016 Aug 3.
11. Jones GE, Strauss DC, Forshaw MJ, Deere H, Mahedeva U, Mason RC. Breast cancer metastasis to the stomach may mimic primary gastric cancer: report of two cases and review of literature. *World J Surg Oncol* 2007;5:75.