

Management of traumatic pneumothorax in isolated blunt chest trauma

Murat Sarıçam¹, Berker Özkan², Yaşar Türk³

¹Department of Thoracic Surgery, Namık Kemal University School of Medicine, Tekirdağ, Turkey

²Department of Thoracic Surgery, İstanbul University School of Medicine, İstanbul, Turkey

³Department of Radiology, Namık Kemal University School of Medicine, Tekirdağ, Turkey

DOI: 10.18621/eurj.375947

ABSTRACT

Objectives: Pneumothorax is an important complication of blunt chest trauma. The aim of this study was to report our experience in treatment strategy and outcomes of traumatic pneumothorax.

Methods: A total of 78 patients who developed pneumothorax due to isolated blunt chest trauma were evaluated in terms of age, gender, size of pneumothorax, treatment methods, complications and length of hospital stay. The size of pneumothorax was calculated with computer-aided volumetry.

Results: Tube thoracostomy was performed for 48 patients while observation was undertaken for 30 cases. Chest tubes were inserted in 6 patients after 24 hours following the traumatic event. A total of 8 patients who developed prolonged air leakage and hemothorax as complications underwent video-assisted thoracoscopic surgery. None of the patients developed any mortality or morbidity.

Conclusions: Traumatic pneumothorax demands prompt diagnosis and treatment. Monitoring all patients even with small sizes of traumatic pneumothorax for at least 24 hours onset of their initial assessment and applying chest tubes for cases who have pneumothorax larger than 50% at first examination should be an appropriate modality for treatment. Moreover, the minimally invasive approach of video-assisted thoracoscopic surgery benefits to overcome the complications of thoracic trauma.

Keywords: Blunt chest trauma, traumatic pneumothorax, treatment

Received: January 8, 2018; Accepted: February 15, 2018; Published Online: May 23, 2018

A pneumothorax is defined as collection of air in the pleural space. It is present in 40 to 50% of patients suffering thoracic trauma [1]. Prompt diagnosis and treatment of traumatic pneumothorax is essential for these patients.

Massive or tension pneumothorax is frequently recognized clinically before imaging. On the other hand, several studies suggest that large number of pneumothoraces diagnosed by computerized tomography (CT) are missed on initial chest X-rays

termed occult pneumothorax [2, 3].

Current treatment guidelines recommend urgent chest tube insertion for patients who have unstable clinical conditions and symptoms; such as hypoxia, hypotension or an impaired level of consciousness [4, 5]. However, the optimal management for stable patients continues to be debated considering that complication and failure of inappropriate interventions may rate up to 30% [6].

We report treatment methods, points demanding



Address for correspondence: Murat Sarıçam, MD., Assistant Professor, Namık Kemal University School of Medicine, Department of Thoracic Surgery, Süreyyapaşa, Tekirdağ, Turkey
E-mail: msaricam@nku.edu.tr

e-ISSN: 2149-3189

Copyright © 2019 by The Association of Health Research & Strategy
Available at <http://dergipark.gov.tr/eurj>

caution and outcomes in patients with traumatic pneumothorax in our institution.

METHODS

We conducted a retrospective study to clarify the treatment strategy and outcomes in patients with the diagnosis of traumatic pneumothorax. A total of 78 patients throughout 1,428 trauma cases who admitted to our emergency unit between December 2011 and April 2017 were included in the study. All cases had pneumothorax due to isolated blunt thoracic trauma.

The patients were divided into 4 groups considering the initial size of pneumothorax diagnosed via thorax CT at the initial assessment: Group A (n = 12, <10%), Group B (n = 18, 10-20%), Group C (n = 22, 20-50%) and Group D (n = 26, >50%). All the patient groups were evaluated in terms of age, gender, treatment method and length of hospital stay. Treatment method included conservative approach and chest tube insertion. Regardless of the way of approach, all patients were closely monitored applying nasal oxygen therapy at 3 L/hour and examined with daily chest X-rays. Patients under observation who developed clinical or radiological deterioration, such as oxygen desaturation or increase in the size of preexisting pneumothorax underwent tube thoracostomy urgently. All tube thoracostomies were performed under local anesthesia using 24 French (F) chest tubes by the same two thoracic surgeons.

Hospital stay revealed the time between the admittance to the emergency unit and the discharge of the patients. Cases treated via tube thoracostomy were discharged the day after chest tube removal. Complications were noted for each group of patients.

Pneumothorax was diagnosed upon CT findings for all patients. Besides, radiological studies were carried out retrospectively by the same radiologist using the same CT and CT computer. Size of the pneumothorax was calculated with the guidance of computer-aided volumetry (CAV).

RESULTS

We have 48 (61.5%) male and 30 (38.5%) female patients with a median age of 35.3 years (range, 6-68 years). Cause of the blunt thoracic trauma was car accident in 34 (43.6%) , fall from heights in 24 (30.8%), beating in 14 (17.9%) and jamming under heavy objects in 6 (7.7%) patients. Accompanying thoracic injuries were pulmonary contusion in 34, fractured ribs in 23, clavicle fracture in 8, scapula fracture in 3 and combination of these pathologies in 14 cases , respectively. Concerning that additional surgery and healing period were necessary, patients who had injuries to thoracic vertebra or diaphragm were not included in this study. Etiology and accompanying injuries are given in Figure 1.

Pneumothorax was right sided in 34 (43.6%) , left sided in 37 (47.4%) and bilateral in 7 (9%) patients. A

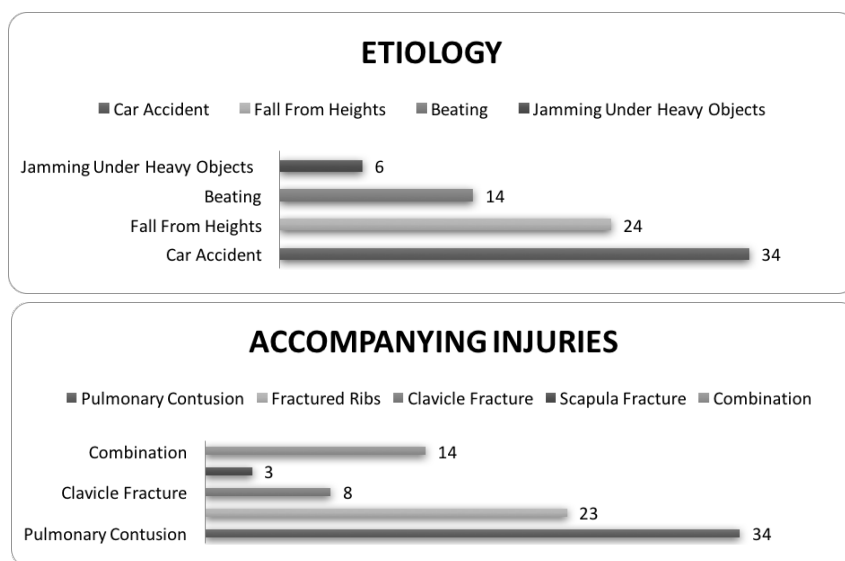


Figure 1. Etiology and accompanying thoracic injuries

Table 1. Distribution of patients

Parameters	Group A	Group B	Group C	Group D	Total
Age (mean, years)	28.4	41.3	32.6	38.8	35.3
Gender (n) (male/female)	9/3	12/6	11/11	16/10	48/30
Treatment (n) (Observative / Chest tube)	10/2	10/8	10/12	-/26	30/48
Hospital stay (mean, days)	1.8	4.1	7.4	10.6	6.1

Group A = the initial size of pneumothorax < 10%, Group B = the initial size of pneumothorax of 10-20%, Group C = the initial size of pneumothorax of 20-50%, Group D = the initial size of pneumothorax > 50%

total of 48 patients underwent tube thoracostomy whilst conservation was undertaken for remaining 30 cases.

Ten patients in Group A were discharged without any surgical procedures. However, 2 patients of this group had chest tubes in 24 hours after their admittance due to the increases in size of pneumothorax. Group B had observative approach for 10 and tube thoracostomy for 8 patients as the treatment method. Ten patients of Group C were only monitored carefully and the remaining 12 cases of this group underwent tube thoracostomy. Similarly, 2 patients in each of Group B and C had their chest tubes in the next 24 hours following their admittance. Taking a stand on corrupted clinical status, all the patients in Group D were treated with tube thoracostomy in sequel of their initial evaluation in the emergency unit.

Mean hospital stay was 1.8 days for Group A, 4.1 for Group B, 7.4 for Group C and 10.6 for Group D, respectively.

Group C had 2 and Group D had 4 patients who underwent video-assisted thoracoscopic surgery (VATS) with the diagnosis of prolonged air leakage due to parenchymal damage. Moreover, VATS was performed for 2 patients in Group D for hemothorax which emerged subsequently as a delayed complication of fractured ribs.

A total of 6 (12.5%) patients of all tube thoracostomies were treated with additional chest tubes upon the diagnosis of subcutaneous emphysema, malposition of the chest tube and failure in the expansion of the lung. Further surgical intervention was not necessary for these cases. Data related to the general distribution of patients are given in Table 1.

None of the patients developed mortality or morbidity. One patient in Group A and 2 patients in

Group C developed recurrence of pneumothorax after the tenth day following discharge, recognized on chest X-ray but showing no related clinical signs and underwent tube thoracostomy again.

DISCUSSION

Management of traumatic pneumothorax is still debatable concerning the watch or act strategy for its treatment. Percentage of the initial traumatic pneumothorax and the general medical status of the patients should be accepted to be the main points for setting up decisions. Although some of the recent studies in the literature advocate tube thoracostomies for pneumothoraxes larger than 20%, our paper suggests that one third of the cases in the same aspect require chest tubes.

Presence of pneumothorax following blunt trauma is related to the severity of the injury. Pneumothorax may appear upon the laceration of the visceral pleura secondary to fractured ribs or rupture of the alveoli resulting from sudden compression of the chest [7, 8].

Diagnosis of pneumothorax becomes absolute on clinical and radiological findings. Symptoms of a pneumothorax include chest pain, shortness of breath, rapid heartbeat and breathing which may be confused with other pathologies of a trauma patient. Auscultation of the chest reveals decreased or absent breath sounds over the affected lung. Diagnosis shall be confirmed by chest X-ray, CT or chest ultrasonography (US) since the clinical diagnosis of pneumothorax based solely on auscultation is incorrect in 20-30% of cases [9]. Although some authors reported that chest US was more sensitive and accurate than chest X-rays, CT is still accepted to be the reference standard in detection of traumatic pneumothoraces [5, 7, 9]. Chest X-rays are also

appropriate and cost-effective to be scheduled daily for the follow-up of patients.

Success rate of conservative approach in small and anteriorly localized pneumothoraces is 81% [9]. However, it is a well known fact that mechanical ventilation increases the risk of size increment of existing pneumothorax or development of tension pneumothorax in 20% of small pneumothoraces [10]. Recent papers supported that chest tubes are unnecessary for patients who developed less than 2 fractured ribs or pneumothorax smaller than 20% in size or who did not require mechanical ventilation [11-13]. Our current study included 30 patients with a pneumothorax less than 20% in size. Of these, 10 (33%) cases underwent tube thoracostomy proving that size of the initial pneumothorax does not make an exact criteria for treatment. Regardless of the initial size of traumatic pneumothorax, all the patients should be carefully observed in means of increasing or newly developing pneumothoraces for 24 hours at least to reach a final decision for discharge.

Although numerous studies have reported that a chest tube can be used as the sole treatment for traumatic pneumothorax, persistent air leak or failure in lung expansion in 4-23% of cases sometimes require additional treatment and prolonged hospital stay. Furthermore, tube thoracostomy may bring along complications such as nonfunctioning or malposition of chest tube, wound infection, abdominal or thoracic injury and vascular trauma in 2-10% of the patients [4-6]. Advantages of minimally invasive surgery offered by VATS have oriented many institutions to accept this method as the preferred treatment for patients with chest trauma [14]. As noted above, 8 patients with the diagnosis of prolonged air leakage and hemothorax underwent VATS without encountering any further complications or morbidity.

CONCLUSION

Pneumothorax is a life-threatening complication of chest trauma which requires immediate diagnosis and treatment. In our experience, rigorous observation of the trauma patients both clinically and radiologically avoided mortality. We believe that all patients with even small sizes of pneumothoraces shall be monitored for at least 24 hours after the traumatic

event, considering that most of the complications occur within this period. Detoriation in clinical status and increase of pneumothorax identified by radiological follow-up studies shall alert surgeons to insert chest tubes. We also suggest that cases who have pneumothorax larger than 50% at their first assessment shall urgently undergo tube thoracostomy. Moreover, our surgical experience with VATS in trauma patients support it as an effective modality for the treatment of complicated thoracic trauma.

Conflict of interest

The authors disclosed no conflict of interest during the preparation or publication of this manuscript.

Financing

The authors disclosed that they did not receive any grant during conduction or writing of this study.

REFERENCES

- [1] Haynes D, Baumann M. Management of pneumothorax. *Semin Respir Crit Care Med* 2010;31:769-80.
- [2] Matsumoto S, Kishikawa M, Hayakawa K, Narumi A, Matsunami K, Kitano M. A method to detect occult pneumothorax with chest radiography. *Ann Emerg Med* 2011;57:378-81.
- [3] Sangster G, Gonzales-Beicos A, Carbo A, Heldmann M, Ibrahim H, Carrascosa P, et al. Blunt traumatic injuries of the lung parenchyma, pleura, thoracic wall and intrathoracic airways: multidetector computer tomography imaging findings. *Emerg Radiol* 2007;14:297-30.
- [4] Henry M, Arnold T, Harvey J. Pleural Diseases Group, Standards of Care Committee, British Thoracic Society. BTS guidelines for the management of spontaneous pneumothorax. *Thorax* 2003;58:39-52.
- [5] Baumann M, Strange C, Hefner JE, Light R, Kirby TJ, Klein J, et al. Management of spontaneous pneumothorax: an American College of Chest Physicians Delphi consensus statement. *Chest* 2001;119:590-602.
- [6] Cai W, Lee JG, Fikry K, Yoshida H, Novelline R, Moya M. MDCT quantification is the dominant parameter in decision-making regarding chest tube drainage for stable patients with traumatic pneumothorax. *Comp Med Imag* 2012;36:375-86.
- [7] Richardson JD, Miller FB, Carrillo EH, Spain DA. Complex thoracic injuries. *Surg Clin North Am* 1996;76:725-58.
- [8] Yladom MY, Platz E, Brown DF, Nadel ES. Pneumothorax in a blunt trauma patient. *J Emerg Med* 2008;35:199-203.
- [9] Chad GB, Kirkpatrick AW, Feliciano DV. The occult pneumothorax: What have we learned? *Can J Surg* 2009;52:173-9.
- [10] Reddy VS. Minimally invasive techniques in thoracic trauma. *Semin Thorac Cardiovasc Surg* 2008;20:72-7.
- [11] Ball CG, Kirkpatrick AW, Laupland KB, Fox DL, Litvinchuk S, Dyer DM. Factors related to the failure of radiographic recognition of occult posttraumatic pneumothoraces. *Am J Surg* 2005;189:541-46.
- [12] Kesieme EB, Dongo A, Ezemba N, Irekpita E, Jebbin N, Kesieme C. Tube thoracostomy: complications and its management. *Pulm Med* 2012;25:68-78.
- [13] Lin YC, Tu CY, Liang SJ. Pigtail catheter for the management of

pneumothorax in mechanically ventilated patients. *Am J Emerg Med* 2010;28:466-71.
[14] Fabbrucci P, Nocentini L, Secci S, Manzoli D, Bruscano A, Fedi M.

Video-assisted thoracoscopy in the early diagnosis and management of post-traumatic pneumothorax and hemothorax. *Surg Endosc* 2008;22:1227-31.



This is an open access article distributed under the terms of Creative Commons Attribution-NonCommercial-NoDerivatives 4.0 International License.