

Coronary artery bypass grafting in a renal transplant patient: case report

Kıvanç Atılğan¹, Ertan Demirdaş¹, Mediha Boran², Zafer Cengiz Er¹, Ferit Çiçekçioğlu¹

¹Department of Cardiovascular Surgery, Bozok University School of Medicine, Yozgat, Turkey

²Department of Nephrology, Bozok University School of Medicine, Yozgat, Turkey

DOI: 10.18621/eurj.386681

ABSTRACT

The patients with end-stage renal disease have an increased risk of atherosclerosis and the probability of cardiovascular diseases. Due to the use of immunosuppressive agents, the patients having renal graft carry an additional risk of atherosclerosis or endocarditis. A 67-year-old male patient with a history of renal transplantation was referred to our hospital with a severe chest pain and dyspnea. After diagnosing severe ischemic coronary artery disease by coronary angiography, the patient underwent a successful operation of a single vessel coronary artery bypass grafting (CABG) in beating heart. Up to 20% of post-renal transplantation mortality is attributed to cardiovascular diseases. Graft rejection, the need of hemodialysis, perioperative infection are some of the major complications for renal transplant patients undergoing CABG surgery. Off-pump CABG (OPCABG) surgery is a less invasive technique in comparison with CABG with cardiopulmonary bypass (CPB), and protects the patient from negative effects of CPB such as complement system activation, inflammatory mediator secretion, thrombocytopenia, clotting disorders. We recommend to prefer OPCABG and have preoperative prophylaxis in order to avoid both perioperative infection and renal graft rejection in renal transplant patients undergoing CABG surgery.

Keywords: Coronary artery bypass grafting, renal transplant, cardiopulmonary bypass, beating heart, immunosuppressive treatment

Received: January 30, 2018; Accepted: March 11, 2018; Published Online: June 4, 2018

Following to renal transplantation, patients with end-stage renal disease have improved a remarkable survey and a better life quality. However, these patients have an increased risk of atherosclerosis and cardiovascular diseases due to the use of immunosuppressive agents [1-4]. Renal transplant patients undergoing coronary artery bypass grafting (CABG) also are under the risk of higher rates of postoperative complications such as graft rejection, infection or impairment of renal function.

CASE PRESENTATION

A 67-year-old male patient with a history of renal transplantation in 2008 was referred to our hospital with a severe chest pain and dyspnea aggravating by effort. The angina got over with resting and 5 mg of sublingual isosorbide dinitrate. Functional capacity was class III (New York Heart Association (NYHA) classification, 2011). The patient used prednisolone 10 mg 1x1 (Oral), Tacrolimus 1000 mcg 1x2 (Oral), and



Address for correspondence: Kıvanç Atılğan, MD., Bozok University School of Medicine, Department of Cardiovascular Surgery, Yozgat, Turkey
E-mail: kivanccatilgan@gmail.com

Copyright © 2019 by The Association of Health Research & Strategy
Available at <http://dergipark.gov.tr/eurj>

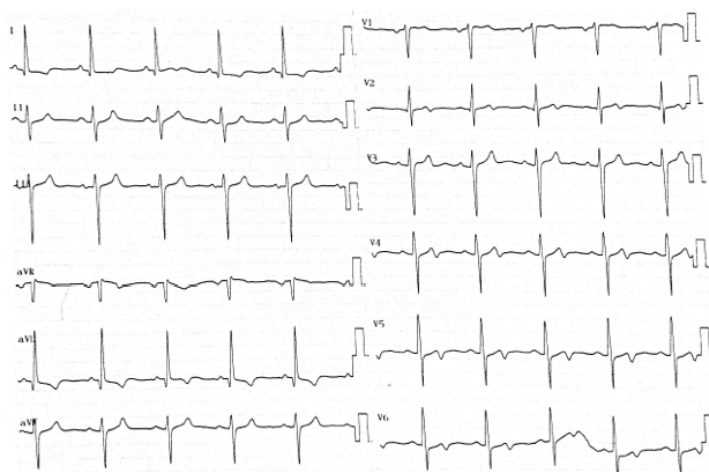


Figure 1. Electrocardiogram of the patient.

Mycophenolate 500 mg 1x2 (Oral) since 2008.

On the physical examination; systemic arterial pressure was measured 129/71 mmHg, and heart beat was rhythmic and 74/min. Two old scar tissues of previously opened and non-functional arteriovenous fistulas on the proximal and distal anterior parts of left forearm were observed. Cardiac and pulmonary auscultation was non-specific.

Preoperative blood urea nitrogen (BUN) and creatinine were 15 mg/dL and 1.09 mg/dL. Other hematologic data were normal as well. Electrocardiogram showed biphasic T waves in V4-6 derivations (Figure 1). On the transthoracic echocardiography ejection fraction was 55%. On the percutaneous coronary angiography 95% occlusion was observed in the proximal part of the left anterior descending artery (LAD) and without any serious

occlusive disease in other coronary arteries (Figure 2).

The patient was hospitalized in a single bad room and Ertapenem 1000 mg 1x1 (IV) was ordered in order to have a prophylaxis due to immunosuppressive therapy. Immunosuppressive therapy was organized as in Table 1. The patient underwent a successful CABG in beating heart, left internal mammarian artery (LIMA) was anastomosed to LAD. Oral treatment of prednisolone was ordered as intravenous form with the highest dose in the operation day and the dose decreased day by day until the postoperative sixth day. On the postoperative seventh day oral prednisolone was started again. The patient was discharged without any complication on the postoperative tenth day. BUN and creatinine levels at discharge were 18 mg/dL and 1.12 mg/dL.

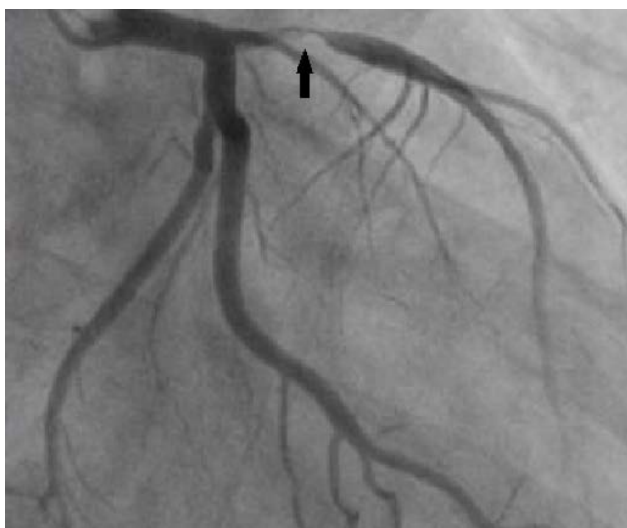

Figure 2. Coronary angiogram shows the LAD lesion (arrow). LAD = left anterior descending coronary artery.

Table 1. Immunosuppressive drugs management during operational process

Time	Prednisolone	Tacrolimus	Mycophenolate
Preoperative 06:00	250 mg (IV)	1000 mg 1x2 (Oral)	500 mg 1x2 (Oral)
Postoperative Day 1	125 mg (IV)	1000 mg 08:00	500 mg 10:00
		1000 mg 20:00	500 mg 22:00
Postoperative Day 2	100 mg (IV)	1000 mg 08:00	500 mg 10:00
		1000 mg 20:00	500 mg 22:00
Postoperative Day 3	80 mg (IV)	1000 mg 08:00	500 mg 10:00
		1000 mg 20:00	500 mg 22:00
Postoperative Day 4	60 mg (IV)	1000 mg 08:00	500 mg 10:00
		1000 mg 20:00	500 mg 22:00
Postoperative Day 5	40 mg (IV)	1000 mg 08:00	500 mg 10:00
		1000 mg 20:00	500 mg 22:00
Postoperative Day 6	20 mg (IV)	1000 mg 08:00	500 mg 10:00
		1000 mg 20:00	500 mg 22:00
Postoperative Day 7	10 mg (Oral)	1000 mg 08:00	500 mg 10:00
		1000 mg 20:00	500 mg 22:00

DISCUSSION

Renal transplant patients have many risk factors for coronary artery disease due to the nature of end-stage renal disease and immunosuppressive drugs [1-3] Up to 20% of post-renal transplantation mortality is attributed to cardiovascular diseases such as acute coronary syndrome (ACS) [3].

In a renal transplant patient referring to a medical center with ACS, percutaneous coronary intervention (PCI) has a low success rate due to the calcification of the coronary arteries, which is a common problem of end-stage renal disease [5, 6]. CABG is usually a better treatment solution for these patients.

The rejection of the renal graft and renal dysfunction, the need of hemodialysis, perioperative infection are some of the major complications for renal transplant patients undergoing CABG surgery. Performing CABG with cardiopulmonary bypass (CPB) has additional risk factors due to its effects such as inflammatory activation, volume overload, increased blood concentration of immunosuppressant [7, 8] and perfusion pressure, low urine output [7-9]. Because of that, in renal transplant patients undergoing CABG with CPB, addition of mannitol and human albumin in hemofilter and prime solution, and less preparation of prime solution, and decreased transfusion of blood products may help avoiding the negative effects of CPB.

Off-pump coronary artery bypass grafting

(OPCABG) surgery is a less invasive technique in comparison with CABG with CPB, and protects the patient from negative effects of CPB as mentioned before. In a renal transplant patient, aortic calcification is severe and use of CPB may be difficult. That's why; performing CABG surgery in a renal transplant patient in off-pump technique would be a better option.

Perioperative infection is another serious complication for renal transplant patients undergoing CABG due to immunosuppressive treatment. Because of that, hospitalizing the patient in a private room and ordering a wide-spectrum antibiotic would be helpful for prophylaxis.

The rejection of the renal graft and renal dysfunction are major critic problems. In order to minimize these fatal complications, we prefer to order the oral corticosteroid treatment as intravenous form starting from the operation day with the highest dose as 250 mg of prednisolone until the postoperative sixth day with the lowest dose of 20 mg. On the postoperative seventh day we order the oral standart 10 mg dose of prednisolone.

CONCLUSION

As a result, we recommend to prefer OPCABG and have preoperative prophylaxis in order to avoid both perioperative infection and renal graft rejection in renal transplant patients undergoing CABG surgery.

Authorship declaration

All authors listed meet the authorship criteria according to the latest guidelines of the International Committee of Medical Journal Editors, and all authors are in agreement with the manuscript.

Informed consent

Written informed consent was obtained from the patient for publication of this case report and any accompanying images.


Conflict of interest

The authors declared that there are no potential conflicts of interest with respect to the research, authorship, and/or publication of this article.

REFERENCES

- [1] Taketani S, Fukushima N, Ohtake S, Sawa Y, Nishimura M, Matsuda H. Coronary artery bypassgraft in a renal transplant recipient. *Jpn J Thorac Cardiovasc Surg* 2000;48:542-4.
- [2] Lansing AM, Masri ZH, Kralakulasingam R, Martin DG. Angina during hemodialysis. Treatment by coronary bypass graft. *JAMA* 1975;232:736-7.
- [3] Frye EB, Vazziri ND, Martin DC, Frarooqui S. Cardiovascular pathology in renal transplant recipients. *J Nat Med Ass* 1986;78:1187-91.
- [4] Yao H, Smilovitch M, Cecere R, Sandal S, Paraskevas S, Baran D, et al. Sequential and urgent coronary artery bypass surgery followed by kidney transplantation in a highly sensitized patient with unstable angina. *Transplantation* 2018;102:e41-2.
- [5] Sakao T, Kashu Y, Nakagawa H, Kajiwarra S. Off-pump coronary artery bypass grafting in two renal transplant patients. *Jpn J Thorac Cardiovasc Surg* 2003;51:678-80.
- [6] Christiansen S, Splittgerber FH, Marggraf G, Claus M, Philipp T, Zerkowski HR, et al. Results of cardiocoperations in five kidney transplant patients. *Thorac Cardiovasc Surg* 1997;45:75-7.
- [7] Noda H, Fujimura Y, Gohra H, Hamano K, Katoh T, Esato K. Coronary bypass surgery after renal transplantation. *Jpn J Thorac Cardiovasc Surg* 1999;47:135-40.
- [8] Ando M, Koyanagi H, Endo M, Nishida H, HachidaM, Teraoka S. [A report of two cases of coronary bypass surgery after renal transplantation]. *Nihon Kyobu Geka Gakkai Zasshi* 1993;41:2126-30. [Article in Japanese]
- [9] Bolman RM 3rd, Anderson RW, Molina JE, SchwartzJS, Levine B, Simmons RL, et al. Cardiac operations in patients with functioning renal allografts. *J Thorac Cardiovasc Surg* 1984;88:537-43.

[1] Taketani S, Fukushima N, Ohtake S, Sawa Y, Nishimura M, Matsuda H. Coronary artery bypassgraft in a renal transplant recipient. *Jpn J*



This is an open access article distributed under the terms of Creative Commons Attribution-NonCommercial-NoDerivatives 4.0 International License.