

Management of catheter-related complications during intraperitoneal chemotherapy for ovarian cancer: Two case reports and review of the literature

Over kanserinde intraperitoneal kemoterapi esnasında gelişen kateter ilişkili komplikasyonların yönetimi: İki olgu sunumu ve literatür derlemesi

Gunsu KIMYON COMERT, Osman TURKMEN, Alper KARALOK, Derman BASARAN, Cigdem KILIC, Sevgi KOC, Fulya KAYIKCIOGLU, Nurettin BORAN

ABSTRACT

In this article, we presented two cases with catheter-related complications that occurred during intraperitoneal chemotherapy (IPC) following comprehensive cytoreductive surgery for ovarian carcinoma. One of the patients had bowel perforation which was managed by removing the port and creating a colostomy. The other had catheter blockage that was managed by releasing the catheter from the fibrous adhesion. Both patients completed all cycles of chemotherapy without delay. IPC following optimal cytoreductive surgery in serous ovarian carcinoma holds promise to improve survival. Catheter-related complications are one of the major barriers that health care centers experience with the use of catheters in clinical practice. Yet, they can be managed without having any delays in chemotherapy treatments.

Keywords: Ovarian cancer, Intraperitoneal chemotherapy, Catheter-related complication

ÖZ

Bu çalışmada, over kanseri tanısıyla sitoredüktif cerrahiye takiben uygulanan intraperitoneal kemoterapi (İPK) esnasında meydana gelen kateter ilişkili komplikasyona sahip iki hasta sunulmuştur. Hastalardan birinde bağırsak perforasyonu gelişmiştir. Port çıkarılmış ve kolostomi uygulanmıştır. Diğer hastada ise, kateterde blokaj gelişmiş ve kateter boyunca uzanan fibröz adezyonun serbestleştirilmesi ile komplikasyon yönetilmiştir. Kemoterapi her iki olguda da gecikme olmaksızın 16 haftada tamamlanmıştır. Seröz over kanserinde optimal sitoredüktif cerrahi sonrası İPK, sağkalımı artırarak umut vaad etmektedir. Klinik uygulamaya adaptasyonu zorlaştıran nedenlerin başında gelen kateter ilişkili komplikasyonlar kemoterapinin tamamlanmasında gecikme olmaksızın yönetilebilmektedir.

Anahtar kelimeler: Over kanseri, Intraperitoneal kemoterapi, Kateter ilişkili komplikasyon

Introduction

Epithelial ovarian cancer (EOC) especially the serous type, is in tendency to spread to mesothelial cell covered body cavities by exfoliation of malignant cells [1]. Advanced disease that have dissemination covering the entire peritoneal surface such as visceral peritoneum of intra-abdominal organs, parietal peritoneum and diaphragm is usually encountered [1]. EOC is one of the most common gynecological cancers with high mortality rates worldwide [2]. Because of the absence of screening methods, researchers are focused on the therapy options.

Although, the current standard therapy is cytoreductive surgery by achieving a less than 1 cm residual tumor combined with chemotherapy, researches continue on alternative therapies to improve the survival [3]. Nowadays,

Gunsu Kimyon Comert (✉), Osman Turkmen, Alper Karalok, Derman Basaran, Cigdem Kilic, Sevgi Koc, Fulya Kayikcioglu, Nurettin Boran
Gynecologic Oncology Clinic, Etlik Zubeyde Hanim Women's Health Teaching and Research Hospital, Ankara, Turkey
e-mail: gunsukimyon@gmail.com

Submitted / Gönderilme: 07.02.2018 Accepted/Kabul: 04.04.2018

although the common way of administering chemotherapy is intravenous, intraperitoneal way attracts a great deal of attention because of its counteraction effect for the natural spread of disease and results of recent trials related to intraperitoneal chemotherapy (IPC) which demonstrated improvements in survival [4-7].

Based on the meta-analysis that was reported on the improved disease-free and overall survival in patients treated with IPC, National Cancer Institute (NCI; US) suggested IPC as a preferred therapy in patients who had optimally debulked front-line surgery for advanced ovarian cancer [7,8]. Although, this suggestion was announced in 2006, IPC could not be adopted into practice in many clinics. The reasons of adaptation barriers are lack of experience about the insertion technique, apprehension about the port or catheter complications and delay in therapy. Therefore, we aimed to present the catheter-related complications in 2 cases while receiving IPC following the extended cytoreductive surgery and to improve the awareness of the catheter-related complications.

Case Reports

Between June 2015 and October 2016, data of 2 cases who had catheter-related complications during IPC were evaluated. They had cytoreductive surgery due to ovarian carcinoma.

Technique and protocol: Intraperitoneal port (DistricAtch®245, 9.3F size, Titanium/Polysulfone) was inserted at the end of the operation. The skin was incised transversely at the left midclavicular line on the last costal bone. Subcutaneous dissection was applied to reach up to fascia and to create a pocket for the port. A fenestrated catheter without a cuff was placed through the guide that created a tunnel tract with the width of the catheter. After passing the fascia, a guide was pushed through the preperitoneal tissue up to the point of peritoneal entry which was approximately 5 cm lateral to the incision at the umbilical line (Figure 1). Single-lumen port was sutured above the fascia with 2.0 polypropylene on two corners. 100 U/cc heparinized saline was flushed with its own needle (Huber needle). Catheter lied over the descending colon and toward to pelvis. Vaginal cuff and midline incision were closed watertight. The protocol was planned as an intravenous paclitaxel (175 mg/m², 3 hours) and intraperitoneal cisplatin (75mg/m²) on day 1 every 21 days. Hydration with saline was performed at premedication period and continued totally 24 hours with

monitorization of urine output to ensure that the urine output is at least 100 cc/hour. Initially, 1 liter of saline was infused into the abdomen without cisplatin. Then, an additional 1 liter of saline including cisplatin was infused. Flushing with heparinized saline was done after each port use.

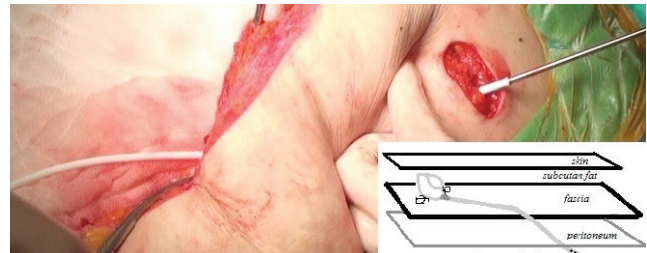


Figure 1. Insertion route of the catheter using its own guide

Case Report 1

A 52-year-old postmenopausal woman presented with abdominal distension. She had diabetes mellitus in her medical history. Bilateral 5 cm ovarian solid masses were detected on ultrasound scans. Omental cake, extensive peritoneal tumoral implants and ascites were reported on computed tomography (CT). There were no distant metastasis according to imaging studies. Among the tumor markers, only cancer antigen-125 (CA125: 6442 IU/ml) level was high. Endoscopic and colonoscopic evaluation of gastrointestinal system was normal. Eastern Cooperative Oncology Group (ECOG) [9] performance status was zero. Information about the operation procedure, probability of chemotherapy necessity and the implementation routes of chemotherapy were given preoperatively. Due to an initial diagnosis of ovarian cancer, laparotomy was performed with a vertical incision. Intraoperative inspection revealed diffuse tumor dissemination and peritoneal cancer index (PCI) [10] was 25. Result of frozen/section (F/S) was reported as ovarian serous malignant epithelial tumor. The operation was completed with type 1 hysterectomy, bilateral salpingo-oophorectomy, retroperitoneal lymph node dissection, parietal peritonectomy, total omentectomy, splenectomy, cholecystectomy and diaphragm stripping. No visible tumor (Residue®: 0) was obtained at the end of the surgery. Certain pathology reported as high grade serous carcinoma. She had stage IIIC (FIGO 2014) disease. After postoperative full recovery, the IPC was performed on postoperative day 14. Ten days after the 3rd cycle, she presented with abdominal distension and edema on bilateral legs. The imaging studies demonstrated approximately 7 cm bilateral anechoic septate cysts and dilated cecum. There was venous thrombus

on the left leg. Anticoagulation therapy was started. The distension of the abdomen worsened after 12 hours from the conservative management. Free intra-abdominal gas was detected in the imaging studies. She underwent emergency laparotomy with the suspicion of intestinal perforation. A fistula on the left part of the transverse colon, two anechoic 5 cm septate pseudo cysts, catheter as free and no any visible tumor were detected at the exploration. Formation of the fistula was at the local area. The port and the catheter were removed. Colostomy was performed at the point of the fistula on the colon. Cysts were drained. After full postoperative recovery, chemotherapy was given on day 21 of her 3rd cycle without delay. Platinum-based chemotherapy was completed to 6 cycles intravenously. After 3 months from completion of IPC, loop colostomy was closed. She is alive without disease at 13 months follow up.

Case Report 2

A 54-year-old postmenopausal woman presented with abdominal distension. No medical history was reported. Upon physical examination and imaging studies, 5 cm solid mass on the right adnexa, 3 cm solid mass in the Douglas cavity, omental cake, extensive peritoneal implants and ascites were detected. There were not extra-abdominal diseases. Among the tumor markers, only CA125 (2927 IU/ml) level was elevated. Endoscopic and colonoscopic evaluation of gastrointestinal system was normal. ECOG performance status was zero. Information about the operation procedure, probability of chemotherapy necessity and the implementation routes of chemotherapy were given preoperatively. Laparotomy was performed with a vertical incision. PCI was 14. Result of F/S was reported as an ovarian serous malignant epithelial tumor. The operation was completed with type 1 hysterectomy, bilateral salpingo-oophorectomy, retroperitoneal lymph node dissection, parietal peritonectomy, total omentectomy, splenectomy, cholecystectomy, appendectomy and diaphragm stripping. At the completion of the operation, R0 was obtained. According to postoperative pathologic report, she had stage IIIC high grade serous ovarian carcinoma. After the postoperative full recovery, the IPC was performed on postoperative day 14.

Nine weeks after beginning of chemotherapy, she presented with indefinite abdominal pain. There was only minimal vaginal discharge in physical examination. There were no abnormality in laboratory tests and ultrasonographic examination of the abdomen. Therapy for vaginitis was given. On the first day of the 4th IPC cycle,

while controlling the port and just before flushing of the heparinized saline was done, it was seen that blood was coming from the port to the injector. She had a CT scan after the injection of the water-soluble radiographic agent into the port. On the CT scan, there was no obstruction in the lumen of the catheter. However, adhesion and formation of a sheath around the catheter was seen (Figure 2). The patient underwent exploratory laparotomy. An adhesive sheath was detected along the whole length of the catheter. No visible tumor was seen at the exploration. Firm adhesion around the catheter was dissected and catheter was released. Two days later chemotherapy was given intraperitoneally. All six cycles of IPC were completed in 16 weeks. It was evaluated as a complete response according to clinical, CA125 level and imaging studies. Port and catheter were removed after one month. Seven months after completion of chemotherapy, high CA125 (226 IU/ml) level was detected. According to imaging studies, only a supraclavicular enlarged lymph node was determined. Because of the extra-abdominal recurrence, she has still been receiving second-line intravenous chemotherapy for 1 month.

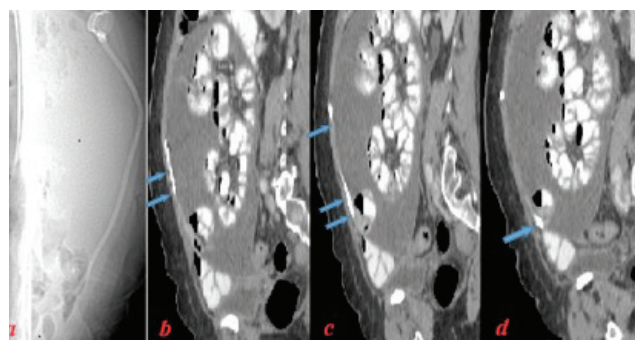


Figure 2. Abdominal Computed Tomography: Adhesive sheet around the catheter (case #2); localization of catheter (a); arrow: catheter filled with contrast; there were no spread to intra-abdominal cavity (b, c, d) and at the tip of the catheter the saccular structure was shown (d)

Discussion

Epithelial ovarian cancer is mostly disseminated peritoneally and also recurrences usually occur in the peritoneal surfaces of the abdominal cavity and visceral organs [7]. Based on the tendency of this spread pattern, IPC following at least optimal cytoreductive surgery holds promise to get a grip on the disease. Basic three large Gynecologic Oncology Group trials showed improved survival benefit in patients who were treated with IPC compared to those who received intravenous chemotherapy following optimal cytoreductive surgery [4,6,11]. Barriers for adaptation of

IPC to clinical practice are especially related to catheter use, lack of experience about the insertion techniques, devices, medications and drugs, questions associated with the insertion time [12]. All of them are interdependent factors.

One of the most common complications of IPC is catheter-related complications [13,14]. The rates of catheter-related complication were 6.8–40.5% [13,14]. A study showed that the catheter-related complication was high (with a mean rate of approximately 13%), because it shouldered majority of responsibility about failure of the intraperitoneal therapy completion [15]. Catheter-related complications can be sorted as access problems, dislocation of the port, obstruction, retraction, leakage, pain around the port pocket, abdominal discomfort, infection and bowel perforation. Focusing on the solutions of these factors, may improve both the clinical practice rates and chance of completing the chemotherapy intraperitoneally.

The devices of infusion changed in time. In the earlier periods, catheters developed for peritoneal dialysis were used for intraperitoneal therapy [16]. Nowadays, fully implanted peritoneal access devices were developed [17]. Important features of these devices are as follows: fenestrated or unfenestrated, single lumen or double lumen, titanium or plastic and presence or absence of cuff. There are few studies which determines the ideal features of catheters. Multiple fenestration catheters can help better distribution, yet it is asserted that they are prone to obstruction or bowel adhesions [12, 15]. In spite of that, Black et al., reported that using fenestrated catheters were related with lower risk catheter-related complications, even if bowel resection was present [18]. Catheter with cuff(s) tend to erode the fascia, to migrate into the peritoneal cavity and to be associated with bowel erosion [19]. We used fenestrated catheters with cuffs for our patients. One of the patients had bowel perforation which was managed by removing the port and creating colostomy.

One of the most common catheter-related complications is blockage of the catheter that causes obstruction in infusion [18,20]. One of our patients had catheter blockage that was managed by releasing the catheter from the fibrous adhesions. The rate of obstruction ranged from 2.1% to 22% [15]. The reasons of blockage are adhesion formation around the catheter, kinking or fibrin in the lumen. There is no clear evidence about the leading cause of the blockage. But some reports blamed fenestrated catheters as the formation of adhesive fibrous sheath was easier around these catheters [12, 15]. In spite of that, Ivy et al., found that there was

no significant difference about complications between fenestrated or unfenestrated catheters [21]. Also, Lesnock et al., reported that there was no indication about the superiority of unfenestrated catheters [13]. The underlying reason about the kinking can be passing the fascia and the peritoneum at the same point perpendicularly. This can be avoided by paying attention to pass the fascia horizontally and to push the guide through the preperitoneal tissue up to the point of peritoneal entry that is 5-6 cm lateral to the incision at the umbilical line.

The risk of bowel perforation was low and rates were reported up to 3.6% for patients who received IPC with fully implanted peritoneal port [22,23]. The bowel perforations can occur at the time of placement, during or soon after the therapy and at the time of port removal [15,22]. One of our patients had bowel perforation during the therapy which was managed by removing the port and creating colostomy. Sakuragi et al., incidentally detected a catheter-related perforation in the small intestine in one patient at surgery because of abdominal wall hernia which was performed 36 months after implantation of a catheter [24]. Emoto et al., reported a patient with a watery diarrhea after IP injection and CT showed that a bowel fistula was located between the catheter and the rectum [20]. Davidson et al. found bowel perforation with a rate of 3.5% that occurred during the treatment in six patients and incidentally in two who underwent second look surgery following completion of chemotherapy [23]. Placement of the port under visualization is recommended to decrease the risk of bowel perforation. The recommendations about the removing time are after the last cycle of IPC or within 1 year of the treatment to avoid future complications such as bowel injury or infections [12,24].

Infection rates ranged from 0% to 20.5 % [24,25]. The majority of those were local infections [15, 24, 26]. The underlying factors for infections are not clear. Using catheters with cuff(s) could lead to infection because of its erosive effect to bowel [19]. Davidson et al., found that catheter-related complication rates (4.3%-16%) including infection were increased when the gastrointestinal procedures were performed, but this was not statistically significant [24]. Landrum et al., asserted that while placement of port was avoided at the time of bowel resection, the rate of infection decreased from 17.6% to 10.8% [22]. Although, delaying the insertion of a port to the postoperative period in patients who underwent bowel surgery was recommended, there was no certain contraindication about placement of a port during

bowel resection [12,15,22,23,27]. Black et al., reported that there were no differences in complication rates and completion rate of IPC in patients with or without bowel surgery [18]. Also, Emoto et al., found that none of the patients whose intraperitoneal port inserted concurrently with gastrointestinal surgery had infection [20].

Port dislocation and catheter retraction could be encountered in several cases (1%) [15]. This situation was suspected at the presence of pain or mass on the area of port pocket, challenge at the access of the needle or infusion, swelling at the port pocket during the infusion. The recommendations to avoid port dislocation and catheter retraction are as follows; (i) paying attention to the insertion of the port overlying fascia on the costa with non-absorbable sutures and to the length of catheter within peritoneal cavity (at least 12 cm), (ii) avoiding from redundant dissection in pocket of port (iii) consideration of the additional sutures around the catheter at the point of peritoneal entry [12,15,28]. The rates of leakage related with the device ranged from 1.3% to 11.9% [14,29]. The precautions are using the catheter's own guide with a width close to the catheter size, paying attention to the full connection at the point of the port-catheter and paying attention if the needle is at the correct area of the port [12,15].

Intraperitoneal chemotherapy following optimal cytoreductive surgery in epithelial serous ovarian cancer holds promise to improve survival. One of the catheter-related complications is blockage of the catheter. In this study, we presented two catheter-related complications. One of the patients had blockage of the catheter and the other had a bowel perforation. Both patients were treated successfully and chemotherapy was not terminated by complications. Awareness about the complications is important in order to decrease the rates of complications, to solve the problems earlier and easier, to increase the completion rates of chemotherapy intraperitoneally and to increase the adaptation of IPC to clinical practice. Catheter-related complications, one of the major barriers in the adaptation of IPC into clinical practice can be managed without having any delay in the therapy of IPC patients.

Conflict of interest statement

The authors declare no competing interest. This research did not receive any specific grant from funding agencies in the public, commercial, or not-for-profit sectors.

References

1. Brown PO, Palmer C. The preclinical natural history of serous ovarian cancer: defining the target for early detection. *PLoS Med* 2009; 6:e1000114. doi: 10.1371/journal.pmed.1000114.
2. Ferlay J, Soerjomataram I, Dikshit R, et al. Cancer incidence and mortality worldwide: sources, methods and major patterns in GLOBOCAN 2012. *Int J Cancer* 2015; 136:359-86. doi: 10.1002/ijc.29210.
3. Landrum LM, Java J, Mathews CA, et al. Prognostic factors for stage III epithelial ovarian cancer treated with intraperitoneal chemotherapy: a Gynecologic Oncology Group study. *Gynecol Oncol* 2013; 130:12-8. doi: 10.1016/j.ygyno.2013.04.001.
4. Armstrong DK, Bundy B, Wenzel L, et al. Intraperitoneal cisplatin and paclitaxel in ovarian cancer. *N Engl J Med* 2006; 354(1):34-43. doi: 10.1056/NEJMoa052985.
5. Tewari D, Java JJ, Salani R, et al. Long-term survival advantage and prognostic factors associated with intraperitoneal chemotherapy treatment in advanced ovarian cancer: a gynecologic oncology group study. *J Clin Oncol* 2015; 33:1460-6. doi: 10.1200/jco.2014.55.9898.
6. Markman M, Bundy BN, Alberts DS, et al. Phase III trial of standard-dose intravenous cisplatin plus paclitaxel versus moderately high-dose carboplatin followed by intravenous paclitaxel and intraperitoneal cisplatin in small-volume stage III ovarian carcinoma: an intergroup study of the Gynecologic Oncology Group, Southwestern Oncology Group, and Eastern Cooperative Oncology Group. *J Clin Oncol* 2001; 19:1001-7. doi: 10.1200/jco.2001.19.4.1001.
7. Fujiwara K, Armstrong D, Morgan M, Markman M. Principles and practice of intraperitoneal chemotherapy for ovarian cancer. *Int J Gynecol Cancer* 2007; 17:1-20. doi: 10.1111/j.1525-1438.2007.00809.x.
8. National Cancer Institute. NCI clinical announcement in 2006: intraperitoneal chemotherapy for ovarian cancer Available from: [http://ctepcancer.gov/highlights/docs/clin_annnc_010506pdf]; Accessed 30/11/2017.
9. Oken MM, Creech RH, Tormey DC, et al. Toxicity and response criteria of the Eastern Cooperative Oncology Group. *American Journal of Clinical Oncology* 1982; 5:649-56.
10. Jacquet P, Sugarbaker PH. Clinical research methodologies in diagnosis and staging of patients with peritoneal carcinomatosis. *Cancer Treat Res* 1996; 82:359-74.
11. Alberts DS, Liu PY, Hannigan EV, et al. Intraperitoneal cisplatin plus intravenous cyclophosphamide versus intravenous cisplatin plus intravenous cyclophosphamide for stage III ovarian cancer. *N Engl J Med* 1996; 335:1950-5. doi: 10.1056/nejm199612263352603.
12. Markman M, Walker JL. Intraperitoneal chemotherapy of ovarian cancer: a review, with a focus on practical aspects of treatment. *J Clin Oncol* 2006; 24:988-94. doi: 10.1200/jco.2005.05.2456.
13. Lesnock JL, Richard SD, Zorn KK, et al. Completion of intraperitoneal chemotherapy in advanced ovarian cancer and catheter-related complications. *Gynecol Oncol* 2010; 116:345-50. doi: 10.1016/j.ygyno.2009.11.009.

14. Berry E, Matthews KS, Singh DK, et al. An outpatient intraperitoneal chemotherapy regimen for advanced ovarian cancer. *Gynecol Oncol* 2009; 113:63-7. doi: 10.1016/j.ygyno.2008.12.035.
15. Helm CW. Ports and complications for intraperitoneal chemotherapy delivery. *BJOG* 2012; 119:150-9. doi: 10.1111/j.1471-0528.2011.03179.x.
16. Speyer JL, Myers CE. The use of peritoneal dialysis for delivery of chemotherapy to intraperitoneal malignancies. *Recent Results Cancer Res* 1980; 74:264-9.
17. Pfeifle CE, Howell SB, Markman M, Lucas WE. Totally implantable system for peritoneal access. *J Clin Oncol* 1984; 2:1277-80. doi: 10.1200/jco.1984.2.11.1277.
18. Black D, Levine DA, Nicoll L, et al. Low risk of complications associated with the fenestrated peritoneal catheter used for intraperitoneal chemotherapy in ovarian cancer. *Gynecol Oncol* 2008; 109:39-42. doi: 10.1016/j.ygyno.2007.12.004.
19. Varney RR, Goel R, vanSonnenberg E, Lucas WE, Casola G. Delayed erosion of intraperitoneal chemotherapy catheters into the bowel. Report of two cases. *Cancer* 1989; 64:762-4.
20. Emoto S, Ishigami H, Hidemura A, et al. Complications and management of an implanted intraperitoneal access port system for intraperitoneal chemotherapy for gastric cancer with peritoneal metastasis. *Jpn J Clin Oncol* 2012; 42:1013-9. doi: 10.1093/jjco/hys129.
21. Ivy JJ, Geller M, Pierson SM, Jonson AL, Argenta PA. Outcomes associated with different intraperitoneal chemotherapy delivery systems in advanced ovarian carcinoma: a single institution's experience. *Gynecol Oncol* 2009; 114:420-3. doi: 10.1016/j.ygyno.2009.05.036.
22. Landrum LM, Gold MA, Moore KN, Myers TK, McMeekin DS, Walker JL. Intraperitoneal chemotherapy for patients with advanced epithelial ovarian cancer: a review of complications and completion rates. *Gynecol Oncol* 2008; 108:342-7. doi: 10.1016/j.ygyno.2007.10.004.
23. Davidson SA, Rubin SC, Markman M, et al. Intraperitoneal chemotherapy: analysis of complications with an implanted subcutaneous port and catheter system. *Gynecol Oncol* 1991; 41:101-6.
24. Sakuragi N, Nakajima A, Nomura E, et al. Complications relating to intraperitoneal administration of cisplatin or carboplatin for ovarian carcinoma. *Gynecol Oncol* 2000; 79:420-3. doi: 10.1006/gyno.2000.5979.
25. Nanninga AG, Willemse PH, Boonstra H, De Vries EG. Low complication rate during intraperitoneal therapy through a totally implanted peritoneal access port in patients with ovarian cancer. *Int J Gynecol Cancer* 1992; 2:107-10.
26. Topuz E, Salihoglu Y, Aydiner A, et al. Celsite port and catheter as an intraperitoneal access device in the treatment of ovarian cancer. *J Surg Oncol* 2000; 74:223-6.
27. Walker JL, Armstrong DK, Huang HQ, et al. Intraperitoneal catheter outcomes in a phase III trial of intravenous versus intraperitoneal chemotherapy in optimal stage III ovarian and primary peritoneal cancer: a Gynecologic Oncology Group Study. *Gynecol Oncol* 2006; 100:27-32. doi: 10.1016/j.ygyno.2005.11.013.
28. Pendergrass M, Gordinier ME, Parker LP, Metzinger DS, Helm CW. Retraction of an intraperitoneal chemotherapy port: a case report and literature review. *Int J Gynecol Cancer* 2007; 17:1131-3. doi: 10.1111/j.1525-1438.2007.00910.x.
29. Piccart MJ, Speyer JL, Markman M, et al. Intraperitoneal chemotherapy: technical experience at five institutions. *Semin Oncol* 1985; 12(3 Suppl 4):90-6.