

## Use of a Vessel Sealing System (LigaSure Impact™) In The Sealing and Division of The Intestine

Damar Mühürleme Sisteminin (LigaSure Impact™) Bağırsak Kapamada Kullanımı  
Nurullah Damburacı, Murat Güner, Barış Sevinç, Ömer Karahan

Uşak Üniversitesi Tıp Fakültesi, Genel Cerrahi Anabilim Dalı, Uşak, Türkiye

### ÖZET

**AMAÇ:** Çalışmanın amacı LigaSure Impact™ (LigaSure LF 4200) cihazının bağırsak kapama ve mühürlemedeki etkinliğini değerlendirmektir.

**GEREÇ VE YÖNTEM:** çalışmaya beş rektum kanseri, iki sağ kolon kanseri ve sol kolon kanseri, pankreas kanseri ve ileostomili birer hasta dahil edilmiştir. LigaSure Impact™ (LigaSure LF 4200) cihazı duodenum, jejunum, ileum, transvers ve sigmoid kolonun kesilmesinde lineer kesici stapler gibi kullanılmıştır.

**BULGULAR:** hastaların yaşları 20-85 arasındadır. Cihaz kullanılarak toplam 20 bağırsak kesme işlemi gerçekleştirilmiştir. Mühürleme aşamasında hiç bir vakada başarısızlıkla karşılaşmamıştır.

**SONUÇ:** Oldukça sınırlı bir çalışma popülasyonu olmasına rağmen çalışmamızın sonuçlarına dayanarak cihazın bağırsak kesme ve mühürlemede başarıyla kullanılabileceği gösterilmiştir. Bağırsak için daha uygun cihazların geliştirilmesiyle birlikte kullanımı daha da yaygınlaştırılabilir.

**Anahtar Kelimeler:** LigaSure, ince bağırsak, kolon, mühürleme

### ABSTRACT

**OBJECTIVE:** To evaluate the efficiency of the LigaSure Impact™ (LigaSure LF 4200) device in the sealing and division of the intestine.

**MATERIAL AND METHODS:** The study included 13 patients (9 male, 4 female). The diagnosis was rectal cancer in 5 cases, gastric cancer in 3, right colon cancer in 2, left colon cancer in 1, and pancreatic cancer in 1; 1 case had ileostomy. The LigaSure Impact™ (LigaSure LF 4200) device was used as a linear cutting stapler in the resection of the duodenum, jejunum, ileum, and transverse and sigmoid colon.

**RESULTS:** Ages of the patients ranged between 20-85 years. A total of 20 cutting procedures were performed with LigaSure (3 at duodenal, 4 at jejunal, 4 at ileal and 9 at the colonic level). There was no failure or complication in the sealing process. Division of the bowel with LigaSure is easy and safe for making a clean intestinal edge during the operation. Complications included urethral injury in 1 case during the operation and wound infection in the perineal region in 1 case; neither complication was related with thermal energy.

**CONCLUSION:** This issue needs further investigation. Our population was very small and there was no control group. However, our results showed that LigaSure can be used safely in the division and sealing of the intestine as a linear cutting stapler. The development of special devices for the intestine will make this process easier and contribute to its more frequent use.

**Keywords:** LigaSure, small bowel, colon, cutting, sealing.

### INTRODUCTION

The vessel sealing system LigaSure Impact™ is commonly and successfully used for hemostasis and the sealing of arteries smaller than 7 mm in different fields of surgery. The clinical use of LigaSure in open and laparoscopic procedures like hemorrhoid, thyroid and trauma surgery, splenectomy, and appendectomy has been reported as

highly successful (1-5). There have been some experimental studies about the use of the device in intestinal anastomosis (6). The LigaSure device is routinely used in our clinic in thyroidal and open/laparoscopic gastrointestinal procedures for hemostasis. We use LigaSure to seal the vessels of the omentum and intestinal mesentery and to divide them in open/laparoscopic gastric

and intestinal surgeries. In this study, we used the device for the division and sealing of the intestine and evaluated the results.

#### MATERIAL AND METHOD

Permission for the study was obtained from the local ethical committee of Selçuk University, Meram Medical Faculty.

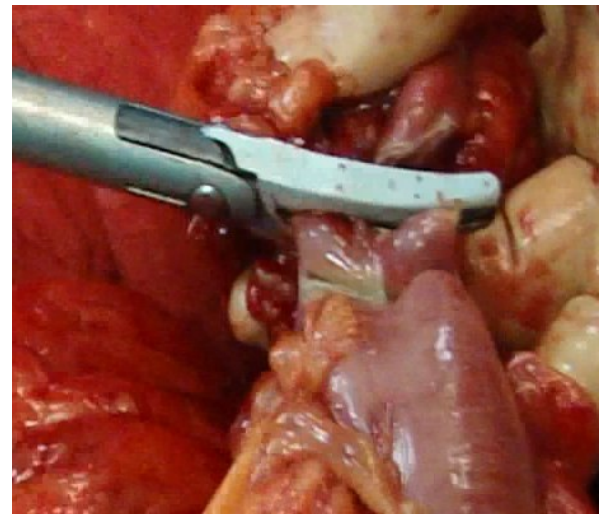
Thirteen patients (9 male, 4 female) were included. The diagnosis was rectal cancer in 5, gastric cancer in 3, right colon cancer in 2, left colon cancer in 1, and pancreatic cancer in 1 case; 1 case had ileostomy. The patients were aged between 20-85 years. After preparation of the bowel or stomach, we used ForceTriad™ (Valleylab, Boulder, Colorado, USA) energy platform and LigaSure Impact™ (LigaSure LF 4200). LigaSure Impact™ has both sealing and cutting functions. Its sealing width and length are 3.3-4.7 mm and 36 mm, respectively, and cutting length is 34 mm; the shaft length is 18 cm and shaft diameter is 13.7 mm (7). We used its sealing and cutting functions as a linear cutting stapler. When its sealing function was not adequate, it was used as a facilitator and supporting method.

In 3 open and 2 laparoscopic abdominoperineal resections due to rectal cancer, we divided the part of the sigmoid colon that would be resected using LigaSure as a linear cutting stapler (Fig. 1). In 2 laparoscopic operations, we removed the 12 mm trochar and inserted the LigaSure Impact™ into the same incision (Figs. 2, 3). In abdominoperineal resections, different from the other procedures, we sealed the distal bowel twice to prevent fecal leakage into the abdominal cavity (Fig. 4). The distal bowel was emptied by a rectal tube transanally and resected from the perineal region. The proximal sealed bowel was removed from the abdomen, the sealed edges were cut, and then end colostomy was done.

Of the 3 cases with gastric cancer, 2 underwent total gastrectomy and 1 subtotal gastrectomy. In those cases, the duodenum and the jejunal loop that would be used for anastomosis were cut using LigaSure (Figs. 5, 6). Three duodenal stumps and two jejunal edges that would be used for anastomosis were closed by 3/0 silk sutures in 1 layer (Fig. 7). In 1 of the 2 cases with total gastrectomy, the closed jejunal edge was resected, and end-to-end esophagojejunostomy was performed. In the other case

with total gastrectomy, end-to-side esophagojejunostomy was done. In the case with subtotal gastrectomy, side-to-side gastrojejunostomy was made. Intestinal continuity was achieved with jejunojejunostomy (Roux-en-Y). During the process of jejunojejunostomy, the sealed edge of the jejunum was resected.

In the 2 cases with right colon cancer, the proximal ileum and distal colonic segment were cut using LigaSure. In the case with left hemicolectomy, the transverse and sigmoid colon were also cut with LigaSure. The case with pancreatic cancer was inoperable due to a large and fixated tumor. Roux-en-Y choledochojejunostomy was made to maintain bile drainage. The jejunum prepared for anastomosis was cut with LigaSure. We closed the ileostomy of the patient who underwent total proctocolectomy, ileoanal pouch and loop ileostomy due to ulcerative colitis. In this case, the peroperatively traumatized ileal edges were cut using LigaSure. During the anastomosis, the edges sealed by LigaSure were resected. Information about the patients is given in Table 1.



**Figure 1:** Sealing of the colon with LigaSure.

#### RESULTS

We performed 20 cuttings, 5 closures, 12 anastomoses, and 5 colostomies in 13 cases. All the procedures were completed successfully. There was no difficulty in the division of the duodenum, jejunum, ileum or colon. As with a linear stapler, the division was not fully completed in some cases. In such conditions, the connections at the edges were re-cut using LigaSure. Peroperatively, contamination of the abdominal cavity with feces was easily prevented. The embedding of the duodenal and jejunal

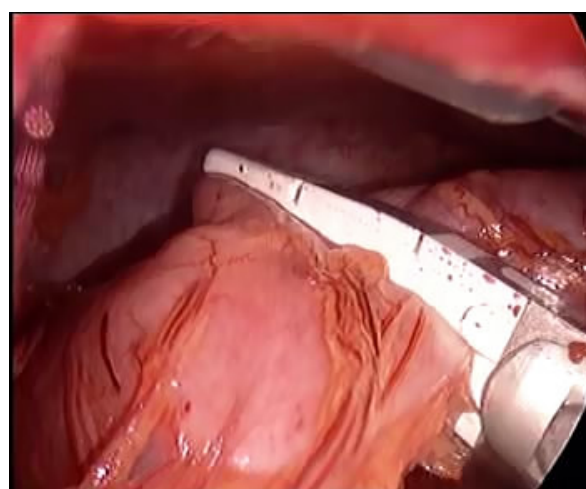
stumps was easier, and there was no need for two-layer suturing technique since the stumps were closed in one layer.

**Table 1.** Procedures performed in the study subjects

Dx	A/S	Operation	Div.	Clos.	A	C
Rectal cancer	62/M	Miles operation	SC	-	-	SEC
Rectal cancer	78/M	Miles operation	SC	-	-	SEC
Rectal cancer	77/M	Miles operation	SC	-	-	SEC
Rectal cancer	42/F	Laparoscopic Miles operation	SC	-	-	SEC
Rectal cancer	51/M	Laparoscopic Miles operation	SC	-	-	SEC
Gastric cancer	71/M	Subtotal gastrectomy	-	D+J	GJ+JJ	-
Gastric cancer	55/M	Total gastrectomy	-	D+J	EJ+JJ	-
Gastric cancer	55/M	Total gastrectomy	-	D	EJ+JJ	-
Colon cancer	81/F	Right hemicolectomy	I+TC	-	IC	-
Colon cancer	85/F	Right hemicolectomy	I+TC	-	IC	-
Colon cancer	59/M	Left hemicolectomy	TC+SC	-	CC	-
Ileostomy	20/F	Ileostomy closure and wound site infection	I+I	-	II	-
Pancreatic cancer	64/M	Roux-en-Y choledochojejunostomy	J	-	CJ+JJ	-
<b>Total</b>			20	5	12	5

Div.: Division, Clos.: Closure, A: Anastomosis, C: colostomy, D: Duodenum, J: Jejunum, I: Ileum, TC: Transverse colon, SC: Sigmoid colon, EJ: esophagojejunostomy, GJ: Gastrojejunostomy, JJ: Jejunojejunostomy, II: Ileoileostomy, IC: Ileocolostomy, SEC: Sigmoid end colostomy, CC: Colocolonic anastomosis, CJ: choledochojejunostomy

The edges for anastomosis or colostomy were transferred to the anastomosis or colostomy site without any contamination risk. In cases with abdominoperineal resection, the distal part of the bowel was resected without any fecal contamination from the sealed part. Perioperatively and postoperatively, there were no complications due to bowel sealing. In one case, the posterior urethra was injured during dissection of the tumor passing through the rectal wall. It was repaired through a urinary catheter. Perineal wound infection was also noted in one case. However, these two complications were not related to LigaSure use.



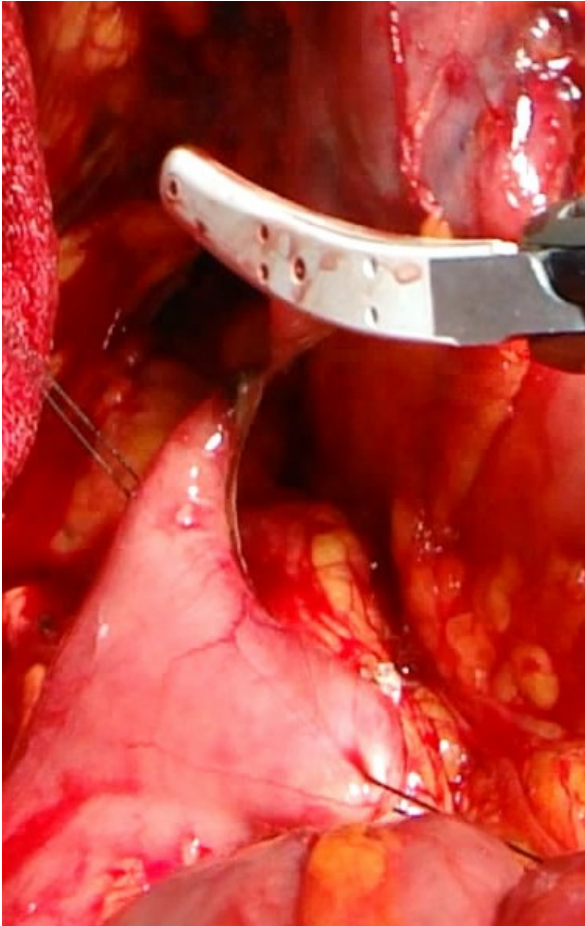
**Figure 2:** Laparoscopic sealing of the colon with LigaSure

## DISCUSSION

LigaSure is an electrothermal vessel sealer. It is an alternative to suture, hemoclip, stapler, and ultrasonic coagulator. The device can seal vessels, including arteries up to 7 mm. It has a different energy system from monopolar and bipolar electrocautery. LigaSure causes less heat damage to the tissue than UltraCision. The energy denatures the elastin and collagen in the vessel wall and seals the vessel (3, 8).

LigaSure is used in different fields of surgery (9). It is superior to closed hemorrhoidectomy with its feature of shortening the operation time without increasing the complication rate (1). It reduces blood loss and fluid accumulation in thyroid surgery (2). In laparoscopic splenectomy, LigaSure simplifies the procedure, provides sufficient hemostasis and shortens the operation time (4).

In children, compared to monopolar electrocautery, it is safe and effective in the dissection of the mesentery of the appendix vermiformis, is effective in hemostasis and shortens the operation time (5). In trauma surgery, it is effective in hemostasis and bowel resection (3).



**Figure. 3:** Sealing and division of the duodenum with LigaSure.

The safety and efficiency of LigaSure have also been reported in liver resection for transection of normal parenchyma (10), laparoscopic nonanatomic hepatectomy (11) and laparoscopic resection of adrenal and nonadrenal tumors (12, 13). The vessel sealing system reduces the operation time in laparoscopic colectomy (14). Aside from general surgery, LigaSure is also used in thoracal surgery, gynecology and urology (15-17).

It has been shown in experimental studies that LigaSure can be used as an alternative in appendiceal stump closure (18) and in the sealing of a porcine pancreatic stump in distal pancreatectomy (19). After demonstration of the sealing of the cystic artery and duct with LigaSure in experimental studies (20, 21), it was also shown that the

cystic duct can be safely sealed using LigaSure during laparoscopic cholecystectomy in children (22). The procedures involving the pancreas, appendix and cystic duct represent different uses of LigaSure other than with vessels. Furthermore, the studies performed in canine lung and porcine bowel were found to be successful. All these results show that LigaSure can be used safely in tissues consisting of collagen and elastin (23). Based on that information, a prototype of the LigaSure anastomotic device (LAD) with a reconstructive function in addition to its dissection, cutting and hemostasis functions was developed. The studies of porcine bowel anastomosis made using the LAD were successful. The ideal laparoscopic equipment needs to have dissection and reconstruction functions with no requirement of reinstallation. In the future, a LAD possessing those functions will facilitate the surgeons' work (6).

There have been other studies about the use of LigaSure in the bowel. Salameh et al. (24) compared the burst pressure of porcine bowel anastomosis using LigaSure versus stapler. The burst pressure of the anastomosis made with LigaSure was significantly lower when compared to the stapler. That study assessed the efficiency of LigaSure in bowel anastomosis and reported it to be insufficient. In our study, we thought as LigaSure wasn't sufficient and one layer of silk sutures was used.

In another study, LigaSure was used in the division of the terminal ileum. In that study, the terminal ileum was sealed and divided using the LigaSure Atlas device during the process of right hemicolectomy. The end-to-side ileotransversostomy was made with stapler. There were no problems related to the procedure. The procedure was reported as easy, safe and inexpensive for laparoscopic right hemicolectomy (25). In our study, LigaSure Impact™ (LigaSure LF 4200) was used in the division of different bowel segments. This device can be used as a linear stapler. During the process of anastomosis, the sealed edges of the intestine were resected and classical anastomosis was done. The division of the bowel with LigaSure was the main procedure in both studies, and both were successful.

The LigaSure device may not be suitable or adequate for anastomosis or closure of the bowel in humans. However, our study showed the LigaSure can be used in the sealing and division of the bowel. This study reports the

preliminary results of the procedure, but further studies are needed before drawing a definitive conclusion. However, our data show that the use of LigaSure as a cutting stapler simplifies the operation and prevents contamination of the abdominal cavity with intestinal content. In addition, use of LigaSure for division of the colon in laparoscopic abdominoperineal resection reduces the need for stapler and thus reduces the cost. LigaSure Impact™ was developed for use in open surgical procedures. In laparoscopic abdominoperineal resection, LigaSure Impact was inserted in the abdomen via the 12 mm trocar incision and was used for division of the previously dissected sigmoid colon.

We did not evaluate the LigaSure regarding its effectiveness in stump closure and used it only

as the first step of closure. LigaSure was used to facilitate closure of the duodenum and jejunum. Using this procedure, the intestine was easily and safely closed with the one-layer technique.

The LigaSure device is routinely used in the division of the omentum, mesentery and mesenteric vessels and now can also be used in the sealing and division of the bowel. Advantages of the procedure include no need for reinstallation or changing of the device. The utilization of the device, which was previously used for hemostasis, for bowel sealing and division without any additional expense presents an important cost advantage. The development of new devices specific to the bowel or perhaps to solid organs would contribute to the much greater utilization of the LigaSure device.

LigaSure can be used in the division of the bowel as a cutting stapler. The stump divided using LigaSure can be closed safely in one layer. The development of devices specific for the bowel would further increase its use. More studies are needed to evaluate this issue before drawing definitive conclusions.

#### AUTHOR DISCLOSURES

Authors in this study have no conflict of interest or financial ties to disclose

#### REFERENCES

1. Pattana-arun J, Sooriprasoet N, Sahakijrungruang C,

Tantiphachiva K, Rojanasakul A. Closed vs ligasure hemorrhoidectomy: a prospective, randomized clinical trial. *J Med Assoc Thai* 2006; 89: 453-458.

2. Dilek ON, Yilmaz S, Degirmenci B, Sahin DA, Akbulut G, Dilek FH. The use of a vessel sealing system in thyroid surgery. *Acta Chir Belg* 2005; 105: 369-372.

3. Hope WW, Burns JM, Newcomb WL, Heniford BT, Sing RF. Safety and efficacy of the electrothermal bipolar vessel sealer in trauma injury. *Injury*. 2009; 40: 564-566. Barbaros U, Dincçag A, Deveci U, Akyuz M, Tükenmez M, Erbil Y, Mercan S. Use of electrothermal vessel sealing with LigaSure™ device during laparoscopic splenectomy. *Acta Chir Belg* 2007; 107: 162-165.

4. Şenel E, Akbıyık F, Atayurt HF, Tiryaki HT. Dissection of mesoappendix in laparoscopic appendectomy: a comparison of monopolar cautery and bipolar vessel sealing system. *Turk J Med Sci* 2010; 40: 757-760.

5. Smulders JF, de Hingh I, Stavast J, Jackimowicz JJ. Exploring new technologies to facilitate laparoscopic surgery: creating intestinal anastomosis without sutures or staples using a radiofrequency-energy-driven bipolar fusion device. *Surg Endosc* 2007; 21: 2105-2109.

6. <http://www.ligasure.com/ligasure/pages.aspx?page=Products/Open/160291> signing date 31.03.2011.

7. Diamantis T, Kontos M, Arvelakis A, Syroukis S, Koronarchis D, Papalois A, Agapitos E, Bastounis E, Lazaris A C. Comparison of monopolar electrocoagulation, bipolar electrocoagulation, Ultracision, and Ligasure. *Surg Today* 2006; 36: 908-913.

8. Riegler M, Cosentini E. Update on LigaSure ©/Atlas© vessel sealing technology in general surgery. *Eur Surg* 2004; 36: 85-88.

9. Romano F, Garancini M, Caprotti R, Bovo G, Conti M, Perego E, Uggeri F. Hepatic resection using a bipolar vessel sealing device: technical and histological analysis. *HPB (Oxford)* 2007; 9: 339-344.

10. Constant DL, Slakey DP, Campeau RJ, Dunne JB. Laparoscopic nonanatomic hepatic resection employing the LigaSure device. *JLS* 2005; 9: 35-38.

11. Misra MC, Aggarwal S, Guleria S, Seenu V, Bhalla AP. Clipless and sutureless laparoscopic surgery for adrenal and extra-adrenal tumors. *JLS* 2008; 12: 252-255.

12. Yavuz N. Laparoscopic transperitoneal adrenalectomy using the LigaSure vessel sealing system. *J Laparoendosc Adv Surg Tech A*. 2005; 15: 591-595.

13. Takada M, Ichihara T, Kuroda Y. Comparative study of electrothermal bipolar vessel sealer and ultrasonic coagulating shears in laparoscopic colectomy. *Surg Endosc* 2005; 19: 226-228.

14. Santini M, Vicidomini G, Baldi A, Gallo G, Laperuta P, Busiello L, Di Marino MP, Pastore V. Use of an electrothermal bipolar tissue sealing system in lung surgery. *Eur J Cardiothorac Surg* 2006; 29: 226-230.

15. Hagen B, Eriksson N, Sundset M. Randomised controlled trial of LigaSure™ versus conventional suture ligation for abdominal hysterectomy. *BJOG* 2005; 112: 968-970.

- 16.** Daskalopoulos G, Karyotis I, Heretis I, Delakas D. Electrothermal bipolar coagulation for radical prostatectomies and cystectomies: a preliminary case-controlled study. *Int Urol Nephrol* 2004; 36: 181-185.
- 17.** Elemen L, Yazir Y, Tugay M, Akay A, Aydin S, Yanar K, Ceylan S. LigaSure™ compared with ligatures and endoclips in experimental appendectomy: how safe is it? *Pediatr Surg Int* 2010; 26: 539-545.
- 18.** Hartwig W, Duckheim M, Strobel O, Dovzhanskiy D, Bergmann F, Hackert T, Büchler M W, Werner J. LigaSure for pancreatic sealing during distal pancreatectomy. *World J Surg* 2010; 34: 1066-1070.
- 19.** Schulze S, Kristiansen VB, Hansen BF, Rosenberg J. Sealing of cystic duct with bipolar electrocoagulation. *Surg Endosc* 2002; 16: 342-344.
- 20.** Shamiyeh A, Schrenk P, Tulipan L, Vattay P, Bogner S, Wayand W. A new bipolar feedback controlled sealing system for closure of the cystic duct and artery. *Surg Endosc* 2002; 16: 812-813.
- 21.** Tural S, Engel V, Sultan T. Closure of the cystic duct during laparoscopic cholecystectomy in children using the LigaSure vessel sealing system. *World J Surg* 2011; 35: 212-216.
- 22.** Shields CE, Schechter DA, Tezla P, Baily AL, Dycus S, Cosgriff N. Method for creating ideal tissue fusion in soft-tissue structures using radio frequency energy (RF). *Surg Technol Int* 2004; 13: 49-55.
- 23.** Salameh JR, Schwartz JH, Hildebrandt DA. Can LigaSure seal and divide the small bowel? *Am J Surg.* 2006; 191: 791-793.
- 24.** Moreno-Sanz C, Picazo-Yeste J, Seoane-González J, Manzanera-Díaz M, Tadeo-Ruiz G. Division of the small bowel with the LigaSure Atlas device during the right laparoscopic colectomy. *J Laparoendosc Adv Surg Tech A.* 2008; 18: 99-101..