

Case Report

Mixed type adrenal cyst: A case report

Gulay Bulut^{a,*}, Mehmet Deniz Bulut^b, Deniz Yilmaz^a, Sebahattin Celik^c, Nursen Toprak^b

^aDepartment of Pathology, Yuzuncu Yil University Faculty of Medicine, Van, Turkey

^bDepartment of Radiology, Van Research and Training Hospital, Van, Turkey

^cDepartment of General Surgery, Van Research and Training Hospital, Van, Turkey

Abstract. Adrenal cysts are rare lesions that usually progress asymptotically. They are often determined post-mortem. Our case was a 50-year old-male who had presented to our clinic with upper right quadrant pain. The computed tomography demonstrated a cystic mass in the adrenal gland. No abnormalities were determined in the laboratory tests. According to the histopathological and immunohistochemical examination, the cyst was evaluated as a mixed-type adrenal cyst, the wall of which was covered with endothelium, mesothelium and cubic epithelium. We believed that the case was worth presenting, since it was the first diagnosed mixed-type adrenal cyst in the literature.

Key words: Mixed-type adrenal cyst, endothelial cyst, epithelial cyst, mesothelial cyst

1. Introduction

Adrenal cysts are rarely encountered clinical entities. Their incidence has been reported from 0.06%-0.18% in autopsy series (1). In 1966, Foster put forth a classification based on the histopathology of 220 adrenal cysts into parasitic cysts (7%), epithelial cysts (9%), pseudocysts (39%) and endothelial cysts (45%). Evidence suggests that pseudocysts and endothelial cysts are variants of vascular cysts and account for 84% of adrenal cysts (2). Adrenal cysts are more common in women and present clinically as abdominal pain or as incidental finding (3).

2. Case report

An 50-year-old male was admitted to our hospital with complaints of pain in the abdomen of one-month duration. General physical examination presented as nonspecific abdominal

pain. There was no history of hypertension or trauma in the past. Per abdominal examination showed a soft abdomen; no mass was felt. Haemogram was normal. A complete endocrine workup including the estimation of urinary metanephrines, vanillylmandelic acid and free cortisol did not show any hormonal hypersecretion. A computed tomography and magnetic resonance imaging demonstrated the presence of a right adrenal cystic mass with a maximum diameter of 5 cm in the hepatorenal region (Figure 1a-d).

Right adrenalectomy was therefore performed by an open surgery, during which no invasion to the surrounding tissues was identified. The resected tumor measured 5 cm in diameter. The core was mostly composed of gelatinous fluid, randomly compartmentalized by fibrous tissue. The surface consisted of fibrous capsule, flanked with an atrophic normal adrenal cortex. Histological examination of the surgical specimen revealed that the cyst wall was lined by cuboidal to flattened cells with bland cytologic features. Normal adrenal gland was forming part of its wall (Figure 2). Immunohistochemically, the cyst lining expressed intensely cytokeratin, CD 34 and calretinin (Figure 3-5). These cells were completely negative for D2-40. The final pathological diagnosis was benign mix type adrenal cyst.

*Corresponding Author: Assistant Professor Gulay Bulut, MD

Yuzuncu Yil University, Medical Faculty,
Department of Pathology, 65000, Van, Turkey

Tel: +90-(432)-215 0473

Fax: +90-(432)-216 7519

E-mail: drgulaybulut@yahoo.com

Received: 12.05.2014

Accepted: 08.08.2014

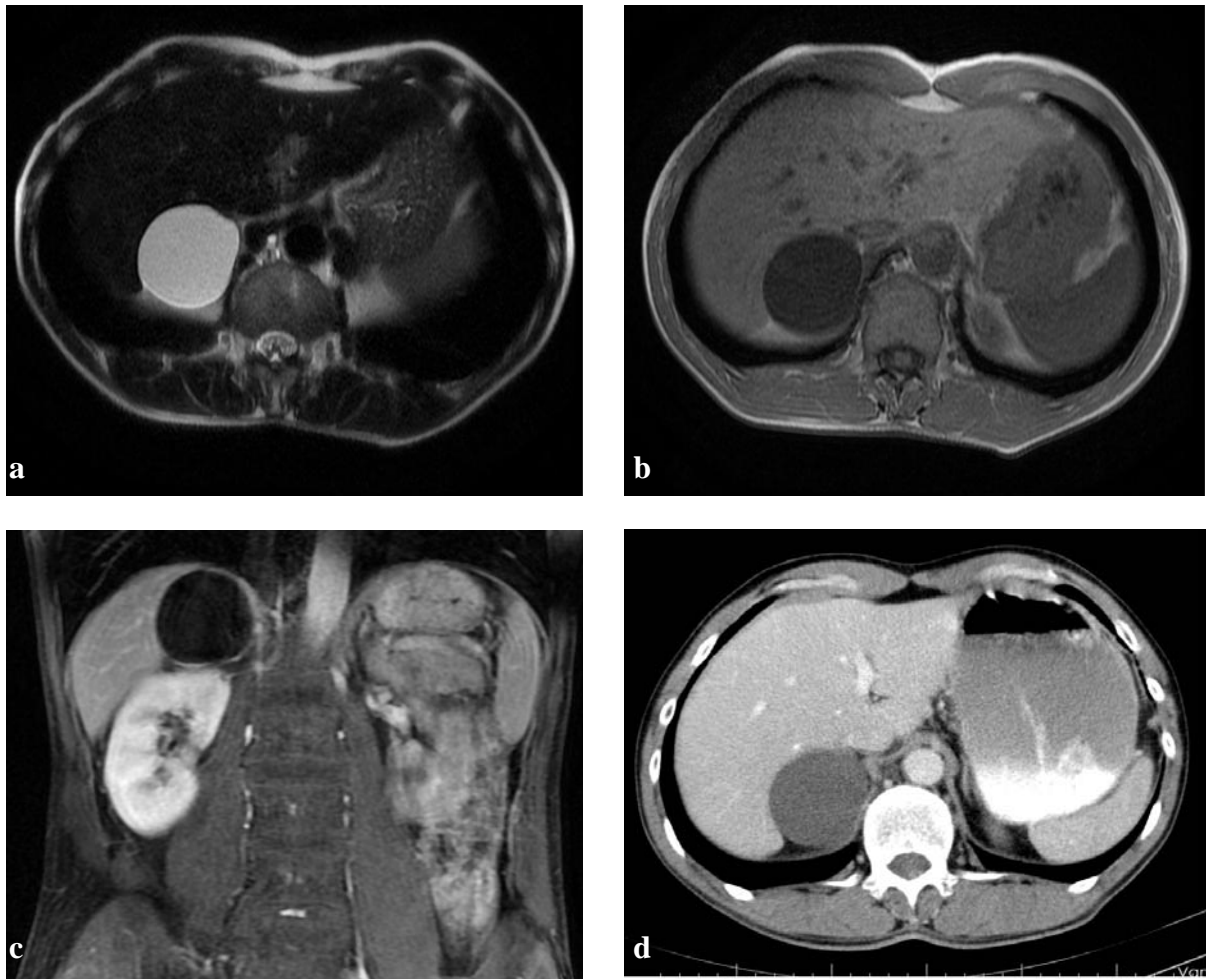


Fig. 1. CT (a), T1 (b), T2 (c) and postcontrast T1 (d) weighted MR image reveal the unilocular, wellcircumscribed, pure liquid nature of a right adrenal gland cyst.

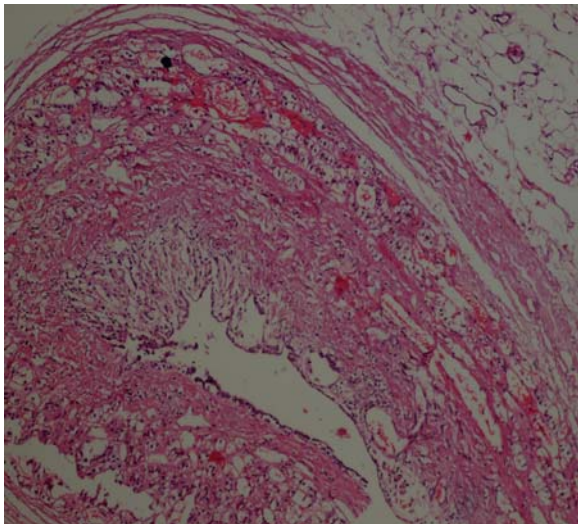


Fig. 2. Microscopic section of the excised adrenal cyst shows the adrenal tissue and the cyst wall, which comprised fibrous tissue with epithelial or endothelial lining (hematoxylin–eosin stain, original magnification $\times 100$).

3. Discussion

Adrenal gland cysts are uncommon entities and four pathological subtypes have been described: (1) cystic degeneration of adrenal neoplasms, (2) true cysts, (3) pseudocysts and (4) infectious cysts. Among adrenal cysts the most common types are epithelial cysts and pseudocysts. True cysts are lined with endothelial or mesothelial cells. Pseudocysts are cysts that are not covered by any type of epithelium and are surrounded by a fibrous wall within the adrenal gland (4). The most frequent cause of infectious cysts is *Echinococcus* (5). However, our case presents some differences in the epithelium covering the cyst. Accordingly, a part of the cyst wall was covered by flat epithelium. Immunohistochemical staining for CD34 was positive in the flat epithelium, which revealed that the cells of this region were of endothelial origin. Endothelial cysts are divided into two groups, as angiomatous and lymphangiomatous.

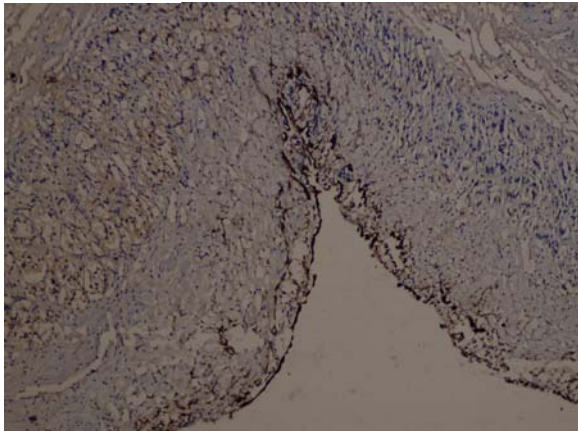


Fig. 3. The cyst lining expressed intensely cyokeratin (Immunoperoxidase stain x 200).

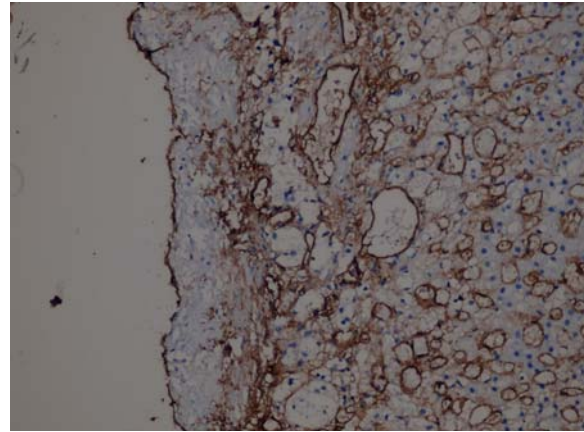


Fig. 4. The cyst lining expressed intensely CD 34 (Immunoperoxidase stain x 200).

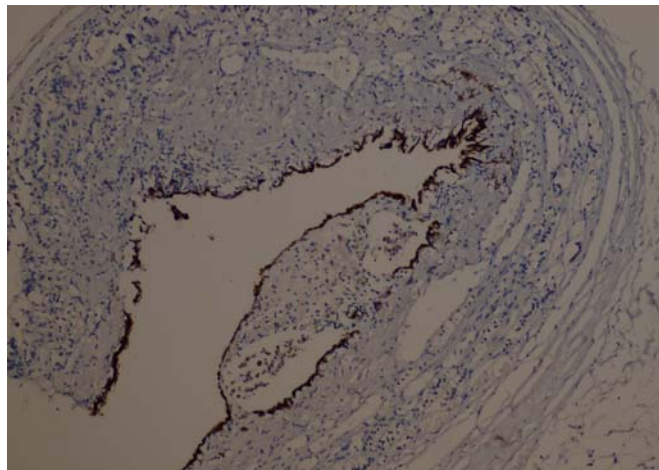


Fig. 5. The cyst lining expressed intensely calretinin (Immunoperoxidase stain x 100).

While lymphangiomatous endothelial cyst is the most frequent, demonstrated by positive D2-40 immunostaining, angiomatous endothelial cyst is the most frequent, demonstrated by positive CD31 and CD34 immunostaining. Positive staining with CD34 showed that the cyst was of angiomatous type. In other regions of the cystic wall, cubic epithelium and mesothelial cells were observed. Positive expression was observed with cyokeratin in the epithelium. On the other hand, positive staining was seen with cyokeratin 7 and calretinin in the epithelium, which was suggested of mesothelium. According to these findings, the cyst was evaluated as a mixed-type adrenal cyst. However, no adrenal cyst of mixed-type has been detected in the literature. Herein, we report the first case of mixed-type adrenal cyst in the literature.

Adrenal cysts may appear in any age group, but are frequent in the fifth and sixth decades. They are usually asymptomatic. In the symptomatic types, the symptoms are usually related to the

size and hormonal activity of the cyst. Complaints such as flank pain, nausea and vomiting due to compression on the pylorus, and distension may be observed in large-sized cysts. The most frequent complain on admission was flank pain (6).

Approximately 7% of all adrenal cysts are malignant or have the potential of malignancy (1). Most adrenal cysts are asymptomatic and are detected incidentally (7). Since only a very small number of adrenal cysts are functional, they do not have characteristic symptoms. Differential diagnosis should be performed to eliminate disorders of the liver, spleen, pancreas and kidney cysts, kidney tumors and cholecystitis in adults, and Wilm's tumor and multicystic renal dysplasia in children, which are clinically unilateral (8).

Histopathologically, cystic degenerated adrenal neoplasia, primary adrenal neoplasias, (pheochromocytoma, adrenal cortical adenoma, adrenal cortical carcinoma) or metastatic tumors

should be considered in the differential diagnosis. The pathological importance of these cysts are their co-existence with incidental malignancies. Therefore, a careful macroscopic examination should be performed and the highest possible number of samples should be obtained, even if they have a benign appearance. Beside the histopathological examination, immunohistochemical analyses are the common studies in the differential diagnosis of adrenal cysts (9).

The examination of the wall structure, size, density, the presence of a solid component, and the contrasting of the solid component on computed tomography analysis may provide a suggestion for a possible malignancy, but the precise diagnosis necessitates histopathological examination (10). Our case had presented to our general surgery department with upper right quadrant pain. Sensitivity was present on palpation. The findings were non-specific. On ultrasonographic images, a 5-cm-cyst was present in the right adrenal gland with regular contours. The computed tomography on the other hand, demonstrated a cystic mass in the right adrenal gland which caused compression on the liver. The precise diagnosis was made via histopathology.

In conclusion, although the screening methods are widely used in the determination of adrenal cysts, the precise diagnosis and typing can be determined via histopathological and immunohistochemical examinations. The cyst that

was detected histopathologically and immunohistochemically in our case, was diagnosed as a mixed-type adrenal cyst, which was the first in the literature.

References

1. Khan MR, Ajmal S, Saleem T. Giant adrenal endothelial cyst associated with acute and chronic morbidity in a young female: A case report. *Cases Journal* 2009; 2:8841.
2. Foster DG. Adrenal cysts: review of the literature and report of a case. *Arch. Surg* 1966; 92:131-143.
3. Lloyd RV, Douglas BR, Young WF. *Endocrine Diseases*. (1st ed) American Registry of Pathology Press, Washington 2002; 205-206.
4. Stimac G, Katusic J, Sucic M, et al. A Giant Hemorrhagic Adrenal Pseudocyst Case Report. *Med Princ Pract* 2008; 17:419-421.
5. Fitzgerald EJ. Hydatid disease of the adrenal gland. *Ir J Med Sci* 1987; 156:366-367.
6. Schmid H, Mussack T, Wornle M, Pietrzyk MC, Banas B. Clinical management of large adrenal cystic lesions. *Int Urol Nephrol* 2005; 37:767-771.
7. Inan M, Besim H, Tulay S, Kobat I. Giant symptomatic adrenal cyst in a patient with an ectopic kidney. *Can J Surg* 2009; 52:25-26.
8. Arıcı S, Eğilmez R, Yıldız E, Karşlı Ş. Adrenal cysts. *Turkish Journal of Pathology* 1996; 12:14-15.
9. Bal N, Koçer NE, Ezer A, Bolat F, Kayaselçuk F. Adrenal cysts: Report of six cases and review of the literature. *Turkish Journal of Pathology* 2007; 23:43-47.
10. Pradeep PV, Mishra AK, Aggarwal V, et al. Adrenal cysts: an institutional experience. *World J Surg* 2006; 30:1817-1820.