

Case Report

Presented with central nervous system involvement, extra- pulmonary and intra-pulmonary tuberculosis combined infection in a dialysis patient

Hulya Gunbatar^{a,*}, Gulay Bulut^b, Yasemin Soyoral^c, Bunyamin Sertogullarindan^a, Senar Ebinc^d

^aDepartment of Pulmonary and Critical Care, Yuzuncu Yil University Medical Faculty, Van, Turkey

^bDepartment of Pathology, Yuzuncu Yil University Medical Faculty, Van, Turkey

^cDepartment of Internal Medicine, Division of Nephrology, Yuzuncu Yil University Medical Faculty, Van, Turkey

^dDepartment of Internal Medicine, Yuzuncu Yil University Medical Faculty, Van, Turkey

Abstract. The clinical appearance of *Mycobacterium tuberculosis* (TB) in patients on dialysis are substantially non-specific that makes diagnosis difficult. We report a case of extrapulmonary and intrapulmonary TB in end stage renal disease (ESRD). A 58- year-old female with ESRD was admitted to emergency with the complaints of intermittent fever, weakness, impairment of consciousness for last three days. Because of mental confusion she was intubated, transferred to the intensive care unit. Thorax CT showed widespread centrilobular nodules in both lungs. The empirically anti-TB therapy was initiated. There was in size of 4x5 cm palpable lymphadenopathy on left supraclavicular region, excisional biopsy revealed caseating granulomatous lymphadenitis. Lumbar puncture was performed and analysis was consistent with TB meningitis. The patient was diagnosed as miliary TB, TB meningitis and TB lymphadenitis and died on the tenth day on admission. Increased awareness of TB in the ESRD population, early diagnosis and treatment are very important.

Key words: Tuberculosis, extrapulmonary, intrapulmonary, end stage renal disease

1. Introduction

Mycobacterium tuberculosis (TB) has been an important health problem in worldwide. Many risk factors are associated with TB, such as renal insufficiency, human immunodeficiency virus (HIV), malignancy, transplant recipients, substance abuse and low socioeconomic status (1,2). Because of cellular immune disturbance, patients with end stage renal disease (ESRD) have an increased TB incidence (3-5). However, the clinical appearance of TB in patients on dialysis are substantially non-specific that makes diagnosis difficult (6,7). There were amounting 136/100,000 new cases of tuberculosis in population and 6,1 million of them which amounts to 24/100,000 lost their lives because of

the disease according to the World Health Organization Report (WHO) in 2007 (8). The incidence of TB was 30/100,000 in the WHO spherical tuberculosis control Turkey report in 2009 (9). Tuberculosis may be classified as pulmonary or extrapulmonary; miliary disease has been classified as both an extrapulmonary and a pulmonary form of TB. Miliary TB applies to clinical disease resulting from the hematogenous dissemination of *Mycobacterium tuberculosis* that affects multiple organs and systems. Miliary TB can appear as a result of progressive primary infection or via reactivation of a latent focus with subsequent spread. Tuberculous lymphadenitis is among the most frequent presentations of extrapulmonary TB. The epidemiology of TB lymphadenitis changes between developed and developing countries, in actual series it represents 63 to 77 percent of cases (10,11). Central nervous system (CNS) disease was observed in 15 to 20 percent of patients with TB (12-14). Among patients with tuberculous meningitis, about one-third to one-half had miliary TB; meningeal involvement was prominent postmortem in 54 percent of cases of miliary TB in one series (15). The rate of TB meningitidis is unknown among dialysis patients.

*Corresponding Author: Dr. Hulya Gunbatar
Yuzuncu Yil University Medical Faculty,
Department of Pulmonary and Critical Care, Kampus/ Van
/Turkey
Phone; +90432 2150470-6135; +90 5065118827
E-mail: hulyagunbatar@hotmail.com
Received: 29.09.2014
Accepted: 06.07.2015

Here we report a case of extrapulmonary and intrapulmonary tuberculosis (central nervous system involvement, tuberculosis lymphadenitis and miliary tuberculosis) in end stage renal disease patient on dialysis.

2. Case report

A 58-year-old female with end stage renal disease due to polycystic renal disease had been treated by hemodialysis three times a week for three years. She was admitted to emergency with the complaints of intermittent fever, weakness, impairment of consciousness for last three days.

In her history; she had admitted to another epicentral hospital with the complaints of fever and diarrhea 1 month ago. Because of the hypokalemia nephrology clinic had inherited the patient. She had received symptomatic treatment but any other investigation was unperformed about tuberculosis.

On admission she was unconscious, non oriented. Her body temperature fluctuated between 38,0 and 39,0 °C. She had mild hypotension (100/70mmHg), a pulse rate of 90 beats/min and respiratory rate of 22/min. Results of a neurologic examination revealed weakness in the right upper and lower extremities with motor power 4/5, bilaterally babinski was reckless. Coarsening on respiratory sounds was seen. There was in size of 4x5 cm palpable lymphadenopathy on left supraclavicular region. Because of mental confusion she was entubated, transferred to the intensive care unit.

Laboratory investigations showed that her hemoglobin (HGB) levels were 9,1 g/dl, erythrocyte sedimentation rate (ESR) was 56 mm/h (normal <20 mm/h), C-reactive protein (CRP) levels were 118 mg/dl (normal <5 mg/dl),

lactate dehydrogenase were 627 U/L and creatine kinase 90 IU/L. The tuberculin skin test (TST) was strongly positive. Chest X-ray showed bilateral micronodular opacities consistent with miliary tuberculosis. The computed tomography (CT) scan and magnetic resonance imaging of brain showed minimal enlargement on lateral ventricle. Lumbar puncture was performed to the patient, cerebrospinal fluid analysis showed; glucose 63 mg/dl, chloride 128 mmol/L, protein 89 mg/dl.

Thorax CT showed widespread centryacinar nodules in both lungs and areas of ground glass opacities. (Figure 1). The empirically diagnostic anti-TB therapy of isoniazid (INH) and rifampin (RFP), pyrazinamide (PZA), and ethambutol (EMB) was initiated.

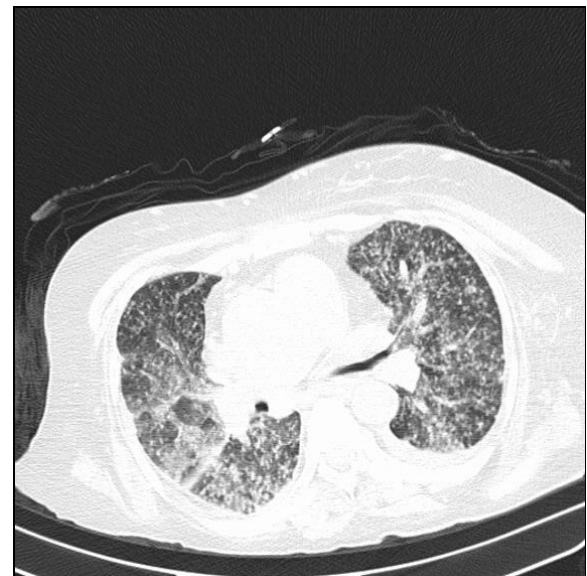

Fig. 1. Widespread sentriasiner nodules in both lungs and areas of ground glass opacities.

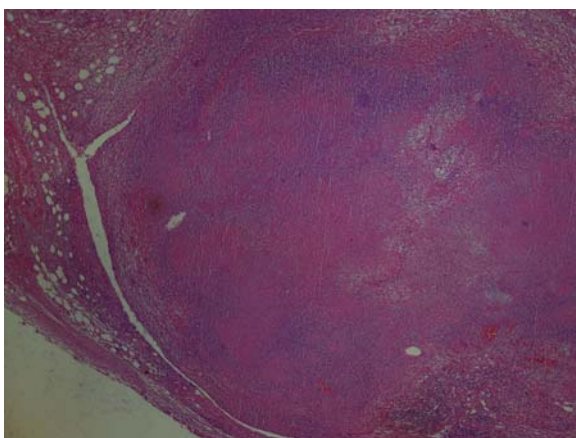


Fig. 2. Microscopic appearance of caseous granulomatous inflammation in the tuberculous lymphadenitis of the lymph node (HEX40).

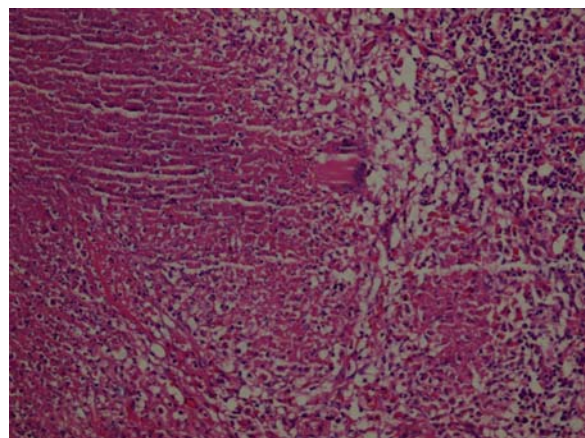


Fig. 3. The pathologic examination of the specimen demonstrates granulomatous inflammation (Hex200).

On thyroid ultrasound, thyroid was heterogeneous and containing multiple calcifications. Fine needle aspiration on the thyroid was performed. Results of pathological analysis was benign. Excisional left supraclavicular lymph node biopsy revealed caseating granulomatous lymphadenitis (Figure 2,3). The patient was diagnosed as miliary TB, TB meningitis and TB lymphadenitis. The patient died on the tenth day on admission.

3. Discussion

ESRD is an aggravating factor for TB infection and there is an increased incidence (16-18). Uremia itself is known to cause impaired T-cell response, the reason of the decreased cellular immunity might be a defect in the co-stimulatory function of antigen-presenting cells and a persistent inflammatory situation of monocytes. Risk factors such as impaired cellular immunity, damaged mucus membranes and skin, malnutrition, acidosis, vitamin D deficiency, hyperparathyroidism, low socioeconomic status, living in crowded conditions and some ethnicities are likely reasons for the increased risk especially in endemic regions (19,20). Depending on the stage of immunosuppression, the presentation of *Mycobacterium tuberculosis* in patients with ESRD can be atypical and difficult to diagnose compared with the classical presentation of *Mycobacterium tuberculosis* in non-immunocompromised persons. Extrapulmonary tuberculosis is common in patients with ESRD, and involvement of lymph nodes is the most common extrapulmonary presentation. The incidence of active TB among patients on long-term dialysis was reported as 1.6 to 5.8% in developed countries (21,22), in Turkey, it was reported as 6.08–23.6% (23). Of 256 patients undergoing hemodialysis regularly between 1990 and 2000, eighteen tuberculosis patients (7%) were reported by Abdelrahman et al.(24) pulmonary tuberculosis was seen in only 4 cases (22.2%), compared with 14 cases presented with extra-pulmonary tuberculosis (77.8%). A total of 287 dialysis patients 64 continuous ambulatory peritoneal dialysis (CAPD) patients were reviewed from October 1997 to January 2002 by Erkoc et al.(20) TB was seen in 30 patients. Thirteen patients with TB presented with fever of unknown origin and four of them developed miliary lesions on chest X-ray. Nine patients had pulmonary TB (four with pleural effusions), five patients had TB lymphadenitis, two patients had TB peritonitis and one patient had vertebral TB. Kazancioglu et al. reported that pulmonary involvement (51.61%) was the most common

form, while extrapulmonary tuberculosis formed the remaining 48.39% in their study (25). As stated above miliary tuberculosis and tuberculosis meningitidis are very rare conditions. Studies from different regions of our country any TB meningitidis cases have been reported (19,20,25).

Because of the weak clinical appearance such as non-specific fever, anorexia fatigue, cough, weight loss diagnosis becomes difficult. Surprisingly in our case there has been a delay in diagnosis until loss of consciousness. In addition multiple forms of TB; TB lymphadenitis, TB meningitidis and miliary TB was seen altogether in our case. In this respect, our patient is the first case that has presented multiple forms of TB in dialysis patients in the literature as far as we know. We suggest that TB lymphadenitis occurred before the onset of other forms. Follow-up of extrapulmonary tuberculosis is very important in patients with ESRD in areas which have a high incidence of tuberculosis. TB should be considered severely and treated urgently if suspected (26). Mortality rate of TB was reported as 0-75% of cases (27,28).

Conclusion; increased awareness of TB in the ESRD population, early diagnosis and treatment in this condition are very important, in order to improve the outcomes and prevent the mortalities.

References

1. Lee S.S, Chou K.J, Su I.J, Chen Y.S, et al. High prevalence of latent tuberculosis infection in patients in end-stage renal disease on hemodialysis: comparison of QuantiFERON-TB GOLD, ELISPOT, and tuberculin skin test. *Infection* 2009; 37: 96-102.
2. Li S.Y, Chen T.J, Chung K.W, et al. *Mycobacterium tuberculosis* infection of end-stage renal disease patients in Taiwan: a nationwide longitudinal study. *Clin.Microbiol.Infect* 2011; 17: 1646-1652.
3. Ates G, Yildiz T, Danis R, et al. Incidence of tuberculosis disease and latent tuberculosis infection in patients with end stage renal disease in an endemic region. *Ren.Fail* 2010; 32: 91-95.
4. Lui S.L, Yip T, Tse K.C, Chan T.M, Lai K.N, Lo W.K. Tuberculous lymphadenitis in patients undergoing continuous ambulatory peritoneal dialysis. *Int.Urol. Nephrol* 2007; 39: 971-974.
5. Kuno Y, Iyoda M, Aoshima Y, et al. A case of tuberculous peritonitis in a hemodialysis patient with high serum soluble interleukin-2 receptor and CA-125 levels. *Intern.Med* 2010; 49: 1783-1786.
6. Fukasawa H, Suzuki H, Kato A, et al. Tuberculous arthritis mimicking neoplasm in a hemodialysis patient. *Am.J.Med.Sci* 2001; 322: 373-375.
7. Ko Y.C, Lee C.T, Cheng Y.F, et al. Hypercalcaemia and haemophagocytic syndrome: rare concurrent presentations of disseminated tuberculosis in a dialysis patient. *Int J Clin Pract* 2004; 58: 723-725.
8. World Health Organization, Global tuberculosis control: Surveillance, planning, financing.WHO

- Report 2007, WHO, Geneva (2007)(WHO/HTM/TB 2007.376).
9. World Health Organization Global tuberculosis control: epidemiology, strategy, financing: WHO report 2009 WHO/HTM/TB/2009.41 Year: 2009
 10. Geldmacher H, Taube C, Kroeger C, Magnussen H, Kirsten DK. Assessment of lymph node tuberculosis in northern Germany: a clinical review. *Chest* 2002; 121: 1177-1182.
 11. Mert A, Tabak F, Ozaras R, Tahan V, Öztürk R, Aktuğlu Y. Tuberculous lymphadenopathy in adults: a review of 35 cases. *Acta Chir Belg* 2002; 102: 118-121.
 12. Maartens G, Willcox PA, Benatar SR. Miliary tuberculosis: rapid diagnosis, hematologic abnormalities, and outcome in 109 treated adults. *Am J Med* 1990; 89: 291-296.
 13. Kim JH, Langston AA, Gallis HA. Miliary tuberculosis: epidemiology, clinical manifestations, diagnosis, and outcome. *Rev Infect Dis* 1990; 12: 583-590.
 14. Gelb AF, Leffler C, Brewin A, Mascatello V, Lyons HA. Miliary tuberculosis. *Am Rev Respir Dis* 1973; 108: 1327-1333.
 15. Slavin RE, Walsh TJ, Pollack AD. Late generalized tuberculosis: a clinical pathologic analysis and comparison of 100 cases in the preantibiotic and antibiotic eras. *Medicine (Baltimore)* 1980; 59: 352-366.
 16. Yalcinkaya F, Tumer N, Akar N, Ekim M, Bildirici Y. Tuberculous osteomyelitis: an unusual case of tuberculous infection in a child undergoing continuous ambulatory peritoneal dialysis. *Pediatr.Nephrol* 1995; 9: 485-486.
 17. Peces, R., de la Torre M, Alcazar R. Visceral leishmaniasis and renal tuberculosis in a patient on maintenance haemodialysis. *Nephrol.Dial.Transplant.*, 1996; 11: 707-708.
 18. Summers S.A, Gupta R.K, Clutterbuck E.J, Laing C, Cooke G.S. Haemodialysis catheter-associated infection: common pathogens in unusual places. *Nephrol.Dial.Transplant* 2005; 20: 2287-2288.
 19. Sen N, Turunc T, Karatasli M, Sezer S, Demiroglu YZ, Oner Eyuboglu F. Tuberculosis in patients with end-stage renal disease undergoing dialysis in an endemic region of Turkey. *Transplant Proc* 2008; 40: 81-84.
 20. Erkok R, Dogan E, Sayarlioglu H, et al. Tuberculosis in dialysis patients, single centre experience from an endemic area. *Int J Clin Pract* 2004;58(12):1115-1117
 21. Belcon MC, Smith EK, Roujouleh H. Tuberculosis in dialysis patients. *Clin Nephrol* 1982; 17: 14-18.
 22. Andrew OT, Schoenfeld PY, Hopewell PC, Humphreys MH. Tuberculosis in patients with end-stage renal disease. *Am J Med* 1980; 68: 59-65.
 23. Taskapan H, Utas C, Oymak FS, Gulmez I, Ozesmi M. The outcome of tuberculosis in patients on chronic hemodialysis. *Clin Nephrol* 2000; 54: 134-137.
 24. Abdelrahman M, Sinha A.K, Karkar A. Tuberculosis in end-stage renal disease patients on hemodialysis. *Hemodialysis International* 2006; 10: 360-364.
 25. Kazancioglu R, Ozturk S, Gursu M, et al. Tuberculosis in patients on hemodialysis in an endemic region. *Hemodial Int.* 2010; 14: 505-509.
 26. Valek M, Sulkova S, Slovakova A, Drobilcova M, Sagova M. Tuberculosis in patients with chronic kidney failure. *Cas Lek Cesk* 2003; 142: 271-275.
 27. Hussein MM, Mooij MJ, Roujouleh H. Tuberculosis and chronic renal disease. *Semin Dial* 2003; 16: 38-44.
 28. Cengiz K. Increased incidence of tuberculosis in patients under-going hemodialysis. *Nephron* 1996; 73: 421-424.