

# Is Fragmented Qrs Associated with The Severity Of Carotid Artery Disease?

Fragmente Qrs Karotis Arter Hastalığının Ciddiyeti İle İlişkili Midir?

Efe Edem<sup>1</sup>, Hasan Reyhanoğlu<sup>2</sup>

<sup>1</sup> İzmir Tınaztepe Hastanesi, Kardiyoloji. Orcid No: 0000-0002-5042-4077

<sup>2</sup> İzmir Tınaztepe Hastanesi, Kalp Damar Cerrahi Orcid No: 0000-0002-2872-3361

Yazışma Adresi / Correspondence:

**Efe Edem**

Ahmet Piriştina Blv. No:51 Tınaztepe, Buca, İzmir | Türkiye

T: +90 533 590 61 87 E-mail: edemefe@gmail.com

Geliş Tarihi / Received : 13.01.2018 Kabul Tarihi / Accepted : 10.04.2018

## Abstract

Objective	This study investigated the association between fragmented QRS and the severity of carotid artery disease. ( <i>Sakarya Med J</i> , 2018, 8(2):279-284 )
Materials and Methods	168 patients who underwent carotid angiography due to transient ischemic attack or ischemic stroke between March 2009 and July 2017 were enrolled in the study. Patients enrolled in the study were divided into two groups according to severity of carotid artery disease on carotid angiography. Group One consisted of patients with a carotid stenosis of <50% (n:82) and group 2 consisted of patients with a carotid stenosis of ≥50% (n:86). Two groups were compared in terms of existence of fragmented QRS on electrocardiogram prior to carotid endarterectomy by using hospital records.
Results	The study group consisted of 168 patients. Group One showed more male predominance and this indicated a significant difference in terms of gender between two groups (p=0.026). Existence of chronic obstructive pulmonary disease was more common in group 2 and this indicated a statistically significant difference (p=0.001). 12-lead ECG of patients in group 2 tended to demonstrate fQRS much frequently compared to patients in group 1 (p=0.002).
Conclusion	fQRS seems to be associated with the severity of CAD and assessment of fQRS can be a predictive factor to determine high risk patients for concealed coronary artery disease in patients with severe carotid artery disease and without a history of coronary artery disease.
Keywords	Electrocardiography, Coronary artery disease, Carotid artery disease

## Öz

Amaç	Bu çalışmada fragmente QRS ile karotis arter hastalığının ciddiyeti arasındaki ilişki araştırılmıştır. ( <i>Sakarya Tıp Dergisi</i> , 2018, 8(2):279-284 ).
Gereç ve Yöntem	Mart 2009 ve Temmuz 2017 tarihleri arasında geçici iskemik atak veya iskemik inme nedeni karotis anjiyografi uygulanan 168 hasta çalışmaya dahil edildi. Çalışmaya dahil edilen hastalar karotis anjiyografideki karotis arter hastalığının ciddiyetine göre 2 sınıfa ayrıldı. İlk grupta karotis darlığı %50'nin altında olan hastalar var iken (n:82) ikinci grupta karotis darlığı ≥%50 olan hastalardan oluşmaktaydı (n:86). İki grup karotis endarterektomi ameliyatı öncesi elektrokardiogramları taranarak fragmente QRS varlığı açısından karşılaştırıldı. .
Bulgular	Çalışma popülasyonu toplam 168 hastadan oluşmaktaydı. Birinci grupta erkek cinsiyet hakimdi ve bu istatistiksel olarak anlamlı idi (p=0.026). Kronik obstrüktif akciğer hastalığı ise ikinci grupta daha fazla idi ve bu istatistiksel olarak anlamlı idi (p=0.001). İkinci gruptaki hastaların 12 derivasyonlu elektrokardiogramlarında fragmente QRS varlığı birinci gruba kıyasla istatistiksel olarak daha fazla idi (p=0.002).
Sonuç	Fragmente QRS varlığı karotis arter hastalığının ciddiyeti ile ilişkili görünmektedir. Fragmente QRS değerlendirilmesi ciddi karotis arter hastalığına sahip olup tanısı konmamış latent koroner arter hastalığı olan hastaların saptanmasını tahmin ettirici bir faktör olarak kullanılabilir.
Anahtar Kelimeler	Elektrokardiografi, Koroner Arter Hastalığı, Karotis Arter Hastalığı

## Introduction

Atherosclerosis is a widespread disease which contributes to morbidity and mortality in general population.<sup>1</sup> Since it is a general disease of the arterial system, carotid artery disease (CAD) frequently accompanies with coronary artery disease (CoAD). Fragmented QRS (fQRS) is a novel electrocardiographic parameter which reflects the heterogenous myocardial depolarization from regional ischemia, scar or myocardial fibrosis.<sup>2</sup> The existence of fQRS has been demonstrated to presume adverse outcomes in various diseases such as acute coronary syndrome, CAD, ischemic or nonischemic cardiomyopathy, and prior myocardial infarction (MI) showing resolved Q waves.<sup>3-7</sup> In clinical practice, it is important for physicians to decide which patient should be scanned for CoAD especially if the patient is diagnosed with CAD without a prior history of CoAD. Thus, in the current study, we aimed to evaluate the association between the existence of fQRS and the severity of CAD in order to predict these patients with a concealed CoAD .

## Materials and Methods

The current study is a single-center retrospective study. The study protocol was approved by a local noninvasive Ethics Committee. 206 patients who underwent carotid angiography between March 2009 and July 2017 were screened. Patients with previously known CoAD, echocardiographic regional wall motion abnormalities, and pathologic Q waves on electrocardiogram (ECG) that may already carry fQRS were excluded from the study. Remaining 168 patients were enrolled in the study. Standard 12 lead ECG of each patient was analyzed for fQRS; additional R wave or notching in the nadir of the S wave, or the presence of 2 R (fragmentation) in 2 contiguous leads with a QRS duration of <120ms.

Carotid angiography (CA) was indicated only when the patients were symptomatic and diagnosed with a  $\geq 50\%$  narrowing of internal carotid artery (ICA) via performing doppler ultrasound (US) of the carotid artery. Symptomatic patients were defined as patients suffering from a transient ischemic attack (TIA) or an ischemic stroke within the last six months. To measure carotid stenosis (CS)% on a B-mode US or color Doppler; the most stenotic segment of the ICA was captured using 9-3 MHz linear transducer on a longitudinal image and by measurement of peak systolic velocity at the Doppler angle of insonation  $60^\circ$ . After capturing a transverse scan of the most stenotic segment of ICA on a B-mode US or color Doppler, the original diameter (OD) and residual diameter (RD) were measured by using electronic calipers. The RD was defined as the shortest diameter of the residual lumen at the most stenotic segment of ICA and OD was defined as the measured diameter from the outer media to the outer media of the diseased artery on the same plane and at same direction with the RD. The CS% on B-mode US was calculated by using the following equation:  $CS\% = (1 - [RD/OD]) \times 100\%$ . This method is used in our institution according to text books. The CA images were reviewed by two investigators who were blinded to the results of the B-mode US exam. There was no significant interobserver variability. The CS% on CA was measured at the most stenotic segment of ICA according to North American Symptomatic Carotid Endarterectomy Trial (NASCET) method by using electronic calipers on a picture archiving and communication system image. Between anterior-posterior and the lateral views of the carotid artery stenosis, the more stenotic one was selected in measurement of CS%. Carotid endarterectomy (CEA) was typically indicated for patients who have had symptoms (stroke or TIA) and have blockage greater than 50%.

Patients enrolled in the study were divided into two groups according to severity of CAD. Group One consisted of patients who were diagnosed with a <50% CS on CA in whom eventual medical treatment was applied. On the other hand, Group Two consisted of patients who were diagnosed with a ≥50% CS on CA in whom eventual CEA was performed.

### Statistical Analysis

Statistical analysis was performed using IBM SPSS Statistics, Version 20.0 (IBM, Armonk, NY). Data were presented as mean, standard deviation, median, minimum, maximum, percent and number. Cross tables were constructed for qualitative variables and their distribution was assessed by Chi Square Test. A p value of <0.05 was considered a statistically significant difference for the 95% confidence interval.

### Results

The study group consisted of 168 patients. Mean age of the study population was 63.37±11.95. 130 of them were male (77.4%) and 38 of them were female (%22.7). Demographic characteristics of the study population is presented in Table 1. Group One showed more male predominance and this indicated a significant difference in terms of gender between two groups (p=0.026). Existence of chronic obstructive pulmonary disease was more common in Group Two and this indicated a statistically significant difference (p=0.001). Patients in Group Two were significantly older compared to patients in Group One (p<0.001). 12-lead ECG of patients in Group Two tended to demonstrate fQRS much frequently compared to patients in group 1 (p=0.002) (Figure 1).

**Table 1 -Demographic characteristics of the study group.**

	Group 1 (Medical Follow-up) (n:82)	Group 2 (Carotid Artery Surgery) (n:86)	P Value
Age (years)	57.5±11.76	68.97±9.16	p<0.001
Diabetes Mellitus (positive vs. negative)	(n:20 vs n:62) 24.4% vs. 75.6%	(n:31 vs n:55) 36.0% vs. 64.0%	p=0.140
Hyperlipidemia (positive vs. negative)	(n:27 vs n:55) 32.9% vs. 67.1%	(n:32 vs n:54) 37.2% vs. 62.8%	p=0.561
Hypertension (positive vs. negative)	(n:33 vs n:49) 40.2% vs. 59.8%	(n:45 vs n:41) 52.3% vs. 47.7%	p=0.117
Smoking (positive vs. negative)	(n:52 vs n:30) 63.4% vs. 36.6%	(n:44 vs n:42) 51.2% vs. 48.8%	p=0.109
COPD (positive vs. negative)	(n:6 vs n:76) 7.3% vs. 92.7%	(n:24 vs n:62) 27.9% vs. 72.1%	p=0.001
Gender (Male vs. Female)	(n:70 vs n:12) 85.4% vs. 14.6%	(n:60 vs n:26) 69.8% vs. 30.2%	p=0.026

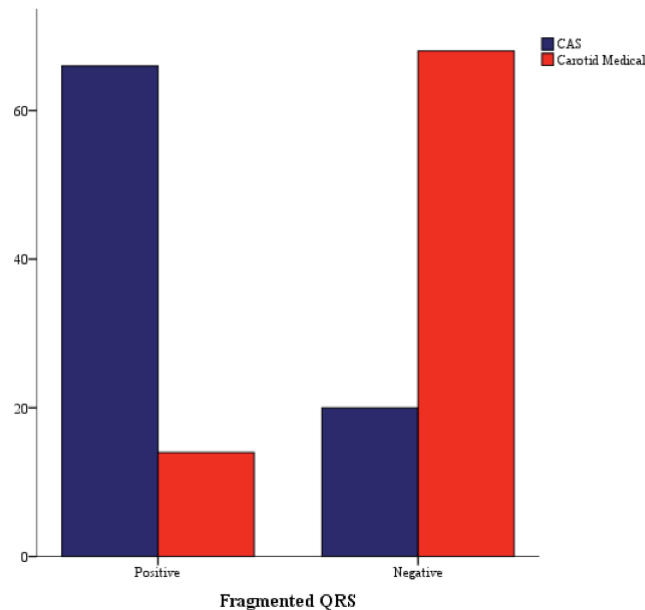


Figure 1 : Vertical bars expressing that the existence of fragmented QRS is more frequent in patients in whom Carotid Artery Surgery (CAS) was performed compared to patients who were medically followed-up ( $p=0.002$ ).

### Discussion

Recent studies indicated that patients with CoAD have a high risk profile in terms of postoperative myocardial complications.<sup>8,9</sup> Considering the systemic nature of atherosclerosis, there is a high prevalence of CoAD in this patient population scheduled for CEA. Some studies in literature have demonstrated that coronary angiography and revascularisation if needed prevent postoperative cardiac events during and after non-cardiac surgery.<sup>10-11</sup> In clinical practice, it is a usual approach for surgeons to screen the patients undergoing CEA in terms of underlying obstructive CoAD if there is history of CoAD or a sign of ischemia on ECG or echocardiography. On the other hand, the question still remains: 'Shall we perform routine coronary angiography before CEA in asymptomatic patients?'

Signs of ischemia on ECG include ST segment depression, T wave flattening or inversion, and pathological Q waves. Recently, a novel ECG parameter called fragmented QRS started taking its place in daily practice. In 2017, Joo Lee et al. showed that fQRS was related with myocardial scar or left ventricular dysfunction in patients with structural heart disease as well as with normal hearts. They also demonstrated that patients with CoAD were more apt to be male with notching of the QRS complex and fQRS on ECG compared to patients who showed normal coronary angiography.<sup>12</sup> In addition, Korkmaz et al. indicated that the presence of fQRS on ECG was associated with myocardial ischemia in patients with intermittent coronary stenosis.<sup>13</sup>

Given the underlying pathogenesis of atherosclerosis, one can conclude that the severity of CoAD increases as the severity of CAD increases. Indeed, analysis of our single-center patient data who underwent CEA showed that as the extension and severity of CAD worsened, the frequency of QRS fragmentation on 12-lead ECG increased in patients without a history of CoAD. Thus, in the light of new developments, we believe that patients undergoing CEA with fQRS on ECG and without a history of CoAD should be carefully investigated in terms of underlying CoAD for minimizing postoperative myocardial complications.

This study demonstrated that fQRS is associated with the severity of CAD and fQRS can be used as a useful and cheap indicator for predicting significant CoAD in patients undergoing CEA without a history of former CoAD.

### **Study Limitations**

The most important limitation of our study is that we were not able to perform coronary angiography in patients with CAD during the follow-up. Thus, large-scale studies about the follow-up data of the study population including coronary angiography results would be more helpful in terms of predicting the roles of fQRS in the setting of severe CAD.

### **Conflict of Interest**

None declared.

Sakarya Med J  
2018;8(2):279-284

**EDEM et al.**  
Is Fragmented Qrs Associated with  
The Severity of Carotid Artery Disease?

1. Bhatt DL, Eagle KA, Ohman EM, Hirsch AT, Goto S, Mahoney EM, et al. Comparative determinants of 4-year cardiovascular event rates in stable outpatients at risk of or with atherothrombosis. *JAMA* 2010;304:1350e1357.
2. Basaran Y, Tigen K, Karahmet T, Isiklar I, Cevik C, Gurel E, et al. Fragmented QRS complexes are associated with cardiac fibrosis and significant intraventricular systolic dyssynchrony in nonischemic dilated cardiomyopathy patients with a narrow QRS interval. *Echocardiography* 2011;28(1):62–68.
3. Das MK, Saha C, El Masry H, Peng J, Dandamudi G, Mahenthiran J, et al. Fragmented QRS on a 12-lead ECG: A predictor of mortality and cardiac events in patients with coronary artery disease. *Heart Rhythm* 2007;4:1385–1392.
4. Chatterjee S, Changawala N. Fragmented QRS complex: A novel marker of cardiovascular disease. *Clin Cardiol* 2010;33:68–71
5. Das MK, Maskoun W, Shen C, Michael MA, Suradi H, Desai M, et al. Fragmented QRS on twelve-lead electrocardiogram predicts arrhythmic events in patients with ischemic and nonischemic cardiomyopathy. *Heart Rhythm* 2010;7:74–80.
6. Canpolat U, Kabakci G, Aytemir K, Dural M, Sahiner L, Yorgun H, et al. Fragmented QRS complex predicts the arrhythmic events in patients with arrhythmogenic right ventricular cardiomyopathy/dysplasia. *J Cardiovasc Electrophysiol* 2013;24:1260–1266.
7. Wang J, Tang M, Mao KX, Chu JM, Hua W, Jia YH, et al. Idiopathic ventricular fibrillation with fragmented QRS complex and J wave in resting electrocardiogram. *J Geriatr Cardiol* 2012;9:143–147.
8. Godet G, Riou B, Bertrand M, Fle'ron MH, Goarin JP, Montalescot G, et al. Does preoperative coronary angioplasty improve postoperative cardiac outcome? *Anesthesiology* 2005;102:739e46.
9. Sprung J, Abdelmalak B, Gottlieb A, Mayhew C, Hammel J, Levy PJ, et al. Analysis of risk factors for myocardial infarction and cardiac mortality after major vascular surgery. *Anesthesiology* 2000;93:129e40.
10. Brilakis ES, Orford JL, Fasseas P, Wilson SH, Melby S, Lennon RJ, et al. Outcome of patients undergoing balloon angioplasty in the two months prior to noncardiac surgery. *Am J Cardiol* 2005; 96:512e4
11. Rihal CS, Eagle KA, Mickel MC, Foster ED, Sopko G, Gersh BJ. Surgical therapy for coronary artery disease among patients with combined coronary artery and peripheral vascular disease. *Circulation* 1995;91:46e53.
12. Jung JL, Jae HL, Jin WJ, Jun YC. Fragmented QRS and abnormal creatine kinase-MB are predictors of coronary artery disease in patients with angina and normal electrocardiographs. *Korean J Intern Med* 2017;32:469-477
13. Korkmaz A, Yildiz A, Demir M, Ozyazgan B, Sahan E, Acar B, et al. The relationship between fragmented QRS and functional significance of coronary lesions. *J Electrocardiol.* 2017 May - Jun;50(3):282-286.