



Posttraumatic pulmonary pseudocyst: Report of two cases

Posttravmatik pulmoner psödokist: İki olgu sunumu

Cihan Bedel¹, Muharrem Özkaya²

Abstract

Posttraumatic pulmonary pseudocyst is a rare complication of blunt thoracic trauma. It is commonly seen in pediatric and young adult patients. In the literature, traumatic pseudocysts are also defined as pseudocystic hematoma, traumatic lung cavity and traumatic pneumatocele. Traumatic pseudocysts usually have good clinical prognosis, recover spontaneously with supportive treatment and do not require surgery. In this report, we present rare cases of two posttraumatic pulmonary pseudocysts developed after traffic accidents, where conservative treatment contributed excellent outcomes.

Keywords: Chest trauma, traumatic pulmonary pseudocyst, cyst

Öz

Posttravmatik pulmoner psödokist künt toraks travmalarının nadir bir komplikasyonudur. Genellikle pediatrik ve genç erişkin hastalarda görülür. Literatürde travmatik psödokistler hematom, travmatik akciğer kavitesi ve travmatik pnömotosel olarak tanımlanmıştır. Travmatik psödokistler genellikle iyi bir klinik prognoza sahiptir, destek tedavisi ile kendiliğinden iyileşir ve ameliyat gerektirmezler. Bu yazıda, trafik kazasından sonra gelişen ve konservatif tedavinin mükemmel sonuçlarla katkıda bulunduğu iki nadir posttravmatik pulmoner psödokist olgusunu sunuyoruz.

Anahtar kelimeler: Toraks travması, travmatik pulmoner psödokist, kist

¹ Department of Emergency Medicine, Health Science University, Antalya Training and Research Hospital, Antalya, Turkey.

² Department of Thoracic and Cardiovascular Surgery, Health Science University, Antalya Training and Research Hospital, Antalya, Turkey.

Informed Consent: The written consent was received from the patient who was presented in this study.

Hasta Onamı: Çalışmada sunulan hastadan yazılı onam alınmıştır.

Conflict of Interest: No conflict of interest was declared by the authors.

Çıkar Çatışması: Yazarlar çıkar çatışması bildirmemişlerdir.

Financial Disclosure: The authors declared that this case has received no financial support.

Finansal Destek: Yazarlar bu olgu için finansal destek almadıklarını beyan etmişlerdir.

Geliş Tarihi / Received: 08.03.2018

Kabul Tarihi / Accepted: 03.04.2018

Yayın Tarihi / Published: 20.07.2018

Sorumlu yazar / Corresponding author:

Cihan Bedel

Antalya Training and Research Hospital, 07100,

Muratpaşa/Antalya, Turkey

Phone: 05075641254

e-mail: cihanbedel@hotmail.com

Copyright © ACEM

Introduction

Posttraumatic pulmonary pseudocyst (TPP) is a rare pulmonary lesion of the lung that can be seen after blunt or penetrating chest trauma. Young adults and children are most commonly impressed [1]. The clinical presentation is variable and ranges from asymptomatic to acute respiratory distress. Chest pain, dyspnea, cough, and hemoptysis are commonly reported [2]. Differential diagnosis of TPP includes lung abscess, bronchial cyst, post-inflammatory pneumatocele, tuberculosis, mycosis, herniation of the viscera, esophageal rupture, and neoplasm [3]. Chest computed tomography (CT) is important for early diagnosis [4]. Spontaneous remission is the usual outcome, but sometimes they can be complicated and surgical treatment is required [5].

We here report two cases of TPPs, which are rare cases, developed after blunt chest trauma due to traffic accident where conservative treatment contributed excellent outcomes.

Case reports

Case 1

A 26-year-old male was admitted to our hospital after a traffic accident. No characteristic feature was found in the patient's medical history. He was a smoker and often abused alcohol. The patient complained of right shoulder and right chest pain. On physical examination, he was hemodynamically stable and well perfused. Auscultation of the lungs revealed decreased respiratory sounds over the right hemithorax and painful right shoulder motions were noted.

The hemoglobin count was 13.1 g/dL; white blood cell count was $16.5 \times 10^3/\text{mm}^3$ and there was a mild increase in serum transaminase, creatine phosphokinase and lactic dehydrogenase activity. CT revealed bilateral pneumothorax, which was more prominent on the right side, lung contusion, and bilateral cavitory lesions particularly on the right side (Figure 1 a-b). A chest tube was placed in the right pleural cavity. He was treated with antibiotics (cephazoline sodium, Cefamezin, Eczacıbaşı, Istanbul, Turkey), postural drainage and analgesics. With this treatment, the patient improved with disappearance of pain and it disappeared completely in two weeks. The drain was removed on the 5th day and the control x-ray of the patient showed no complication. Follow-up radiographs also showed gradual improvement. Radiograph taken after three months of the treatment showed almost complete resolution of the lesions.

Written consent was taken from the patient.

Case 2

A 22-year-old male was admitted to our hospital after a traffic accident. No characteristic feature was found in the patient's medical history. He was mentally alert and physical examination revealed subcutaneous emphysema, tachypnea, and hemoptysis. Respiratory sounds were diminished over the left lung. Other systems were normal with the exception of the left femur fracture.

The hemoglobin count was 11.7 g/dL; white blood cell count was $13.6 \times 10^3/\text{mm}^3$ and other hematologic and biochemical findings were normal. Chest X-ray (Figure 2) and chest CT scanning (Figure 3a-b) revealed subcutaneous emphysema, multiple bilateral rib fractures, left hemopneumothorax, bilateral contusions and bilateral cavitory lesions particularly on the left side. The patient was treated by catheter aspiration and operation for his femur fracture was performed. He was treated with antibiotics (cephazoline sodium, Cefamezin®, Eczacıbaşı, Istanbul, Turkey and gentamicin sulphate, Genta® 80 mg, I.E. Ulagay, Istanbul, Turkey, postural drainage and analgesics. With this treatment, the patient improved with disappearance of pain and it was disappeared

completely in three weeks. Follow-up radiographs also showed gradual improvement. Radiograph taken after four months of the treatment showed almost complete resolution of the lesions.

Written consent was taken from the patient.

Figure 1 a-b: Computed tomography of the thorax revealed bilateral pneumothorax, lung contusion, and bilateral cavitory lesions particularly on the right side (axial and coronal view).

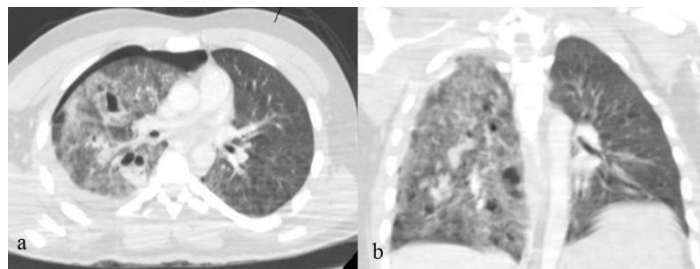


Figure 2: Chest radiograph shows subcutaneous emphysema and consolidation of the left lung.

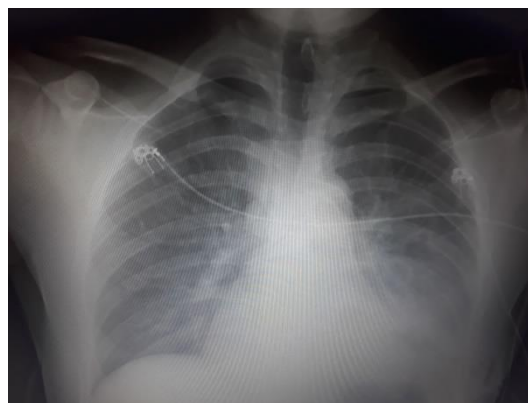
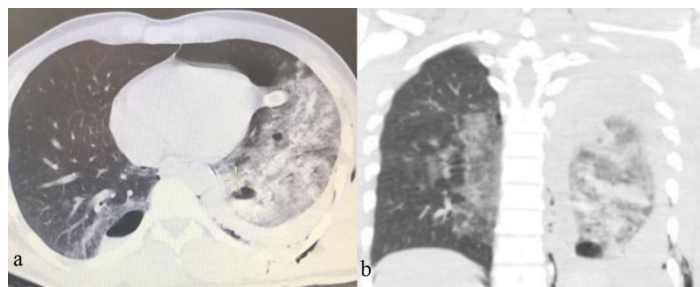


Figure 3 a-b: Computed tomography of the thorax revealed subcutaneous emphysema, multiple rib fractures, left hemopneumothorax, contusions and bilateral cavitory lesions (axial and coronal view).



Discussion

Traumatic pulmonary pseudocyst is a cavitory lesion that can be seen after thoracic trauma. These lesions are usually seen after blunt trauma; however, cases associated with penetrant trauma are rarely reported [6]. TPP constitutes of 2.9% of all parenchymal injuries of the lungs and males younger than 30 years of age enclose the majority of the affected patients [7]. This can be clarified by higher exposure to higher energy trauma like motor vehicle accidents in men or falls from a height.

The lesions result from blunt trauma causing local lacerations of the lung parenchyma. Elastic tapping allows air inlet. TPPs are more often seen in children and young adults because of greater adaptation of the chest wall leads to greater

force transmission to the parenchyma [8]. The current cases were also young male patients, consistent with these reports.

The etiology of TPP is usually associated with blunt thoracic trauma. Motor vehicle accidents and falls have been reported as the most common mechanisms of injury, but little is known about the prevalence of pseudocyst according to mechanism of injury [9]. In our cases, the lesions occurred after traffic accidents consistent with the literature.

Characteristic symptoms of TPPs are hemoptysis, chest pain, dyspnea, cough, and sometimes a small rise in temperature in the early days after the trauma. Mild leucocytosis may be present in blood analyses [8]. In our cases consistent with the literature, the patients presented with a complaint of chest pain and leukocytosis was seen.

Post-traumatic pulmonary pseudocysts may be diagnosed on the chest radiograph, but CT is superior for detecting them. Unlike other cystic and cavitary lesions, the size, shape, and nature of the wall of a post-traumatic pulmonary pseudocyst change relatively quickly, so a series of chest radiographs over several days can help differentiate pseudocyst from other lesions [10].

The differential diagnosis includes postinfectious pneumatocele, tuberculous or mycotic cavity, pulmonary abscess, cavitating carcinoma, cavitating or infected hematoma, and ruptured diaphragm with protrusion of bowel into the chest space. The history of trauma and the CT scan of the chest, usually are enough to confirm the diagnosis of pseudocyst [11].

TPPs are treated conservatively. Resolution of the lesion can be seen after six weeks; however, surgery can be required in certain circumstances. Progressively enlarging and infected lesions, abscessed cysts, and cysts that are associated with hemorrhage or rupture into the pleural cavity can require surgical intervention [12]. The mean time for spontaneous radiologic resolution has been reported within three months in TPPs [7]. In our cases, consistent with the literature, we treated conservatively.

In conclusion, TPP is a rare complication of blunt chest trauma. It usually resolves spontaneously but may require surgery. CT is more valuable than chest radiograph for early diagnosis. Prophylactic antibiotics may be indicated. Clinicians should conduct follow-up radiographs or CT scans until the pseudocyst resolves.

References

1. Yazkan R, Ozpolat B, Sahinalp S. Diagnosis and management of post-traumatic pulmonary pseudocyst. *Respir Care*. 2009;54:538-41.
2. Yang PJ, Tsai IT, Liu TH. Traumatic Pulmonary Pseudocyst. *J Pediatr*. 2015;167:777.e1.
3. Voutsas V, Giakamozis A, Lazaridis T, Bitzani M. Post-traumatic lung pseudocysts: two case reports in ICU patients. *J Thorac Dis*. 2012;4 Suppl 1:74-8.
4. Chon SH, Lee CB, Kim H, Chung WS, Kim YH. Diagnosis and prognosis of traumatic pulmonary pseudocysts: a review of 12 cases. *Eur J Cardiothorac Surg*. 2006;29:819-23.
5. Celik B, Basoglu A. Posttraumatic pulmonary pseudocyst: a rare complication of blunt chest trauma. *Thorac Cardiovasc Surg*. 2006;54:433-5.
6. Caylak H, Kavaklı K, Sapmaz E, Yücel O, Genç O. [Traumatic pulmonary pseudocyst: two case reports]. *Ulus Travma Acil Cerrahi Derg*. 2011;17:269-72. [Article in Turkish]
7. Kocer B, Gulbahar G, Gunal N, Dural K, Sakinci U. Traumatic pulmonary pseudocysts: two case reports. *J Med Case Rep*. 2007;1:112.
8. Papagiannis A, Gaziotis G, Anastasiadis K. Post-traumatic pulmonary pseudocyst: an unusual complication of blunt chest injury. *Pneumon*. 2005;18:228-32.
9. Cho HJ, Jeon YB, Ma DS, Lee JN, Chung M. Traumatic pulmonary pseudocysts after blunt chest trauma: Prevalence, mechanisms of injury, and computed tomography findings. *J Trauma Acute Care Surg*. 2015;79:425-30.

10. Tsitouridis I, Tsinoglou K, Tsandiridis C, Papastergiou C, Bintoudi A. Traumatic pulmonary pseudocysts: CT findings. *J Thorac Imaging*. 2007;22:247-51.