

Measurement of Kidney Dimensions by Ultrasonography and Investigation of the Incidence of Polycystic Kidney Disease in Van Cats

Muhammed Zeyd IŞIK¹
Cumali ÖZKAN¹



¹Van Yüzüncü Yıl University, Faculty of Veterinary Medicine, Department of Internal Medicine, Van, Türkiye



ABSTRACT

This study was conducted to measure kidney size in Van cats using ultrasonography and to investigate the incidence of polycystic kidney disease (PKD). The study's animal material consisted of 80 Van cats of different ages, genders, and eye colors. After performing general clinical examinations on the animals, measurements of the right and left kidneys (kidney length, height, width, volume, cortex length, medulla length, abdominal aorta, and RI) were taken using an ultrasound device. Ultrasound examinations conducted on Van cats of different ages, genders, and eye colors revealed that kidney size varied according to age group, but gender and eye color had no effect on kidney size. In kidney measurements performed on cats of different age groups, it was determined that the measurements in both the right and left kidneys showed statistically significant differences between groups. It was observed that these values generally increased from group 1 to group 4 (Group 1: <6 mounts; Group 2: ≥6-<12 mounts; Group 3: ≥12-<24 mounts; Group 4: ≥24 mounts) and that kidney size varied according to age. The findings were recorded. The right and left kidneys of the cats were examined using ultrasound to investigate whether they had PKD, and no cats were found to have PKD. In conclusion, this study was the first to investigate the determination of normal kidney size and the presence of PKD in Van cats using ultrasonography. None of the cats included in the study had PKD, and there were no differences in kidney size compared to other cat breeds.

Keywords: Kidney, kidney measurement, PKD ultrasonography, Van cat.

INTRODUCTION

Van cats are popular in Türkiye and worldwide due to their white fur and different eye colours.¹⁻⁴ In recent years, urinary tract diseases in cats have become increasingly common and have gained importance due to the difficulty and time required for diagnosis and treatment.⁵ Examinations are crucial in understanding the disease condition, size, structure and anatomical changes in the kidneys, which are organs in the urinary system.⁶ The ultrasonographic examination is one of the easiest and most practical.⁷⁻¹⁰ Changes in the kidneys and the detection of various diseases are possible with ultrasonographic examination.¹¹⁻¹³

Studies have measured kidney parameters such as kidney length, kidney width, kidney height, kidney cortex and medulla measurements, kidney RI measurement, and abdominal aortic diameter in cats during ultrasonographic evaluation. It has been reported that these parameters may vary depending on breed and gender. Kidneys typically measure 2-3 times the length of the second lumbar vertebra, varying by breed. Healthy kidneys in cats measure 3-4.5 long, 2.7-3.1 wide, and 2.0-3.5 cm thick.¹¹⁻¹⁴ Kidney cross-sectional area and volume are also assessed. The average kidney cross-sectional area is 4-6 cm² and volume 11.9-17.7 cm³.

*This research summarises the first author's master's thesis of the same name.

Received: 28.07.2025
Accepted: 19.01.2026
Publication Date: 28.04.2026

Corresponding author: Muhammed Zeyd Işık
E-mail: muhammedisik797@gmail.com

Cite this article: Işık MZ, Özkan C. Measurement of kidney dimensions by ultrasonography and investigation of the incidence of polycystic kidney disease in Van cats. *Vet Sci Prac.* 2026;21(1):1-9



Content of this journal is licensed under a Creative Commons Attribution-NonCommercial 4.0 International License.

Kidney size may vary depending on gender and sterilization status. Size is smaller in females compared to males, and larger in sterilized cats compared to unsterilized cats.^{5,11,12,15-17} A study on Iranian cats⁵ found the right kidney to be 4.16±0.30 cm long, 2.35±0.42 cm wide and 2.52±0.35 cm deep. The left kidney was 4.09±0.35 cm long, 2.41±0.52 cm wide and 2.65±0.04 cm deep. In another study,¹⁷ the kidney length in Ragdoll cats was found to be 3.83±0.45 cm, the kidney cortex 0.73±0.15 cm, and the kidney medulla 0.87±0.19 cm. The kidney length to abdominal aorta ratio is a method used to examine kidney size. Studies on healthy cats report an average aortic diameter to kidney ratio of 11.91±1.59, with an average K/AO ratio of 11.03–12.79.^{12,18,19}

PKD is a genetic disorder commonly found in Persian cats. It is also seen in other cat breeds, such as the Exotic Shorthair, Himalayan, British Shorthair, American Shorthair, Burmilla, Ragdoll, Maine Coon, Neva Masquerade and Chartreux.²⁰⁻²³ The disease is marked by the development of cysts of different sizes in the cortex and medulla of the kidneys.²⁴ Cysts are congenital and grow and develop as the patient ages. As aging causes cysts to increase and grow in size, kidney function gradually declines, eventually leading to chronic kidney failure.^{21,25,26} Although the disease has many symptoms and many diagnostic methods, detecting cysts in kidney tissue by ultrasound is the most practical, inexpensive, and non-invasive way to diagnose the disease.^{8,27} One or more round, anechoic cysts in the kidneys can diagnose the disease.^{19,28,29}

Studies show that PKD affects 38-47% of Persian cats worldwide and 6% of all cats.^{30,31} Ultrasonography has a 98% success rate in diagnosing PKD in 9-10 month-old cats, 91% in cats over 36 weeks, and 75% in cats under 16 weeks.³²

Research indicates that the homeland of Van cats is the foothills of the Altai Mountains and that they are believed to be related to neighboring cats (Iran, Pakistan, and Thailand).¹ Therefore, given that PKD is highly prevalent in Persian cats, that Persian cats are related to Van cats according to the literature, that no previous studies on this subject have been found in Van cats, we believe it is important to investigate and report the incidence of PKD in Van cats.

This study was conducted to evaluate different kidney measurements and to determine the incidence of PKD in Van cats.

MATERIALS AND METHODS

Study conducted in accordance with decision of Local Ethics

Vet Sci Pract. 2026;21(1):1-9. doi: 10.17094/vetsci.1752619

Committee for Animal Experiments, Van Yüzüncü Yıl University, 1 December 2022, no. 2022/13-01.

The study material consisted of 80 clinically healthy Van cats of different (<6 months; ≥6-<12 months; ≥12-<24 months; ≥24 months). The study sample consisted of 80 clinically healthy Van cats. The cats were grouped according to age (<6 months; ≥6-<12 months; ≥12-<24 months; ≥24 months), sex (male-female), and eye color (both eyes amber, both eyes blue, or one eye amber and one eye blue).

Animals were examined and prepared for ultrasound. They were placed in a lateral position and a window was created by shaving the caudal part of the last rib on the left and right sides. The left kidney was examined by placing the animal in a lateral position with the left kidney on top. Alcohol and gel were applied to the shaved area before the examination. The same procedure was repeated for the right kidney.

All animals in the study underwent ultrasound to check for PKD. Images of the kidneys were obtained and recorded using the VETUS-5 Mindray ultrasound device. The renal length, height, width, and medulla and cortex lengths were measured from these images. Additionally, the diameter of the abdominal aorta was calculated from the ultrasound images. For the RI, a diagram was obtained by applying PW Doppler to the renal interlobar arteries on the renal ultrasound image. RI measurements were then performed and recorded from this diagram.

Statistical Analyses

The statistical analyses of the study were performed using the SPSS (2013) statistical package program. Descriptive statistics are presented as mean and standard error. The Shapiro-Wilk test was used to determine whether the results showed a normal distribution, and all data showed a normal distribution. Duncan's multiple comparison test was used to determine the differences between the values of the study groups. In the study groups, the ANOVA test was used to compare the values obtained according to eye color, and the independent samples t-test was used to compare the values obtained for different genders. The relationship between the ultrasonographically measured kidney values was determined using Pearson correlation analysis. The statistical significance level was set at $P < .05$.

RESULTS

The ultrasound examinations of the cats in the study, divided into age groups, revealed no PKD findings.

Renal length, height, width, volume, cortex, medulla, aortic

diameter and RI values were determined for the right and left kidneys in different groups. See Table 1 for values, means, standard errors and intergroup statistical comparisons. Statistical comparisons between groups revealed some statistically significant differences in the measurements of kidney length, height, width, volume, cortex and medulla in the right and left kidneys. Values

generally increase from group 1 to group 4, but there is no statistically significant difference in the values between group 2-3 (except for the right kidney renal L), and changes in kidney size are observed according to age. No statistically significant changes were observed in aortic diameter and RI values in the right and left kidneys when comparing the groups.

Table 1. Right and left kidney USG measurements in different age groups.

Groups	Renal L (Mean±SEM)	Renal H (Mean±SEM)	Renal G (Mean±SEM)	Volume (Mean ±SEM)	Cortex (Mean±SEM)	Medulla (Mean±SEM)	Aortic Diameter (Mean ±SEM)	RI (Mean±SEM)	
Right Kidney	Group 1 (n:20)	3.00±0.08 ^d	1.81±0.04 ^c	2.26±0.05 ^c	6.07±0.29 ^c	0.42±0.02 ^c	0.41±0.01 ^c	0.40±0.01	0.54±0.01
	Group 2 (n:20)	3.48±0.06 ^c	2.06±0.02 ^b	2.52±0.05 ^b	8.84±0.20 ^b	0.48±0.02 ^b	0.49±0.02 ^b	0.41±0.01	0.56±0.01
	Group 3 (n:20)	3.68±0.07 ^b	2.07±0.03 ^b	2.60±0.05 ^b	9.73±0.37 ^b	0.48±0.01 ^b	0.48±0.02 ^b	0.43±0.01	0.54±0.01
	Group 4 (n:20)	4.15±0.07 ^a	2.38±0.06 ^a	2.83±0.05 ^a	13.78±0.60 ^a	0.61±0.03 ^a	0.59±0.02 ^a	0.40±0.01	0.54 ±0.01
	<i>P</i>	.000	.000	.000	.000	.000	.000	.051	.280
Left Kidney	Group 1 (n:20)	2.99±0.08 ^c	1.76±0.05 ^c	2.28±0.04 ^c	5.91±0.29 ^c	0.41±0.01 ^c	0.43±0.01 ^c	0.41±0.01	0.52 ±0.01
	Group 2 (n:20)	3.44±0.05 ^b	2.09±0.05 ^b	2.49±0.04 ^b	8.79±0.32 ^b	0.51±0.02 ^b	0.50±0.02 ^b	0.43±0.00	0.55±0.01
	Group 3 (n:20)	3.63±0.07 ^b	2.11±0.05 ^b	2.57±0.04 ^b	9.73±0.36 ^b	0.51±0.02 ^b	0.51±0.02 ^b	0.41±0.01	0.57±0.01
	Group 4 (n:20)	4.17±0.07 ^a	2.47±0.06 ^a	2.75±0.06 ^a	13.88±0.59 ^a	0.60±0.02 ^a	0.60±0.02 ^a	0.40±0.01	0.55±0.01
	<i>P</i>	.000	.000	.000	.000	.000	.000	.260	.050

Note: Renal L: Renal longitudinal length, Renal H: Renal height, Renal G: Renal width, RI: Resistive index, (Mean±SEM): Standard Error of Mean, n:number, ^{a,b,c,d}: Shows if the values in the columns are similar or different.

Table 2, 3 present the arithmetic means, standard error values, and intra-group statistical comparisons according to gender for kidney length, kidney height, kidney width, kidney volume, kidney cortex, kidney medulla, aortic diameter, and RI values. Although some numerical differences were detected in the measurements obtained from the right and left kidneys of the male and female cats in the group, no statistically significant changes were observed. The values obtained for the cats in the study were

compared based on their eye colour. The arithmetic means, standard error values and intra-group statistical comparisons according to gender for the kidney measurement values of Van cats with different eye colours are presented in Tables 4, 5. These values include kidney length, height, width, volume, cortex, medulla, aorta diameter and RI. Examining the tables showed no statistically significant differences in kidney measurements between cats with different eye colours.

Table 2. Changes in right kidney USG measurements of different age groups according to gender.

Groups	Gender	Renal L (Mean±SEM)	Renal H (Mean±SEM)	Renal G (Mean±SEM)	Volume (Mean ±SEM)	Cortex (Mean±SEM)	Medulla (Mean±SEM)	Aortic Diameter (Mean ±SEM)	RI (Mean±SEM)
Group 1	Female (n:10)	2.98±0.15	1.75±0.03	2.26±0.09	5.83±0.54	0.39±0.02	0.39±0.02	0.40±0.01	0.53±0.01
	Male (n:10)	3.02±0.06	1.88±0.06	2.25±0.07	6.31±0.25	0.45±0.03	0.42±0.02	0.40±0.01	0.55±0.02
	<i>P</i>	.809	.087	.960	.444	.136	.415	1.000	.466
Group 2	Female (n:12)	3.49±0.07	2.07±0.04	2.49±0.06	8.79±0.31	0.49±0.02	0.48±0.01	0.41±0.01	0.56±0.01
	Male (n:8)	3.47±0.11	2.06±0.03	2.56±0.07	8.91±0.24	0.47±0.03	0.50±0.04	0.42±0.01	0.56±0.01
	<i>P</i>	.878	.889	.531	.776	.553	.496	.894	1.000
Group 3	Female (n:12)	3.73±0.10	2.05±0.04	2.67±0.05	10.04±0.47	0.48±0.02	0.50±0.03	0.42±0.02	0.55±0.01
	Male (n:8)	3.61±0.06	2.10±0.06	2.48±0.06	9.26±0.59	0.49±0.02	0.45±0.03	0.46±0.00	0.53±0.01
	<i>P</i>	.416	.525	.032	.323	.778	.278	.074	.249
Group 4	Female (n:8)	3.91±0.15	2.24±0.14	2.92±0.03	12.65±1.13	0.54±0.02	0.54±0.01	0.40±0.01	0.53±0.02
	Male (n:12)	4.25±0.05	2.44±0.05	2.79±0.06	14.26±0.67	0.63±0.03	0.61±0.03	0.40±0.01	0.55±0.01
	<i>P</i>	.023	.126	.244	.236	.128	.129	.840	.479

Note: Renal L: Renal longitudinal length, Renal H: Renal height, Renal G: Renal width, RI: Resistive index, (Mean±SEM): Standard Error of Mean, n: number

Table 3. Changes in left kidney USG measurements of different age groups according to gender.

Groups	Gender	Renal L (Mean±SEM)	Renal H (Mean±SEM)	Renal G (Mean±SEM)	Volume (Mean ±SEM)	Cortex (Mean±SEM)	Medulla (Mean±SEM)	Aortic Diameter (Mean ±SEM)	RI (Mean±SEM)
Group 1	Female (n:10)	2.96±0.16	1.77±0.09	2.21 ±0.05	5.76±0.61	0.41±0.01	0.41±0.01	0.41±0.02	0.52±0.01
	Male (n:10)	3.02±0.06	1.74±0.04	2.35 ±0.03	6.06±0.03	0.40±0.02	0.44±0.02	0.41±0.01	0.52±0.02
	<i>P</i>	.733	.733	.801	.046	.640	.643	.373	.924
Group 2	Female (n:12)	3.43±0.08	2.13±0.08	2.50 ±0.06	9.04±0.50	0.50±0.03	0.49±0.03	0.43±0.01	0.55±0.02
	Male (n:8)	3.45±0.07	2.03±0.02	2.47 ±0.05	8.43±0.23	0.51±0.03	0.51±0.03	0.43±0.01	0.54±0.01
	<i>P</i>	.874	.874	.314	.701	.376	.832	.636	.881
Group 3	Female (n:12)	3.68±0.11	2.12±0.07	2.59 ±0.06	10.03±0.50	0.51±0.03	0.50±0.03	0.41±0.02	0.57±0.02
	Male (n:8)	3.57±0.05	2.10±0.04	2.53 ±0.06	9.29±0.48	0.51±0.02	0.52±0.02	0.41±0.01	0.57±0.01
	<i>P</i>	.472	.472	.840	.493	.338	.967	.644	.859
Group 4	Female (n:8)	3.97±0.13	2.34±0.11	2.76 ±0.17	12.53±0.85	0.54±0.02	0.58±0.04	0.41±0.01	0.53±0.02
	Male (n:12)	4.25±0.07	2.52±0.06	2.74 ±0.05	14.46±0.67	0.62±0.03	0.61±0.03	0.40±0.01	0.56±0.01
	<i>P</i>	.070	.070	.142	.881	.141	.106	.522	.530

Note: Renal L: Renal longitudinal length, Renal H: Renal height, Renal G: Renal width, RI: Resistive index, (Mean±SEM): Standard Error of Mean, n: number.

Table 4. Evaluation of right kidney USG measurements of different age groups according to eye color.

Groups	Eye Color	Renal L (Mean±SEM)	Renal H (Mean±SEM)	Renal G (Mean±SEM)	Volume (Mean ±SEM)	Cortex (Mean±SEM)	Medulla (Mean±SEM)	Aortic Diameter (Mean ±SEM)	RI (Mean±SEM)
Group 1	Blue (n:8)	2.94±0.18	1.74±0.03	2.25±0.12	5.69±0.67	0.38±0.02	0.39±0.03	0.41±0.01	0.52±0.01 ^b
	Amber (n:4)	3.06±0.02	1.77±0.03	2.32±0.00	6.14±0.11	0.41±0.01	0.40±0.03	0.40±0.01	0.59±0.01 ^a
	Single Eye (n:8)	3.03±0.09	1.92±0.07	2.24±0.08	6.42±0.31	0.46±0.03	0.43±0.01	0.40± 0.02	0.53±0.01 ^b
	<i>P</i>	.825	.082	.872	.592	.092	.472	.900	.011
Group 2	Blue (n:10)	3.49±0.10	2.07±0.03	2.54±0.07	8.97±0.19	0.47±0.03	0.48±0.03	0.41±0.01	0.55±0.01
	Amber (n:6)	3.48±0.12	2.06±0.05	2.47±0.11	8.70±0.65	0.49±0.01	0.52±0.02	0.41±0.02	0.56±0.00
	Single Eye (n:4)	3.44±0.14	2.04±0.10	2.54±0.10	8.71±0.26	0.50±0.05	0.45±0.02	0.42±0.02	0.59±0.01
	<i>P</i>	.949	.916	.804	.831	.823	.357	.860	.058
Group 3	Blue (n:6)	3.49±0.10	1.99±0.06	2.51±0.08	8.58±0.49	0.47±0.01	0.43±0.02	0.41±0.01	0.53±0.02
	Amber (n:4)	3.67±0.04	2.10±0.02	2.76±0.05	10.45±0.43	0.50±0.04	0.52±0.04	0.38±0.01	0.54±0.01
	Single Eye (n:10)	3.80±0.08	2.11±0.05	2.58±0.06	10.13±0.48	0.48±0.02	0.49±0.03	0.45±0.01	0.55±0.01
	<i>P</i>	.114	.338	.193	.102	.843	.227	.043	.621
Group 4	Blue (n:8)	4.14±0.14	2.43±0.09	2.95±0.04	14.57±0.94	0.61±0.04	0.60±0.03	0.40±0.00	0.56±0.01
	Amber (n:4)	4.15±0.04	2.29±0.14	2.70±0.12	12.59±1.47	0.56±0.09	0.54±0.08	0.41±0.01	0.55±0.02
	Single Eye (n:8)	4.16±0.14	2.39±0.11	2.79±0.07	13.58±1.00	0.63±0.04	0.61±0.03	0.40±0.02	0.53±0.02
	<i>P</i>	.997	.755	.107	.520	.697	.475	.766	.452

Note: Renal L: Renal longitudinal length, Renal H: Renal height, Renal G: Renal width, RI: Resistive index, (Mean±SEM): Standard Error of Mean, n: number, Single Eye: One eye blue, one eye amber. ^a^b: indicates whether the values in the columns are statistically similar or different from each other.

Table 5. Evaluation of left kidney USG measurements of different age groups according to eye color.

Groups	Eye Color	Renal L (Mean±SEM)	Renal H (Mean±SEM)	Renal G (Mean±SEM)	Volume (Mean ±SEM)	Cortex (Mean±SEM)	Medulla (Mean±SEM)	Aortic Diameter (Mean ±SEM)	RI (Mean±SEM)
Group 1	Blue (n:8)	2.93±0.21	1.77±0.12	2.18±0.05	5.64±0.77	0.41±0.02	0.44±0.03	0.41±0.02	0.51±0.01
	Amber (n:4)	3.03±0.03	1.74±0.06	2.35±0.10	6.04±0.02	0.41±0.03	0.40±0.02	0.41±0.03	0.54±0.03
	Single Eye (n:8)	3.04±0.09	1.76±0.05	2.35±0.01	6.13±0.05	0.41±0.02	0.43±0.02	0.42±0.01	0.53±0.02
	<i>P</i>	.847	.982	.063	.784	.955	.693	.952	.320
Group 2	Blue (n:10)	3.44±0.05	2.15±0.09	2.53±0.06	9.19±0.53	0.54±0.03	0.51±0.02	0.43±0.01	0.54±0.01
	Amber (n:6)	3.40±0.15	2.01±0.03	2.46±0.08	8.26±0.53	0.47±0.02	0.48±0.04	0.43±0.00	0.56±0.04
	Single Eye (n:4)	3.50±0.14	2.07±0.08	2.41±0.03	8.62±0.01	0.47±0.04	0.48±0.04	0.42±0.02	0.53±0.01
	<i>P</i>	.852	.555	.460	.484	.207	.668	.499	.674
Group 3	Blue (n:6)	3.48±0.12	1.96±0.08	2.55±0.11	9.15±0.45	0.46±0.02	0.48±0.03	0.41±0.00	0.55±0.01
	Amber (n:4)	3.81±0.01	2.18±0.02	2.59±0.13	10.53±0.39	0.54±0.02	0.54±0.05	0.38±0.02	0.63±0.06
	Single Eye (n:10)	3.66±0.10	2.17±0.05	2.57±0.05	10.15±0.43	0.53±0.03	0.51±0.03	0.43±0.02	0.56±0.02
	<i>P</i>	.244	.092	.973	.047	.211	.671	.192	.163
Group 4	Blue (n:8)	4.13±0.10	2.57±0.07	2.72±0.08	14.18±1.05	0.61±0.03	0.62±0.04	0.39±0.01	0.53±0.01
	Amber (n:4)	4.14±0.11	2.41±0.10	2.59±0.11	12.73±1.32	0.56±0.04	0.55±0.09	0.39±0.01	0.54±0.04
	Single Eye (n:8)	4.22±0.16	2.40±0.11	2.86±0.08	14.16±0.95	0.60±0.04	0.61±0.03	0.42±0.01	0.57±0.01
	<i>P</i>	.860	.384	.216	.672	.735	.514	.074	.253

Note: Renal L: Renal longitudinal length, Renal H: Renal height, Renal G: Renal width, RI: Resistive index, (Mean±SEM): Standard Error of Mean, n: number, Single Eye: One eye blue, one eye amber.

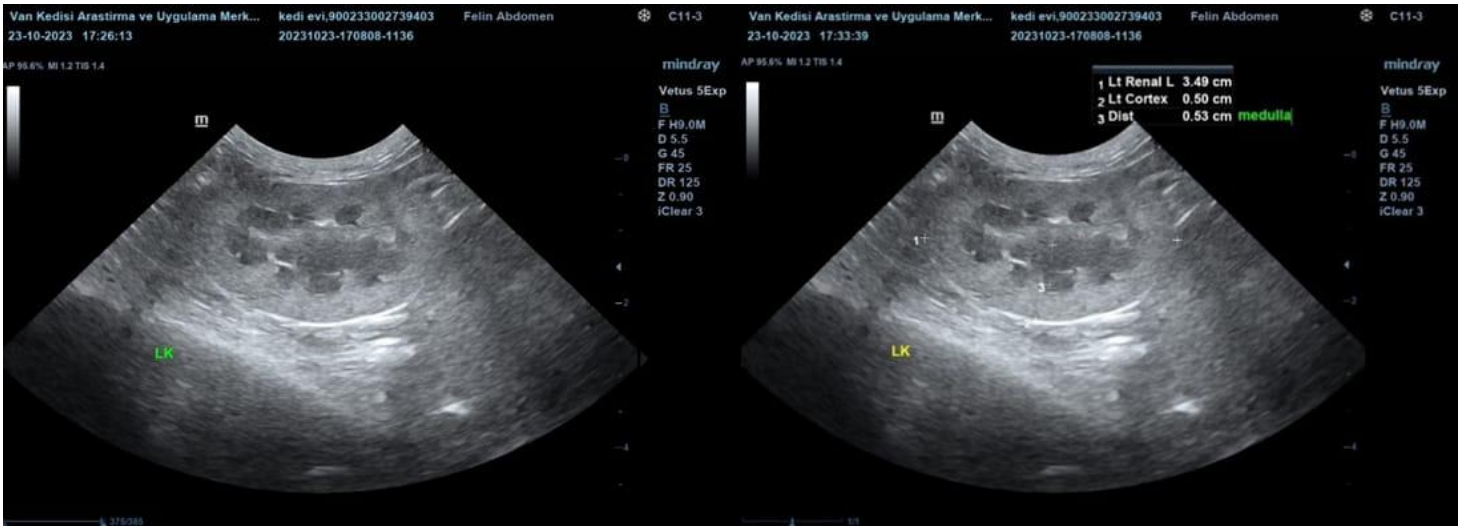


Figure 1. Ultrasonographic longitudinal image and measurements of the left kidney.

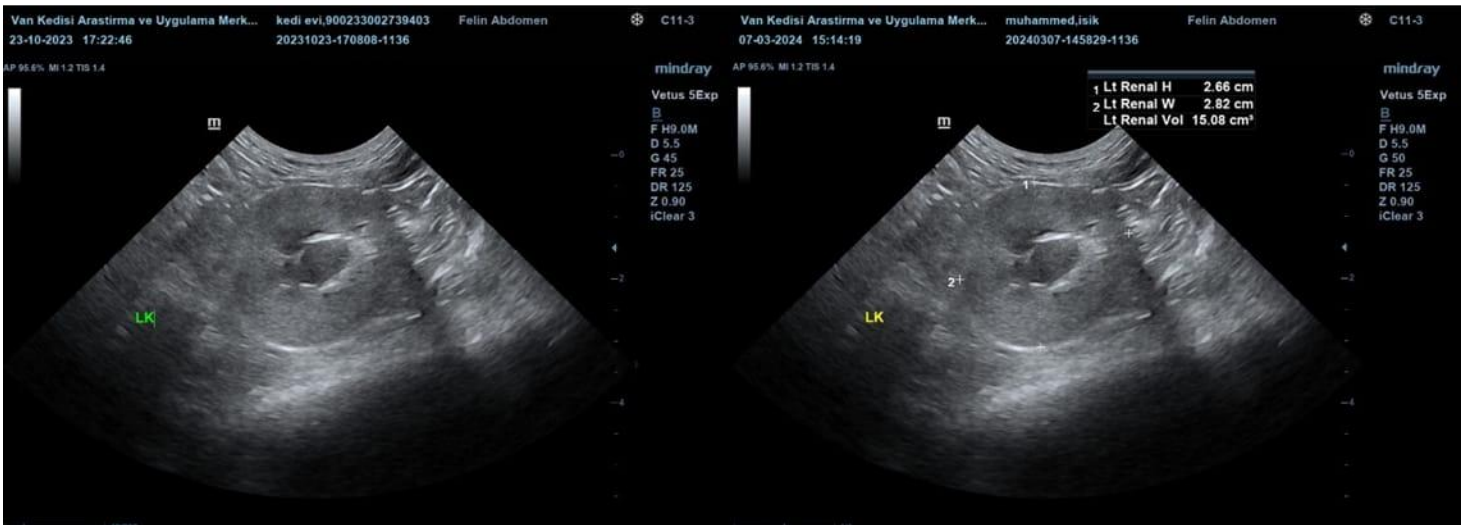


Figure 2. Ultrasonographic transverse image and measurements of the left kidney.

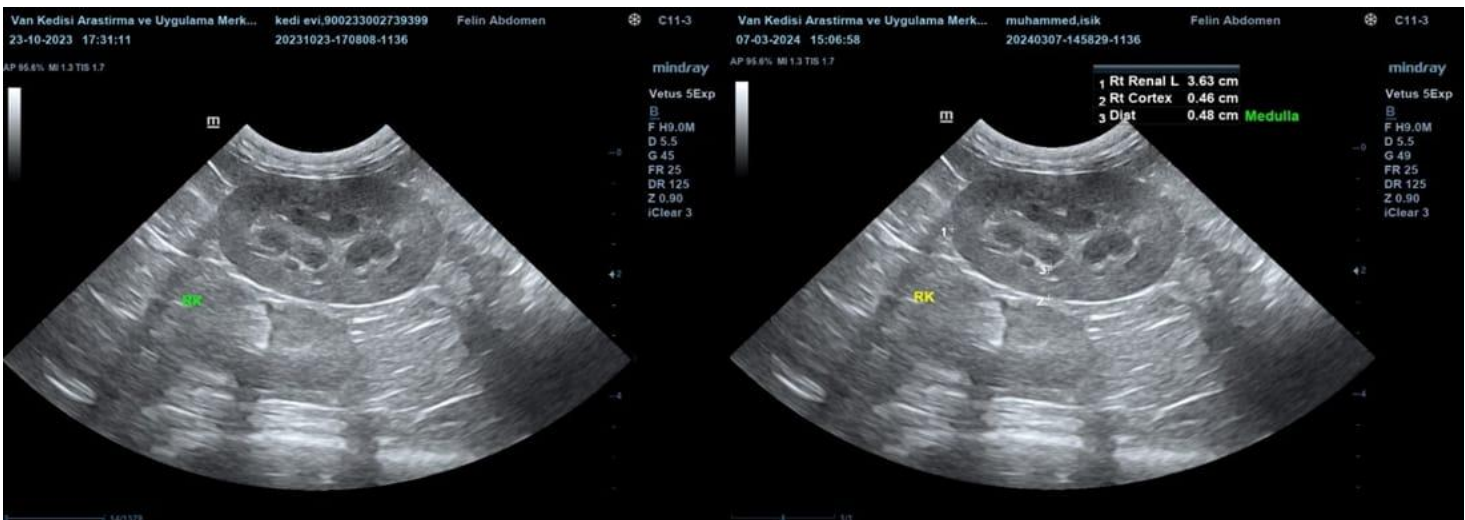


Figure 3. Ultrasonographic longitudinal image and measurements of the right kidney.

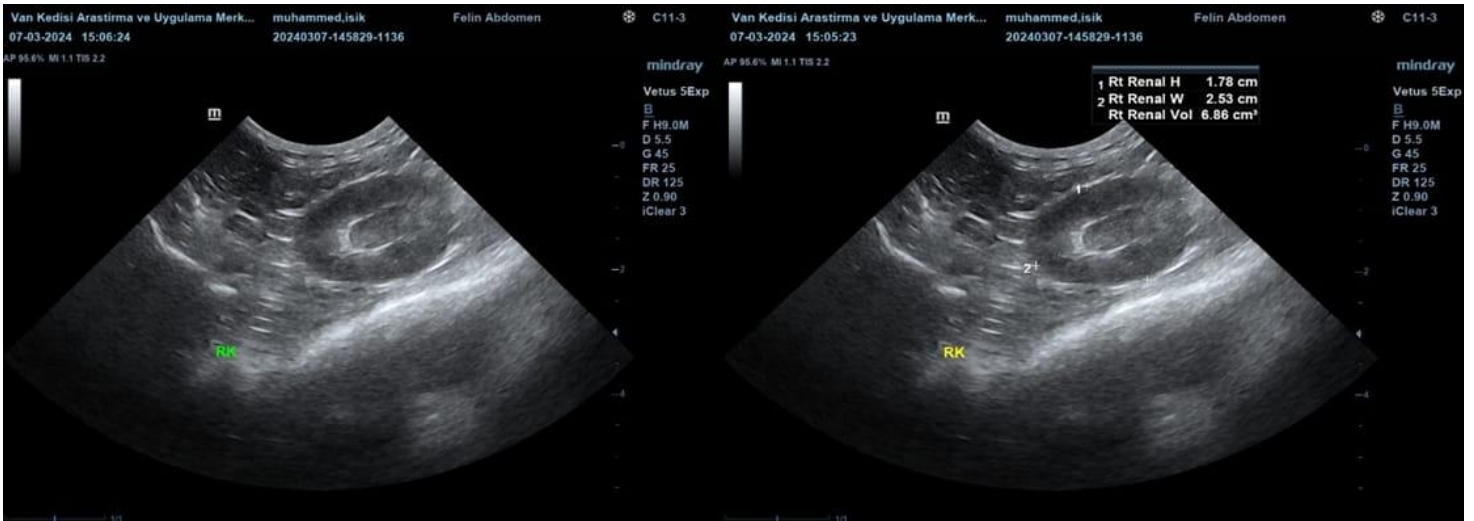


Figure 4. Ultrasonographic transverse image and measurements of the right kidney.

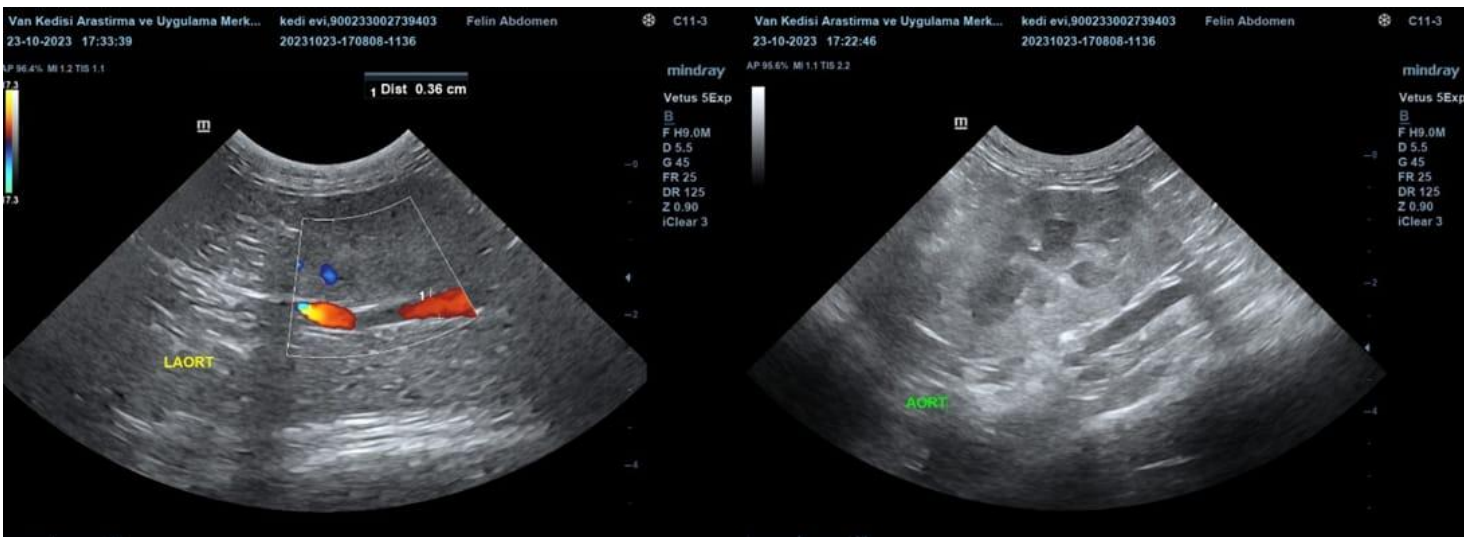


Figure 5. Ultrasonographic image and measurement of the abdominal aorta.

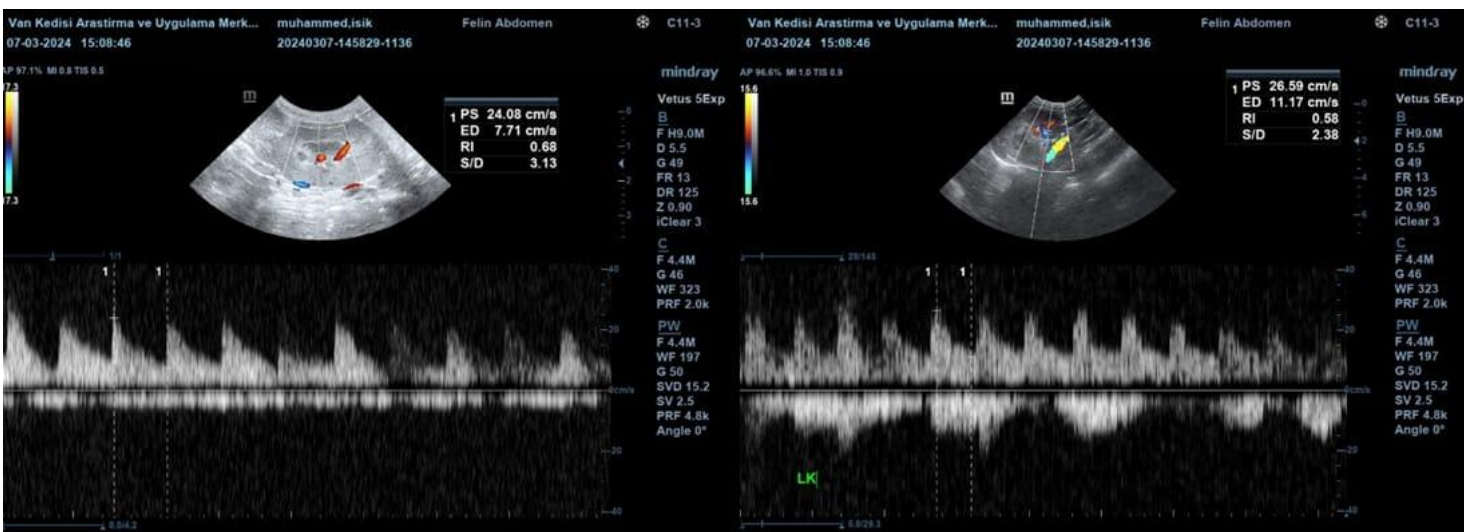


Figure 6. Ultrasonographic image and measurement of the RI

DISCUSSION

The study was conducted on Van cats divided into age, gender and eye colour groups. The aim was to measure normal kidney sizes using ultrasound and to investigate the presence of PKD. In recent years, there has been a significant increase in the incidence of urinary system diseases, and the difficulty and length of treatment has increased the importance of these diseases. In the diagnosis of urinary system diseases, painless, non-invasive, and direct ultrasound imaging has recently begun to be used frequently⁵. An ultrasound can provide important information about any abnormalities in the urinary system.¹² Knowing the normal dimensions of the organs is crucial in determining whether there is any pathological condition.^{17,33} Studies have been conducted to determine normal kidney sizes in cats using ultrasound.^{5,17,33} Widmer³⁴ reported that the kidney length was 3.66 ± 0.46 cm, height 2.21 ± 0.28 cm, width 2.53 ± 0.30 cm, and volume $11.9\text{--}17.7$ cm³. Çayır⁵ kidney lengths were 4.16 ± 0.30 cm for the right kidney, 4.09 ± 0.35 cm for the left kidney, kidney height was 2.52 ± 0.43 cm for the right kidney and 2.65 ± 0.43 cm for the left kidney, kidney width was 2.35 ± 0.42 cm for the right kidney and 2.41 ± 0.52 cm for the left kidney, while the kidney volumes were 13.43 ± 5.2 cm³ for the right kidney and 14.41 ± 6.8 cm³ for the left kidney. Alkan¹⁵ determined that the right kidney measured 3.0–5.5 cm, the left kidney 3.0–5.1 cm and the right kidney's width was between 1.5 and 3.0 cm, the left kidney between 1.5 and 2.9 cm. Debruyne et al.¹¹ reported that kidney length ranges from 3.0 to 4.3 cm, but can reach up to 5.3 cm. Canpolat³⁵ reported the length of the right kidney was 3.4 ± 0.4 cm, the width 2.4 ± 0.2 cm, and the height 2.1 ± 0.4 cm.

Table 1 presents the kidney measurement values of Van cats in different age groups. Statistical comparisons between groups in our study revealed differences in measurements of kidney length, height, width, volume, cortex and medulla. It was determined that these values generally increased from group 1 to group 4, with kidney size varying according to age. We believe that these statistically significant differences observed between groups are proportional to the increase in body mass index associated with the animals ages. The values determined by USG in our study are similar to the values reported in studies conducted on other cat breeds^{5,11,15,34,35} and the findings are parallel.

Debruyne et al.¹¹ determined that the renal cortex was 0.82 ± 0.14 cm and the renal medulla was 0.59 ± 0.06 cm. Park et al.³⁶ found that the left kidney cortex measured 0.47 ± 0.08 cm and the right kidney cortex measured 0.47 ± 0.08 cm, while the left kidney medulla measured 0.55 ± 0.30 cm and the right kidney medulla measured

0.50 ± 0.07 cm. The measurement values obtained in our study are presented in Table 1 (Figures 1-4). Upon examination of Table 1, it was determined that in the statistical comparisons between groups in the right and left kidneys, the measurements of the cortex and medulla were not statistically different in groups 2 and 3, while there were statistical differences between the other groups. These differences are thought to stem from variations in age and body mass ratios between the different animal groups. When we compare our study with the above-mentioned studies^{1,11,36} we can conclude that the values obtained are similar. Debruyne et al.¹¹ found that kidney size differs by sex and sterilisation status: female cats have smaller kidneys than male cats, and sterilised cats have larger kidneys than unsterilised cats. Çayır⁵ stated that there was no statistical difference in the ultrasonographic examination of female and male cat kidneys. Our study found no statistically significant differences in measurements between male and female cats in the group (Tables 2 and 3). Our findings are consistent with those in Çayır⁵, but inconsistent with those in Debruyne et al.¹¹. Our study found no statistically significant differences in kidney measurements between cats with different eye colours (Tables 4, 5). This shows that kidney ultrasound measurements are not affected by eye colour.

Recently, it has been reported that aortic diameter is also used in kidney size examinations. Studies conducted on cats are insufficient due to the lack of size/weight differences between breeds.¹⁸ However, Jaturanratsamee et al.¹⁸ reported that the normal range for abdominal aortic diameter in cats is 0.30-0.33 cm. In our study, the abdominal aorta diameter in Van cats was found to be between 0.41 and 0.43 cm (Table 1, Figure 5). In Van cats, there were no statistically significant differences in aortic diameter between the right and left kidneys in intergroup comparisons, and the values were consistent with those reported in other studies.¹⁸

RI is used to diagnose urinary system diseases. An increase in this value indicates disease severity.^{33,37} Cats RI values are 0.59 ± 0.05 for the right kidney and 0.56 ± 0.06 for the left, with a maximum RI of 0.70.^{33,37,38} Tipisca et al.³³ reported that RI values in cats were 0.54 ± 0.07 on the right and 0.59 ± 0.08 on the left. Ostrowska et al.³⁹ found an RI value of 0.60 ± 0.05 for the right kidney and 0.61 ± 0.05 for the left. River et al.⁴⁰ reported normal values of 0.59 ± 0.05 for the right kidney and 0.56 ± 0.05 for the left.

RI in Van cats was between 0.54 and 0.56 for the right kidney and between 0.52 and 0.57 for the left. There was no significant difference between right and left kidney RI measurements. The RI values obtained in this study are

consistent with the normal values obtained in various studies^{33,36-41} in animals (Table 1, Figure 6), and there are no statistically significant differences between the groups in the right and left kidneys.

PKD is a genetic disease common in Persian cats. It is also reported in Exotic Shorthair, Himalayan, British Shorthair, American Shorthair, Burmilla, Ragdoll, Maine Coon, Neva Masquerade and Chartreux.^{21,30,40} Studies show PKD affects 38-47% of Iranian cats worldwide.³¹ The disease is a dominant genetic disorder, so it can occur in cats bred with Persian cats, increasing the incidence rate.²⁰ Beck and Lavelle's report²⁸ on PKD in cats found the disease most prevalent (45%) in Persian cats, followed by Exotic Shorthairs at 50%. Barthez et al.⁴² found that 128 (41.8%) of 220 Persian cats and 39 (39.1%) of 64 Exotic Shorthair cats tested positive for PKD, while no signs of the disease were found in the other cats. Cannon et al.⁴³ reported a 49% PKD prevalence in cats. Bonazzi et al.³⁰ detected PKD in 29 cats during ultrasound examinations, giving a prevalence rate of 41.4%.

There have been numerous PKD studies and the incidence is higher in Persian cats and cat breeds that interbreed with Persian cats.^{28,30,31,42,43} Research on Van cats shows they are from the city of Buhtamara at the foot of the Altai Mountains and may be related to other cat breeds in nearby regions (Iran, Pakistan, and Thailand).¹ PKD, which is common in Persian cats, has not been studied in Van cats, which are thought to be similar.

Detailed ultrasound examinations of Van cats revealed that none of them had PKD. This finding suggests that PKD is uncommon in Van cats, which are believed to be related to Persian cats. The fact that the Van cats used in the study were obtained from the Van Cat Research and Application Centre at Van Yüzüncü Yıl University, where purebred breeding efforts have been ongoing for years; that the cats are purebred Van cats; and that they have not been crossbred with any other breed may have contributed to our failure to encounter the disease.

In conclusion, PKD was investigated in Van cats using ultrasonography. It was determined that the disease was not found in Van cats and that its incidence was very low. This study also determined normal kidney sizes in Van cats by ultrasonographic examination according to age, gender, and eye colour. It was concluded that kidney size increases with age, but not gender or eye colour, which will be helpful for future studies.

for Animal Experiments, the study doesn't need their approval.

Peer-reviewed: External peer-reviewed

Author Contributions: Concept- MZI, CÖ; Design- MZI, CÖ; Supervision- CÖ; Resources- MZI; Materials- MZI, CÖ; Data Collection and/or Processing- MZI, CÖ; Analysis and/or Interpretation- MZI, CÖ; Literature Search- MZI; Writing Manuscript- MZI; Critical Review- MZI, CÖ

Declaration of Interest: The authors declare no conflict of interest

Conflict of Interest: The authors have no conflicts of interest to declare.

Funding: This study received no financial support.

Use of Artificial Intelligence: Artificial intelligence was not used in this study.

REFERENCES

- Eroğlu T. Türkiye'deki Bazı Kedi Irklarının Genetik Yapılarının Mikrosatellitlerle İncelenmesi. Yüksek Lisans Tezi. Konya Selçuk Üniversitesi; 2007.
- Özkan C, Karaca M, Özdal N. Topical selamectin treatment of otodectes cynotis in Van cats. *Türkiye Parazitoloj Derg.* 2013;37:269-272.
- Bilgiç B, Özkan C, Moscati L, et al. Redox balance in Van cats and it's association with age, gender and eye color. *J Hellenic Vet Med Soc.* 2024;75(2):7301-7308.
- Karadağ S. Türkiye'nin yerel ırklarından Ankara ve Van kedilerinin ırk özellikleri. *Manas J Agric Vet Life Sci.* 2025;15(1):161-166.
- Çayır N. Kedilerde Farklı Görüntüleme Yöntemleri ile Böbreklerin Morfolojik İncelenmesi. Yüksek Lisans Tezi. Aydın Adnan Menderes Üniversitesi; 2008.
- Şındak N, Şelçukbiricik H. Köpeklerin karın içi organ hastalıklarının ultrasonografi ile değerlendirilmesi. *Van Vet J.* 2006;17(1-2):75-79.
- Şirin ÖŞ, Fidan M, Bumin A. Acil veteriner hekimliğinde ultrasonografik muayene yöntemleri. *Erciyes Üniv Vet Fak Derg.* 2021;18(1):57-61.
- Canooğlu E. Kedilerde Meme Bezinin Ultrasonografik Muayenesi. Çelik HA, editör. Evcil Hayvanlarda Meme Sağlığı ve Hastalıklarında Ultrasonografinin Yeri ve Önemi. Ankara: Türkiye Klinikleri Yayınevi;2024;10(1):40-46.
- Silva CEF, Foncesa MAFS, Borges GS, Costa DV, Lopes MM, Öliiverira LM. Gastrointestinal ultrasound in dogs: scientometric analysis. *Adv Res.* 2024;25(6):21-28.
- Şen Y, Turan E. Basic ultrasonography. *Türkiye Klinikleri J Vet Sci.* 2025;11(1):49-53.
- Debruyen K, Haers H, Combes A, et al. Ultrasonography of the feline kidney: technique, anatomy and changes associated with disease. *J Feline Med Surg.* 2012;14:794-803.
- Kaymaz AA, Bayrakal A. Üriner Sistem Ultrasonografisi. Bayrakal A, İskefli O, editörler. Kedi ve Köpeklerde Temel Ultrasonografi ve Ekokardiyografi. Ankara: Güneş Tıp Kitabevi; 2021:195-221.
- Bayrakal A, İskefli O. Böbrekler ve Üreterler. Bayrakal A,

Ethics Committee Approval: As stated in the 01/12/22 letter (no. 2022/13-01) from Van Yüzüncü Yıl University's Local Ethics Committee

Vet Sci Pract. 2026;21(1):1-9. doi: 10.17094/vetsci.1752619

- iskefli O, editörler. Uygulamalı Küçük Hayvan Ultrasonografisi. Ankara: Güneş Tıp Kitabevi; 2024:81-90.
14. Turgut K. Veteriner Klinik Laboratuvar Teşhis. 2. Baskı. Ankara, Bahçivanlar Basım Sanayi AŞ; 2000.
15. Alkan Z. Kedilerde böbreklerin ultrasonografik anatomisi. *Kafkas Üniv Vet Fak Derg.* 1995;1(1):42-46.
16. Clorkson CE, Flecher TF. Anatomy and physiology. Bartges J, Polzin JD, eds. Nephrology and Urology of Small Animals. New Delhi India: Wiley-Blackwell Publishing;2011:3-10.
17. Debruyne K, Paepa D, Daminet S, et al. Renal dimensions at ultrasonography in healthy Ragdoll cats with normal kidney morphology: Correlation with age, gender and bodyweight. *J Feline Med Surg.* 2013;15(12):1046-1051.
18. Jaturanratsamee K, Choisirachon N, Soontornvipart K, Darawiroj D, Srisowanna N, Thanaboornipat C. Ultrasonographic kidney length-to-abdominal aortic diameter for the diagnosis of feline chronic kidney disease: A preliminary study. *Vet World.* 2023;16(5):1114-1121.
19. Anjou MA, Penninck D. Kidneys and ureters. Anjou MA, Penninck D, eds. Atlas of Small Animal Ultrasonography. USA: Blackwell Publishing; 2013:331-360.
20. Nivy R, Lyons AL, Aroch I, Segev G. Polycystic kidney disease in four British shorthair cats with successful treatment of bacterial cyst infection. *J Small Anim Pract.* 2015;56:585-589.
21. Schirrer L, Marin-Garcia JP, Llobat L. Feline polycystic kidney disease: An update. *Vet Sci.* 2021;8:269.
22. Wozzuk JN, Sobczak M, Sawicz Z, et al. First report on the presence of a common pathogenic variant in the PKD1 gene, causing polycystic kidney disease, in a series of related Sphynx cats. *Top Compain Anim Med.* 2024;63:100928.
23. Saberi N, Khaksar E, Molazem M, Rafiee SM. Cardiovascular changes in Persian cats with polycystic kidney disease: a study of cardiac troponin I, echocardiography and blood pressure. *J Feline Med Surg.* 2025;27(1):1-7.
24. Griffin S. Feline abdominal ultrasonography: What's normal? What's abnormal? The kidneys and perinephric space. *J Feline Med Surg.* 2020;22:409-427.
25. Reichle KJ, Dibartola PS, Leveille R. Renal ultrasonographic and computed tomographic appearance, volume, and function of cats with autosomal dominant polycystic kidney disease. *Vet Radiol Ultrasound.* 2002;43(4):368-373.
26. Lee YJ, Chen HY, Hsu WL, Ou CM, Wong ML. Diagnosis of feline polycystic kidney disease by a combination of ultrasonographic examination and PKD1 gene analysis. *Vet Rec.* 2010;167:614-617.
27. Gabow PA. Autosomal dominant polycystic kidney disease: More than a renal disease. *Am J Kidney Dis.* 1990;16(5):403-413.
28. Beck C, Lavelle RB. Feline polycystic kidney disease in Persian and other cats: A prospective study using ultrasonography. *Aust Vet J.* 2001;79(3):181-184.
29. Tümer K, İssi M. Chronic renal failure associated with polycystic kidney disease in a Persian cat. *F Ü Sağ Bil Vet Derg.* 2017;31(3):265-267.
30. Bonazzi M, Volta A, Gnudi G, et al. Comparison between ultrasound and genetic testing for the early diagnosis of polycystic kidney disease in Persian and Exotic Shorthair cats. *J Feline Med Surg.* 2009;11:430-434.
31. Lyons AL, Biller SD, Erdman AC, et al. Feline polycystic kidney disease mutation identified in PKD1. *J Am Soc Nephrol.* 2004;15(10):2548-2555.
32. Lulich JP, Osborne CA. Polycystic kidney disease. Tillet LP, Smith WKF, eds. Blackwells Five-Minute Veterinary Consult: Canine and Feline. New Delhi India: Wiley-Blackwell Published; 2011:1121.
33. Tipisca V, Murino C, Cortese L, et al. Resistive index for kidney evaluation in normal and diseased cats. *J Feline Med Surg.* 2016;18(6):471-475.
34. Widmer RW, Mattoon JS, Vaden SL. Urinary tract. Mattoon JS, Sellon RK, Berry CR, eds. Small Animal Diagnostic Ultrasound. China: Elsevier; 2020:583-630.
35. Canpolat İ. Renal ultrasonographic anatomy in dogs and cats. *Turk J Vet Anim Sci.* 1996;20(6):419-423.
36. Park I, Lee H, Kim J, et al. Ultrasonographic evaluation of renal dimension and resistive index in clinically healthy Korean domestic short-hair cats. *J Vet Sci.* 2009;9:415-419.
37. Novellas R, Ruiz De Gopegui R, Espada Y. Assessment of renal vascular resistance and blood pressure in dogs and cats with renal disease. *Vet Rec.* 2010;166:618-623.
38. Temiz S. Kedilerde Hernia Diafragmatikanın Böbrek Resistif ve Pulzatif İndeks Değerlerine Etkisi. Yüksek Lisans Tezi. Ankara Üniversitesi; 2017.
39. Ostrowska J, Kielbowicz Z, Dorobisz ZU, Atamaniuk W, Fulbiszewska PA, Kinda W. Resistive index (RI) obtained in renal interlobar arteries of normal dog and cat by means of doppler ultrasonography. *Pak Vet J.* 2016;36(01):45-48.
40. River JB, Walter AP, Polzin JD, King LV. Duplex doppler estimation of intrarenal pourcelot resistive index in dog and cat with renal disease. *JVIM.* 1997;11(4):250-260.
41. Gönül R, Koenhemi L, Oralkan D, Or ME, Uysal A. Kronik böbrek yetmezliği bulunan bir kedide renal vasküler direncin doppler ultrasonografi ile saptanması. *Van Vet J.* 2011;22(2):111-113.
42. Barthez P, Riviver P, Begon D. Prevalence of polycystic kidney disease in Persian and Persian related cats in France. *J Feline Med Surg.* 2003;5:345-347.
43. Cannon JM, Mackay AD, Barr FJ, Rudorfh H, Bradley JH, Hones TJG. Prevalence of polycystic kidney disease in Persian cats in the United Kingdom. *Vet Rec.* 2001;149:409-411.