

CASE REPORT

**A Severe Autoimmune-like Anti-Tuberculosis Drug-induced Liver Injury:
Case Report and Review**

Jorge R. Mosqueira¹, Sue Anicama², Jorge De Los Ríos³

¹Médico Cirujano, Universidad Peruana Cayetano Heredia, Departamento de Medicina Interna, Hospital María Auxiliadora, Lima, Perú

²Médico Cirujano, Universidad de San Martín de Porres, Lima, Perú

³Jefe del Servicio de Neumología "CENEX Niño Jesús", Hospital María Auxiliadora, Lima, Perú

ABSTRACT

Drug-induced liver injury is one of the most significant adverse drugs reactions and, in severe cases, could be a potentially life-threatening condition. It can be classified in intrinsic and idiosyncratic reactions and, anti-tuberculous drugs are known to induce the later one. In some cases, it might develop some autoimmune features which represent a challenge for both diagnosis and treatment. We report a 37-year-old woman who was admitted to our hospital with signs of severe acute liver injury. She was diagnosed with autoimmune-like drug-induced liver injury by anti-tuberculous drugs and was treated with corticosteroids, N-Acetylcysteine and Ursodesoxycholic acid. Indeed, based on this case a review of the literature is presented. *J Microbiol Infect Dis* 2018; 8(3):128-134

Keywords: Anti-tuberculous drugs; Corticosteroids; Drug-induced Liver Injury, N-Acetylcysteine, Tuberculosis

INTRODUCTION

Despite its low incidence in general population, Drug-Induced Liver Injury (DILI) remains one of the most challenging conditions [1], especially in developing countries where it is most commonly related to first-line anti-tuberculous (TB) drugs [2]. Anti-TB DILI is defined as the liver damage due to an idiosyncratic reaction of anti-TB drugs and is often an ignored fact, regardless of its potential hamper to the epidemic TB control [3]. Clinical presentation varies widely from asymptomatic liver function tests (LFTs) alteration to a symptomatic disease characterized by nausea, vomiting, anorexia, jaundice, abdominal pain, or even fatal acute liver failure (ALF) [3,4]. The diagnosis is done by exclusion of other causes of liver injury [1,4,5]. Thus, it is very important to describe the pattern of this hepatic damage and if it is autoimmune related. Treatment for this condition remains highly controversial, but the cornerstone of its management is the immediate medication withdrawal that alone could lead to remission in most cases [1,4]. There are also many anti-inflammatory and hepatoprotective agents

(AIHPAs) that have been proposed, although evidence of benefit is inconclusive [4].

CASE REPORT

A 37-year-old Latin American woman was transferred from a Primary Care Center to our Hospital María Auxiliadora due to abnormal LFTs despite Isoniazid (INH), Rifampicin (RMP), Ethambutol (EMB), and Pyrazinamide (PZA) discontinuation. Her past medical history was significant for cholelithiasis and pulmonary tuberculosis treated 13 years ago with the standard first-line anti-TB drugs.

As part of her history of present illness, three weeks after anti-TB drugs were started she presented a skin rash successfully treated with antihistamines. Nonetheless, at the 4th week of being on treatment, an episode of nausea and vomiting that slowly progressed to food intolerance began. Despite that LFTs were normal at the beginning of anti-TB treatment, she developed generalized jaundice and a significant elevation of Aspartate Aminotransferase (AST), Alanine Aminotransferase (ALT), Alkaline Phosphatase (ALP) and bilirubin (BIL), predominantly

Correspondence: Jorge R. Mosqueira, Jefe del Servicio de Neumología "CENEX Niño Jesús", Hospital María Auxiliadora, Lima, Perú

Email: jorge.mosqueira.s@alumni-upch.edu.pe

Received: 24 May 2018 Accepted: 18 August 2018

Copyright © JMID / Journal of Microbiology and Infectious Diseases 2018, All rights reserved

conjugated BIL (CBIL). Therefore, approximately at the end of the 5th week all anti-TB drugs were suspended. However, two weeks later her AST, ALT and ALP levels were in 1125 U/L, 950 U/L and 720 U/L, respectively (Figure 1).

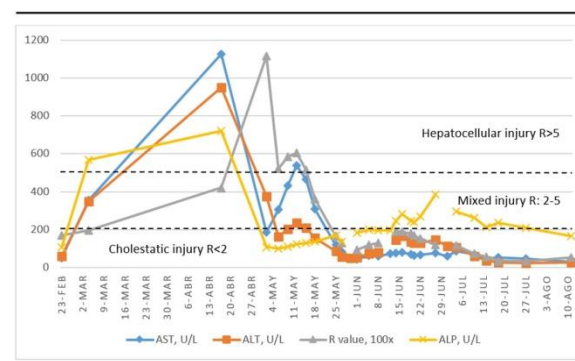
The patient was admitted to our hospital three weeks after drug withdrawal with the following laboratory results: total BIL in 24.75 mg/dl, CBIL in 15.6 mg/dl, AST in 187 U/L, ALT in 376 U/L, ALP in 108 mg/dl, International Normalized Ratio (INR) in 2.35 and hypoalbuminemia. During hospitalization, the patient progressively had tolerated oral intake, but continued with conjugated hyperbilirubinemia greater than 10 mg/dl (Figure 2). Negative findings from direct bacilloscopy on the sputum, faeces and urine were obtained.

Indeed, other causes of liver injury were ruled out. Thus, an abdominal ultrasound showed only diffuse parenchymal liver involvement. Also, a magnetic resonance cholangiopancreatography (MRCP) was performed showing only cholelithiasis. Serologic tests for HIV, hepatitis A, B and C (anti-HAV IgM, HbsAg, anti-HbsAg, anti-HCV) were negative. We also ruled out immunologic causes of liver injury with negative results for AMA, anti-LKM1 and ASMA; nonetheless, we obtained a homogeneous pattern of week positive ANA (1/40), a positive PR3-ANCA (7.4) with a cytoplasmic pattern and also a positive IgG levels (3234 U/L). Finally, because the patient had no clinical and laboratory improvement, a liver biopsy was performed with inconclusive results due to a very small sample, only intrahepatic cholestasis was evident. According to these results, the diagnosis of an idiosyncratic autoimmune-like DILI induced by anti-TB drugs was confirmed.

As soon as the diagnosis was done, the patient was started on corticosteroids: Dexamethasone 4 mg IV t.i.d. for 1 week, then the dose was deescalated to 4 mg IV b.i.d. for one week and, finally, to 4 mg IV q.d. for one week more. Then, it was changed to Methylprednisolone PO for two months due to its stronger glucocorticoid effect. We started with 40 mg and deescalated progressively until withdrawal. She also received, as an adjuvant treatment, N-Acetylcysteine (NAC) 600 mg PO t.i.d. for two weeks and Ursodesoxycholic acid (UDCA) 300 mg PO t.i.d. for four weeks. The LFTs levels

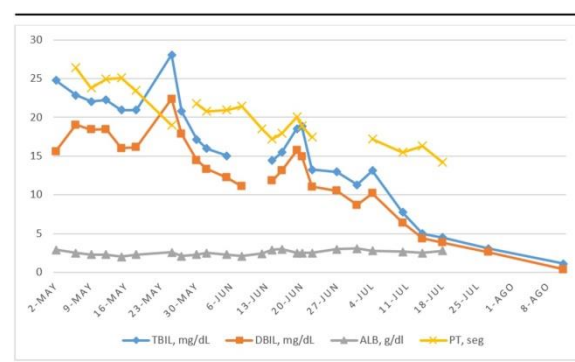
decreased gradually and, within five months of the DILI onset, they got back to normal level (Figures 1 and 2). She also received Vitamin K 10 mg IV q.d. to help correct the INR. Due to the long-term corticosteroid treatment, the patient developed Cushing Syndrome and Diabetes.

Approximately two months after anti-TB drugs withdrawal, she presented positive bacilloscopy tests in sputum and faeces and an alternative anti-TB treatment was started with Levofloxacin 750 mg PO q.d., Ethambutol 1200 mg PO q.d., Amoxicillin/Clavulanic acid 1 g PO b.i.d., Cycloserine 250 mg PO b.i.d. and Amikacin 750 mg IV q.d., without relapse of the liver injury. The patient was discharged and continued her follow-up to the present. Unfortunately, the establishment of central nervous system tuberculosis also occurred.



ALP = alkaline phosphatase, ALT = alanine aminotransferase, AST = aspartate aminotransferase.

Figure 1. Changes in transaminases, ALP and R value since the start of anti-TB treatment



ALB = albumin, DBIL = direct bilirubin, PT = prothrombin time, TBIL = total bilirubin.

Figure 2. Changes in bilirubin, albumin and PT during hospitalization.

DISCUSSION

Despite the health policies implemented, tuberculosis continues being a global health problem, for both industrialized and developing

countries [6]. In Peru, the National Health Strategy for the Prevention and Control of Tuberculosis (ESNPCT) reported that there were 30 988 cases of this disease, with an incidence rate of 87,6 cases per 100 000 inhabitants by 2015 [7]. Currently, investigators as Altındış M. and colleagues have been searching for the best method for early detection of Mycobacterium isolates and drug susceptibility testing [6]. Treatment for this disease includes a combination of several drugs with synergistic effects, that together are effective against different mycobacterial populations and prevents drug resistance. Even though, the majority of patients endure the combination of these drugs, a few can develop adverse effects, being hepatotoxicity the most significant [3].

DILI is a clinical diagnosis of exclusion, caused by any prescription or non-prescription drugs, herbal or dietary supplements [1,4,5]. The incidence of DILI in the general population is estimated to be between 1/100,000 and 20/100,000 [1] and accounts for less than 2% of patients hospitalized for jaundice [5,8]. However, DILI is the leading cause for drugs withdrawal in clinical trials [8], accounts for 7% of all reported drug adverse effects [5]. Also, it is the most common cause of ALF worldwide which has a poor prognosis with a high mortality rate [7,9].

DILI is classified in two major groups according to their underlying mechanism: intrinsic and idiosyncratic reactions. The former is a dose-related, predictable and direct hepatotoxic drug reaction (e.g. acetaminophen overdose). On the other hand, idiosyncratic DILI is unpredictable, dose-independent, occurs only in susceptible individuals and has a large range of presentations [1]. Idiosyncratic DILI is described for anti-TB drugs [2] and can be further classified into immune-mediated DILI and genetically-mediated DILI [9].

The incidence of anti-TB DILI varied widely from 2% to 33% between different populations and studies due to the different definitions and criteria used, and its mortality rate can be as high as 27% [10,11]. There is no local data available. The most commonly associated drugs are INH, RMP and PZA, and when used together, the risk for DILI increases [11]. The clinical manifestations of anti-TB DILI are usually nonspecific and varies from an asymptomatic minimal elevation of LFTs to fatal ALF that could result in death or a liver transplantation [1,3]. It is

known that patients started on standard anti-TB regimens can experience asymptomatic transaminase elevations in 20% of cases, which resolve spontaneously, even when drugs are continued due to a liver adaptation process [11]. The latency period to DILI onset can diverge greatly across individuals, but the majority of cases of anti-TB DILI occurs within the two months of starting the intensive phase of anti-TB treatment [10]. Our patient had a very short latency period but, unfortunately, the decision to withdraw the medication was not made until the 5th week of treatment which could have a deleterious impact on the severity of the disease. Therefore, it is vital to monitor the LFTs to detect liver injury earlier and intervene when necessary.

Risk factors for DILI include host (genetic or non-genetic), pharmaceutical and environmental factors [1,4]. In our patient, the only risk factor was female sex; otherwise, she was young, not pregnant, had no underlying diseases such as chronic liver disease, hepatitis B or C infection, HIV infection, autoimmune liver disease, diabetes, malnutrition or obesity; she was a non-smoker, had no history of alcohol consumption and was not on any other medication, dietary or herbal supplement. Genetic factors were not evaluated due to lack of resources.

The steps to do a correct diagnosis of DILI are the following: (1) confirm the presence of liver injury; (2) exclude other causes of liver injury; (3) perform a causality assessment by linking the liver damage and its characteristics to the specific drugs; (4) in some cases, a liver biopsy may be necessary; (5) classify DILI according to pattern of injury, course or outcome of the disease, grade of severity and the presence or absent of autoimmune features [1,4].

According to the Chinese Society of Hepatology (CSH) [4] and American College of Gastroenterologist (ACG) [1] guidelines, our patient met all the biochemical criteria for DILI (ALT \geq 5 ULN, ALP \geq 2 ULN or ALT \geq 3 ULN and T. Bil \geq 2 ULN). However, in anti-TB DILI, the use of ALP is controversial because anti-TB drugs or tuberculosis itself can alter this parameter [12]. On the other hand, according to the American Thoracic Society (ATS) [5], the Infectious Diseases Society of America (IDSA) [13] and the British HIV Association (BHIVA) [12] guidelines, the criteria for DILI are ALT \geq 3 ULN with symptoms of hepatitis, or \geq 5 ULN without

symptoms. Even the Southern African guideline consider only elevations in ALT and TBIL [11]. Therefore, there is no consensus for the DILI diagnostic criteria, and it is even more debatable in cases of anti-TB DILI. Nevertheless, our patient could meet the diagnostic criteria proposed by all guidelines. It is important to mention that our patient also accomplished the "Hy's law" (elevation of ALT or AST >3 ULN and TBIL >2 ULN with no other apparent cause), which suggest a 1 in 10 mortality risk for DILI [1,4], and indeed she developed severe signs of liver injury.

In this patient, we ruled out disseminated tuberculosis and the main differential diagnoses for DILI such as viral infections, alcoholic liver disease, nonalcoholic fatty liver disease, autoimmune liver disease and bile tract obstruction [4] in order to confirm the diagnosis. We also applied The Roussel Uclaf Causality Assessment Method (RUCAM), the most used diagnosis algorithm for DILI [1,4], obtaining a score of 7 points. This indicates a "probable" correlation between the anti-TB drugs and the liver injury. Rechallenge was not advisable due to the severity of the disease and the slow improvement of the LFTs in our patient. Indeed, DILI guidelines discourage the re-administration of a suspected hepatotoxic drug [1,4].

DILI can be classified, based on clinical pattern of injury, into hepatocellular injury, cholestatic injury and mixed injury [1,4]. This is useful for the differential diagnoses, because most drugs are associated with a certain pattern [9]. The criteria for judging between the three types of DILI is the R-value, obtained by $ALT/ULN \div ALP/ULN$: (1) hepatocellular, $R > 5$; (2) mixed, $R = 2-5$; and cholestatic, $R < 2$ [1,4]. This exercise has to be performed different times during the course of the disease to determine the initial pattern, evolution of DILI and, therefore, select the most accurately treatment at the time [4]. First, our patient had a R value of 1.95 (cholestatic injury). Then, the patient presented a considerable elevation of transaminases with an R value of 11.14 (hepatocellular injury), reason why she was transferred to our Hospital. However, later on, transaminases level was decreasing and the ALP remained high for a much longer time. The R value had changed progressively to a mixed injury and, finally, to a cholestatic injury pattern until remission of the disease (Figure 1). This progression differs from

the literature which states that anti-TB drugs are more likely to produce a hepatocellular pattern, which is also the most common and more probable to develop a severe and fatal disease [8,9].

Based on the course of disease, this patient had an acute DILI because LFTs returned to normal level within 5 months (Chronic DILI is considered if LFTs remain abnormal more than 6 months, or if there is radiographic and histological evidence for portal hypertension or chronic liver injury) [4]. According to the CSH guideline [4] the severity of DILI in our patient was grade 3, which indicates severe liver injury. Taking into account the US DILI Network classification [8], our patient had a moderate-hospitalized DILI.

Some autoimmune features such as positive autoantibodies (PR3-ANCA) and elevated IgG levels were detected. Thus, an Autoimmune-like DILI was considered. This entity predominates in women, accounting for 92% of cases [14], and can be classified in autoimmune hepatitis (AIH) with superimposed DILI, drug-induced AIH (DI-AIH), and immune-mediated DILI (IM-DILI) [14]. Our patient most likely had the later one, which is the most frequent and is produced by a hypersensitivity drug reaction, that can explain the skin rash our patient presented initially. Because there was a significant overlap of clinical and histological features, a liver biopsy was done; unfortunately, results were inconclusive, showing only some signs of cholestasis but, that are usually seen in IM-DILI [14,15]. None typical histological features of AIH were reported. IM-DILI usually presents with $ALT/AST > 5-20$ ULN, gradually improves after the suspected drug is withdrawal and has a complete remission with corticosteroid therapy that can be discontinued after 1 to 6 months without relapse of liver injury [14], as in our patient. Recurrence is common with a shorter latency period and could result in more severe immunoallergic manifestations and liver injury [14].

Once the diagnosis is established, treatment should be started as soon as possible. The four pillars for DILI treatment are: (1) withdrawal of the suspected drugs immediately if not critical for the control of underlying disease; (2) weigh the balance between the risk of progression of the underlying disease after drug withdrawal and the risk of deterioration of the liver injury caused

by continuing the use of the alleged drugs; (3) treat the DILI with AIHPAs according to the clinical patterns of injury; (4) consider emergency liver transplantation in patients with ALF [1,4].

The opportune withdrawal of the suspected hepatotoxic drugs is the cornerstone of the DILI treatment. Spontaneous improvement after drug cessation is accomplished in approximately 95% of patients and most of them will recover completely without any other intervention [1,4]. On the other hand, the suspension of the anti-TB drugs can lead to treatment failure with progression of the disease or drug resistance [5]. Therefore, the decision of when to stop the anti-TB drugs is a challenge. To help discern this, the Food and Drug Administration (FDA) had established some criteria for the withdrawal of any hepatotoxic medications, which our patient met just one week after the anti-TB drugs were started (ALT/AST>8 ULN; ALT/AST>5 ULN, which lasts for 2 weeks; ALT/AST>3 ULN, with TBIL>2 ULN, INR>1.5 or hepatitis symptoms) [4,16]. However, in her Primary Care Center the decision was made: continue the anti-TB drugs; unfortunately, transaminases level reached a peak of more than 20 times the ULN and this may have contributed to a serious hepatocellular injury, which at first was mainly cholestatic.

According to guidelines, first-line anti-TB drugs should be withheld ideally until the LFTs normalize, or until ALT falls below two times ULN. Meanwhile, clinicians could initiate a regimen with at least three anti-TB agents that are less likely to cause hepatotoxicity such as Ethambutol (EMB), an aminoglycoside and a fluoroquinolone [2,5,11]. Since bacilloscopy tests were negative during hospitalization and her LFTs remain substantially high, it was considered not necessary to start this alternative regimen in our patient. All anti-TB DILI guidelines affirm that, as first-line anti-TB drugs are highly effective and relatively inexpensive, the benefits of rechallenge outweigh its risks and it is acceptable to attempt reintroduction of these medications in most patients with different strategies according to each guide [2,5,11]. However, the possibility of DILI recurrence (reported in 11–24% of patients) [2], the severity of the disease in our patient, its slow improvement and its autoimmune features, urged us not to follow this recommendation. In

our patient, no other anti-TB regimen was started until bacilloscopy tests in sputum and faeces were positive two months after drugs withdrawal. The new anti-TB regimen implemented in our patient did not include INH, RMP or PZA.

Following drug withdrawal, there are no definitive therapies available for idiosyncratic DILI rather than supportive care. However, many AIHPAs are proposed since could improve the LFTs and prevent the developing of chronicity or even ALF in severe cases, but there is no definitive evidence to support their use [1,4,16].

NAC, the antidote for acetaminophen overdoses, has been proposed for preventing ALF due to other agents, in particular, anti-TB drugs [1,4,16]. Lee et al. performed the first clinical trial of IV NAC for patients with ALF not secondary to acetaminophen overdose and found that, while overall survival was similar in the populations (70% vs. 66%), transplant-free survival was considerably better for those who received NAC (40% vs.27%) [17]. Since then, several studies have found that NAC increases patient's survival, reduces mortality and need for transplantation, decreases encephalopathy, hospital stay, ICU admission, and failure of other organs in non-acetaminophen-induced ALF [18,19], even when given orally [20].

Corticosteroids are generally used for the therapy of IM-DILI, usually with good response, rare recurrence of liver injury after the its withdrawal [1,4,14], but it can also be administered in severe cases of DILI. However, its use should be cautiously considered due to the multiple adverse reactions [4]. Hu et al. performed a retrospective study with 203 DILI patients, of which 53 were treated with corticosteroids, finding that this therapy improved patient survival and hastened the resolution of liver injury by shortening the duration of peak TBIL to 50% reduction in severe cases [21].

UDCA decreases the duration of the liver injury and help preventing the develop of the vanishing bile duct syndrome [15]. According to the CSH guideline, patients with a cholestatic DILI can be treated with this agent [4]. Wree et al. reported the use of a 3-day regimen of pulsed corticosteroids or a step down therapy over several weeks combined with oral UDCA in 15 patients with severe DILI, including those with hepatocellular and/or cholestatic injury. Both

therapies demonstrated a safe, rapid reduction of TBIL, AST, and ALT. However, in this study, patients with autoimmune features had the slowest improvement, with some requiring long-term immunosuppressive therapy [22].

Despite that the CSH guideline does not recommend the combination of two or more types of AIHPAs [4], we used three of them together in our patient because of the severity presented in this case, the autoimmune features and the cholestatic pattern of injury.

The main limitation of this case was to reach the diagnosis due to lack of resources in our hospital. Because of this, many laboratory exams and procedures were delayed and, therefore, the accurate diagnosis was done late and opportune treatment was postponed.

Conclusion

In spite of the fact that DILI for anti-TB drugs is a relatively rare disease in the general population, it is the most common and serious drug adverse reaction during anti-TB treatment; so, if no timely and appropriate management is given, it may become a life-threatening condition. It usually responds to the suspension of the anti-TB drugs but, in severe cases such as in our patient, whose diagnosis was an idiosyncratic autoimmune-like DILI due to anti-TB drugs, it could be beneficial the use of AIHPAs such as corticosteroids (in pulses or in a step down therapy), NAC (that could also be given orally) or UDCA (for cholestatic pattern). Therefore, we suggest taking into consideration these findings in clinical practice and future case reports.

ACKNOWLEDGMENTS

Conflict of Interest:

There is no conflict of interest involved in this case.

Financial Disclosure:

There is no financial support in this case report.

REFERENCES

- 1) Chalasani NP, Hayashi PH, Bonkovsky HI, Navarro VJ, Lee WM, Fontana RJ. ACG clinical guideline: The diagnosis and management of idiosyncratic drug-induced liver injury. *The Am J Gastroenterol* 2014; 109(7):950-966.
- 2) Ramappa V, Aithal GP. Hepatotoxicity related to anti-tuberculosis drugs: mechanisms and management. *J Clin Exp Hepatol* 2013;3(1): 37-49.
- 3) Naqvi IH, Mahmood K, Talib A, Mahmood A. Antituberculosis drug-induced liver injury: an ignored fact, assessment of frequency, patterns, severity and risk factors. *Open Journal of Gastroenterology* 2015;5(12):173-184.
- 4) Yu YC, Mao YM, Chen CW, et al. CSH guidelines for the diagnosis and treatment of drug-induced liver injury. *Hepato Int* 2017; 11(3):221-241.
- 5) Saukkonen JJ, Cohn DL, Jasmer RM, et al. An Official ATS Statement: Hepatotoxicity of Antituberculosis Therapy. *Am J Respir Crit Care Med* 2006; 174(8):935-952.
- 6) Altındış M, Çetinkaya Z, Kalaycı R, Ciftçi IH, Arslan A, Aktepe OC. Detection of Mycobacterium isolates with different methods and their resistance ratios against anti-tuberculosis drugs. *J Microbiol Infect Dis* 2011; 1 (1): 5-9.
- 7) Alarcón V, Alarcón E, Figueroa C, Mendoza-Ticona A. Tuberculosis en el Perú: situación epidemiológica, avances y desafíos para su control. *Rev Peru Med Exp Salud Publica* 2017; 34(2): 299-310.
- 8) Saithanyamurthi H, Faust AJ. Drug-Induced Liver Disease: Clinical Course. *Clin Liver Dis* 2017; 21(1):21-34.
- 9) Giordano C, Rivas J, Zervos X. An update on treatment of drug-induced liver injury. *J Clin Transl Hepatol* 2014;2(2):74-79.
- 10) Abbara A, Chitty S, Roe JK, et al. Drug-induced liver injury from antituberculous treatment: a retrospective study from a large TB centre in the UK. *BMC Infect Dis* 2017; 17(1):231.
- 11) Jong E, Conradie F, Berhanu R, et al. Consensus statement: Management of drug-induced liver injury in HIV-positive patients treated for TB. *South Afr J HIV Med* 2013; 14(3): 113-119.
- 12) Pozniak A, Bracchi M, Awosusi F, et al. British HIV Association guidelines for the management of TB/HIV co-infection in adults, 2017 [Internet]. *Bhiva.org*. 2018 [cited 1 May 2018]. Available from: <http://www.bhiva.org/documents/Guidelines/TB/BHIVA-TB-HIV-co-infection-guidelines-consultation.pdf>
- 13) Nahid P, Dorman SE, Alipanah N, et al. Official American Thoracic Society/Centers for Disease Control and Prevention/Infectious Diseases Society of America Clinical Practice Guidelines: Treatment of Drug-Susceptible Tuberculosis. *Clin Infect Dis* 2016; 63(7):147-195.

- 14) deLemos AS, Foureau DM, Jacobs C, Ahrens W, Russo MW, Bonkovsky HL. Drug-induced liver injury with autoimmune features. *Semin Liver Dis* 2014; 34(2):194-204.
- 15) Rangel MA, Pinto I, Duarte R, Carvalho I. Antituberculosis Drug-Induced Liver Injury with Autoimmune Features: Facing Diagnostic and Treatment Challenges. *Case Rep Pediatr* 2017; 2017:5741896.
- 16) Stine JG, Lewis JH. Current and future directions in the treatment and prevention of drug-induced liver injury: a systematic review *Expert Rev Gastroenterol Hepatol* 2016; 10(4):517-536.
- 17) Lee WM, Hynan LS, Rossaro L, et al. Intravenous N-Acetylcysteine improves transplant free survival in early stage non-acetaminophen acute liver failure. *Gastroenterology* 2009; 137(3):856-64.
- 18) Nabi T, Nabi S, Rafiq N, Shah A. Role of N-acetylcysteine treatment in non-acetaminophen-induced acute liver failure: A prospective study. *Saudi J Gastroenterol* 2017; 23(3):169-175.
- 19) Darweesh SK, Ibrahim MF, El-Tahawy MA. Effect of N-acetylcysteine on mortality and liver transplantation rate in non-acetaminophen-induced acute liver failure: A multicenter study. *Clin Drug Investig* 2017; 37(5):473-482.
- 20) Hu J, Zhang Q, Ren X, Sun Z, Quan Q. Efficacy and safety of acetylcysteine in "non-acetaminophen" acute liver failure: A meta-analysis of prospective clinical trials. *Clin Res Hepatol Gastroenterol* 2015; 39(5):594-599.
- 21) Hu PF, Wang PQ, Chen H, et al. Beneficial effect of corticosteroids for patients with severe drug-induced liver injury. *J Dig Dis* 2016; 17(9):618-627.
- 22) Wree A, Dechêne A, Herzer K, et al. Steroid and ursodesoxycholic acid combination therapy in severe drug-induced liver injury. *Digestion* 2011; 84(1):54-59.