

## Undetected Duplication Cyst of The Cecum Until Adulthood

Oguzhan Ozsay<sup>1</sup>, Fevzi Cengiz<sup>1</sup>, Nese Ekinci<sup>2</sup>, Salih Can Celik<sup>1</sup>, Kemal Erdinc Kamer<sup>1</sup>

<sup>1</sup>Katip Celebi University Ataturk Training and Research Hospital, General Surgery, İzmir, Turkey  
<sup>2</sup>Katip Celebi University Ataturk Training and Research Hospital, Pathology, İzmir, Turkey

### ABSTRACT

Intestinal duplication is a rare congenital anomaly of the digestive tract. It is often diagnosed antenatally or in the first two years of life. It is observed anywhere in the digestive tract, often in ileum and jejunum. We present a rare case of colonic duplication cyst in adult age in this paper. Our case was diagnosed by ultrasonography performed due to the complaint of chronic abdominal pain and was followed up for 18 months. The patient underwent surgery due to strong suspicion of malignancy. During the operation, the cyst was accessed only after palpation and was resected together with the right colon. The definitive diagnosis could be made by pathological examination. Duplication cysts can cause significant morbidity and even mortality if left untreated. For this reason, it is important to recognize this rare congenital anomaly.

**Key words:** Colonic duplication, gastrointestinal congenital anomaly, adult

### Correspondence:

Fevzi Cengiz, Assoc Prof.  
**Address:** Department of Surgery, Izmir Katip Celebi University Ataturk Training and Research Hospital, Izmir, 35360, Turkey  
**Email:** drfevzi@gmail.com

### INTRODUCTION

Gastrointestinal duplication cysts are rare congenital malformations without a clearly understood etiology [1]. Duplications are very occasionally observed abnormalities and most of them occur in the abdominal cavity (75%), however, they can be present at any point along the gastrointestinal tract from the oral cavity to the anus [1]. Gastrointestinal duplication cysts are predominantly detected before the age of 2 years [1]. They are rarely found in the colon and very few cases have been described in adults [1]. Clinical features of colonic duplication include vague abdominal pain, abdominal mass, and chronic constipation all of which occur due to pressure or direct effects of the lesion [2]. Although they are benign, some fatal consequences may arise if they are not treated appropriately [3]. Surgically treated intestinal duplications have a good prognosis [3]. The main aim of this study is presenting the treatment and follow up of duplication cysts that are quite infrequently observed in adulthood.

### Case

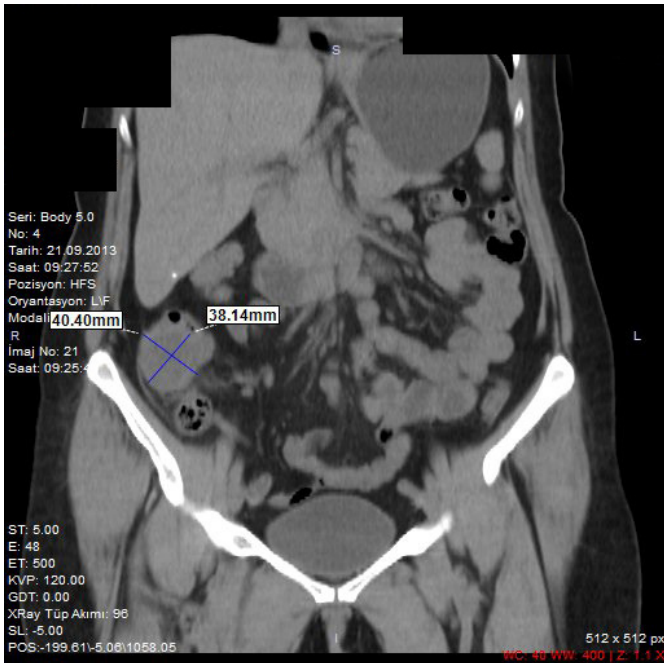
A 52-year-old woman, who was treated due to constipation and abdominal pain is presented.

There was either no medical or family history of a hereditary or chronic disease. Due to the abovementioned complaints in 2011, the patient underwent colonoscopy with a pre-diagnosis of unspecified functional bowel disorder, however, no pathologies were detected. On the other hand, as the abdominal complaints of the patient sustained, she had intermittent hospital presentations. An abdominal ultrasound (USG), in 2013, reported a localized collection of fluid on the ascending colon trace (fluid in the lumen of the colon? or pericolic cyst?) in the right lumbar region. The abdominal computerized tomography (CT) examination at that time reported identification of a liquid-filled structure of 35x40mm in size with thick walls (Figure 1). Then, another colonoscopy was reperformed, however, no pathological structures were identified. During the follow-up period, the tumor marker levels were normal. An abdominal CT in 2015 identified a mass that was reported to be growing posteriorly and it was noted that the mass had regular margins. And it was 33x30x28 mm in size. In addition, a large number of lymph nodes in non-pathological sizes were reported around the cecum. Compared to the previous CT examination, the retroperitoneal

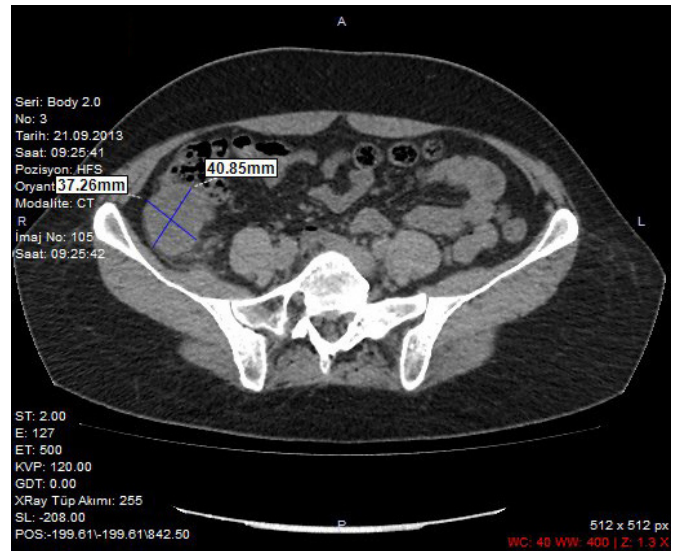
**Received:** 01.05.2018,  
**Accepted:** 26.06.2018  
**DOI:** 10.5799/jcei.458764

fatty tissue around the lesion showed an increase in density consistent with inflammation (Figure 2). The patient was referred to general surgery department to be operated due to the current findings. The surgery started with laparoscopic exploration, but the radiologically defined mass was not observed despite all the dissections made. After laparotomy, the palpation of the cecum and the ascending colon revealed incorporation of the mass with the colon. Then, the mass was removed by a right hemicolectomy.

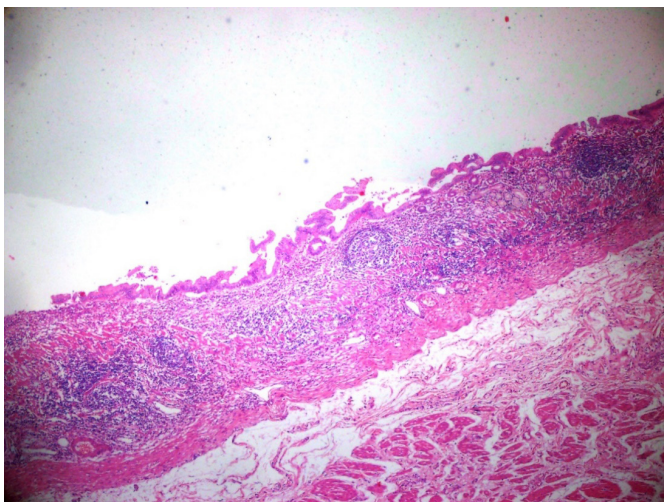
The postoperative period was uneventful, and the patient was discharged from the hospital on the 5th day. The histopathological examination of the right hemicolectomy material revealed an enteric cyst and reactive lymphoid hyperplasia in 16 lymph nodes. On the microscopic examination, it was observed that the cyst wall was not related to the intestinal lumen. In the cyst wall, intestinal mucosa and muscularis propria were observed in addition to the ectopic gastric mucosa (Figure 3).



**Figure 1.** 2013 being adjacent to the intestinal wall, and approximately 35x40mm in size a thick-walled fluid-filled formation was detected



**Figure 2.** 2015 growing posteriorly, it is located just superior to the ileocecal valve. It has regular margins and is 33x30x28 mm in size. A large number of lymph nodes at non-pathological sizes were identified around the cecum



**Figure 3.** Olympus BX51 used under x4 magnification ratio for the microscope examination; Cyst wall proliferated gastric type epithelium with pyloric type glands and two muscle layers

## DISCUSSION

Gastrointestinal duplications are identified by the screening methods prenatally during pregnancy or in the first two years of life at a rate of 67-80% [1,3,4]. It may rarely be asymptomatic and may remain unattended until adulthood [3,4]. The case presented in our paper is a rare occurrence of duplication, which was diagnosed in an adult. Our case was diagnosed with a colonic duplication, which is particularly highlighted. Colonic duplications are reported in the literature with a rate of 7-13% among all duplications [4,5].

Independent of their localization, duplications have three common characteristics; first, they are hollow structures, secondly, they are covered by the gastrointestinal system mucosa, and finally, their walls made of smooth muscles and are often common with the adjacent intestinal wall [3]. The radiologic examination of our case clearly showed the cystic structure of the mass in addition to the histopathological examination revealing that the cyst lumen was covered with the intestinal mucosa and that it was incorporated with the adjacent intestinal smooth muscle structure. Duplication cysts are typically not related to the adjacent

intestinal lumen as observed in our case, whereas tubular lesions may be related to the colon [6].

Duplications are classified according to location, structure [cystic (80%) or tubular (20%)], and presence of ectopic tissue (gastric mucosa is present in 50% of cases) [1,3]. The point to note in this classification is that these three parameters are decisive in determining the clinical phenomenon. During adulthood, the symptoms may range from vague minor digestive problems to bowel obstruction, gastrointestinal bleeding or perforation [3]. In our case, the first detection of the duplication was by ultrasonography. Despite the initial colonoscopy, the duplication remained unnoticed due to its cystic structure and the lack of luminal relation. In literature, CT scanning findings have been reported to be confused with other conditions such as cystic pancreatic tumors, mesenteric inflammatory masses, or Meckel's diverticulum, although it may help in the diagnosis of colonic duplications [2]. Often the duplication is diagnosed during the operation nonetheless our case was diagnosed only after the pathological examination.

Intestinal duplications usually require immediate surgical interventions [3]. However, our case experienced a follow-up period of 18 months, unlike other intestinal duplications presented in the literature. The patient was operated electively due to the inflammation and presence of lymphadenopathies. In previous publications on duplication cysts, some reports suggest that all duplications should be treated with surgical interventions. On the other hand, there are other reports suggesting that only symptomatic duplications should be treated surgically [1,3]. Although the size of the colonic duplication cyst was small in our case study, the observed radiological changes during the follow-up period suggested malignancy, which was not excluded

from the differential diagnosis. This suggests that surgical interventions will be likely during this type of cases. Ectopic gastric mucosa was observed in the histopathologic examination of our patient. As ectopic tissues bear a potential for malignancies, they need to be resected to prevent late-stage complications [4].

In conclusion, although the clinical diagnosis of the colonic duplications, which are rarely diagnosed in adults may be difficult, however, they must be addressed in the differential diagnosis for adults with abdominal masses, chronic abdominal pain, and constipation. Early diagnosis and treatment reduce the risk of dangerous complications such as perforation, bleeding, obstruction and malignant transformations.

**Declaration of interest:** The authors report no conflicts of interest.

**Financial Disclosure:** No financial support was received.

## REFERENCES

1. Fenelon C, Boland MR, Kenny B, Faul P, Tormey S. A colonic duplication cyst causing bowel ischaemia in a 74-year-old lady. *J Surg Case Rep.* 2016;8:1-3.
2. Yong YG, Jung KU, Cho YB, et al. Large tubular colonic duplication in an adult treated with a small midline incision. *J Korean Surg Soc.* 2012;82:190-4.
3. Cavar S, Bogović M, Luetić T, Antabak A, Batinica S. Intestinal duplications—experience in 6 cases. *Eur Surg Res.* 2006;38:329-32.
4. Sharma S, Yadav AK, Mandal AK, Zaheer S, Yadav DK, Samie A. Enteric duplication cysts in children: a clinicopathological dilemma. *J Clin Diagn Res.* 2015;9:8-11.
5. Puligandla PS, Nguyen LT, St-Vil D, et al. Gastrointestinal duplications. *J Pediatr Surg.* 2003;38:740-44.
6. Stefanidis K, Lappas I, Kolofousi C, Kalogeropoulos I. A rare presentation of colonic duplication cyst: report of a case and review of literature. *JBR-BTR.* 2012;95:71-3.