



ARAŞTIRMA / RESEARCH

Effect of axitinib on inflammation in experimental corneal neovascularization model in rats

Axitinibin sıçanlarda deneysel kornea neovascularizasyon modelinde inflamasyona etkisi

Necmiye Canacankatan¹, Erdem Dinç², Deniz Kibar³, Cem Yalaza⁴, Şerife Efsun Antmen⁵, Hacer Merve Gürler¹, Banu Yılmaz Coşkun³, Bahar Taşdelen⁶

¹Mersin University Faculty of Pharmacy, Department of Biochemistry, Mersin, Turkey

²Mersin University, Faculty of Medicine, Department of Ophthalmology, ³Department of Histology and Embryology,

⁶Department of Biostatistics Mersin, Turkey

⁴Toros University, Vocational School, Department of Medical Services and Techniques, Mersin, Turkey.

⁵Mersin University, Vocational School of Medical Services, Mersin, Turkey.

Cukurova Medical Journal 2018;43(Suppl 1):275-284

Abstract

Purpose: This study investigated the anti-inflammatory efficacy of topical application of a selective tyrosine kinase receptor inhibitor (TKI), Axitinib in experimental corneal neovascularization (CNV) model in rats. Vascular endothelial growth factor receptor 1 (VEGFR1), VEGFR2 and VEGFR3 were evaluated as angiogenic markers, nuclear factor kappa B (NF- κ B), tumor necrosis factor α (TNF α) and cyclooxygenase-2 (COX2) were determined as inflammatory markers and also histopathological evaluations were carried out.

Materials and Methods: Experimental CNV model was established by silver nitrate cauterization in right eye. 6 groups were included as Control; CNV; CNV+DMSO; CNV+0.04% Axitinib; CNV+0.08% Axitinib and CNV+0.24% Axitinib. The corneas were collected and VEGFR1, VEGFR2, VEGFR3, NF- κ B, TNF α and COX2 were measured by ELISA.

Results: Axitinib, significantly reduced corneal VEGFR1 and VEGFR2 compared to CNV. The most efficiency of Axitinib treatment was confirmed on VEGFR2 and especially with 0.04% dose. Increased NF- κ B and TNF α level were reduced by 0.04% Axitinib treatment compared to CNV and CNV+DMSO.

Conclusion: Axitinib may be suggested as a promising anti-inflammatory agent in CNV by suppressing corneal VEGFR1, VEGFR2, NF- κ B and TNF α , beside improving the histological pattern.

Key words: Axitinib, corneal neovascularization, VEGFR

Öz

Amaç: Bu çalışmada sıçanlarda deneysel kornea neovaskularizasyonu (CNV) modelinde bir selektif tirozin kinaz reseptör inhibitörü (TKI), Axitinib' in topikal uygulamasının anti-inflamatuar etkinliği araştırıldı. Vasküler endotelial büyüme faktörü reseptörü 1 (VEGFR1), VEGFR2 ve VEGFR3 anjiyojenik belirteçler olarak değerlendirildi, nükleer faktör kappa B (NF- κ B), tümör nekroz faktörü (TNF α) ve siklooksijenaz-2 (COX2) ise inflammatuar belirteçler olarak belirlendi ve ayrıca histopatolojik değerlendirmeler yapıldı.

Gereç ve Yöntem: Sıçanların sağ gözlerinde, gümüş nitrat katekizasyonu ile deneysel CNV modeli oluşturuldu. Kontrol; CNV; CNV+DMSO; CNV+% 0.04 Axitinib; CNV+% 0.08 Axitinib ve CNV+% 0.24 Axitinib olmak üzere çalışmaya 6 grup dahil edildi. Kornealar diseke edildi ve VEGFR1, VEGFR2, VEGFR3, NF- κ B, TNF α ve COX2 ELISA yöntemi ile ölçüldü.

Bulgular: Axitinib, CNV ile karşılaştırıldığında korneal VEGFR1 ve VEGFR2'yi anlamlı olarak azaldı. Axitinib tedavisinin en etkin sonuçları VEGFR2 üzerine ve özellikle % 0,04 dozunda saptandı. Artmış NF- κ B ve TNF α seviyesi % 0.04 Axitinib tedavisi ile CNV ve CNV+DMSO'ya göre azaldığı saptandı.

Sonuç: Axitinib, VEGFR1, VEGFR2, NF- κ B ve TNF α 'yı baskılayarak ve ayrıca histolojik paterni iyileştirerek kornea CNV de ümit verici bir anti-inflamatuar ajan olarak önerilebilir.

Anahtar kelimeler: Axitinib, kornea neovaskularizasyonu, VEGFR

INTRODUCTION

Axitinib (AG-013736) a novel, potent, small molecule, is a selective tyrosine kinase receptor inhibitor (TKI) which exerts its effects by preventing the binding of vascular endothelial growth factor (VEGF) to VEGF receptor 1 (VEGFR1), VEGFR2 and VEGFR3^{1,2} even in nanomolar concentrations³. Many recent clinical and nonclinical studies point out impact of axitinib on restraining of angiogenesis, vascular permeability, and blood flow^{4,5} and it is well known that axitinib is more potent and selective VEGFR inhibitor compared to other similar TKIs.^{6,7} Axitinib was approved by the US Food and Drug Administration (FDA) and several other countries in 2012 for the treatment of advanced metastatic renal cell carcinoma².

Corneal disorders is the third most common cause of blindness worldwide. Ischemia, chemical burns, infection, trauma, toxicity, allergy and inflammation cause corneal neovascularization^{8,9}. As cornea is naturally avascular under normal physiologic conditions, abnormal vascularization decreases corneal clarity and visual acuity by blocking the light due to the corneal scarring and leads permanent vision loss^{10,11}. CNV may also cause the subsequent penetrating keratoplasty^{12,13}. Recent studies have focused on treatment and investigation the underlying pathological process of CNV^{11,14,15}. Angiogenesis, formation of new vessels is common in corneal disorders and VEGF has been proven as one of the most effective mediator of angiogenesis^{16,17}. One of the most efficient treatment strategy of CNV is suppressing VEGF activity and alone or combined TKIs are widely used for this purpose^{8,11}.

Since, it is well known that angiogenesis contributes to inflammatory diseases¹⁸, we aimed to investigate the anti-inflammatory efficiency of topical application of Axitinib in experimental CNV model in rats. VEGFR1, VEGFR2 and VEGFR3 were evaluated as angiogenic markers, nuclear factor kappa B (NF- κ B), tumor necrosis factor α (TNF α) and cyclooxygenase-2 (COX2) were determined as inflammatory markers and also number of leucocytes, thickness of stroma, and total cornea were investigated.

MATERIALS AND METHODS

Seventy seven Wistar albino, healthy male rats

weighing 180–250 g and 6 to 8 weeks old were acquired from the Mersin University Animal Research Laboratory. Rats were included to this study after being acclimatized under standard conditions. All animals were housed in different eurostandard type 4 cages. They were acclimated at a constant temperature (25°C), relative humidity (55 \pm 8%) and with the realization of light–dark cycle (12:12 h). All animals were accessed to tap *water and* on standard diet was used. The study was approved by the Animal Experiments Local Ethics Committee in Mersin University (E.98156 2016/22).

Experimental model and treatment

Rats were assigned to six groups as Control (n=7), CNV (n=14), CNV+DMSO (n=14), CNV+0.04% Axitinib (n=14), CNV+0.08% Axitinib (n=14) and CNV+0.24% Axitinib (n=14). After anesthesia by intramuscular 90 mg kg⁻¹ ketamine hydrochloride and xylazine hydrochloride 7 mg kg⁻¹, an experimental CNV was formed by silver nitrate cauterization in right eyes in treatment groups. The silver nitrate sticks (25% potassium nitrate and 75% silver nitrate) were applied once for 10s to the corneal center and followed by washing immediately with 5mL saline for removing of residual chemicals.

Axitinib (AG 013736) purchased from Pfizer dissolved in DMSO. Treatment with axitinib eye drops of varying concentrations (0.04%, 0.08% and 0.24% respectively) were carried out four times a day for five days in right eye. Rats in Control group received tear drops via the same route for five days in their both eyes. Experimental protocol was ended at the fifth day and rats were sacrificed. The right eyes were dissected in for designated analysis. Seven right eyes were chosen randomly for biochemical evaluation, and whereas the other seven right eyes were used in histopathological investigations. Both of the eyes were dissected in Control group.

Burn stimulus response and Corneal Neovascularization Score

Burn stimulus response and CNV were assessed (OPMI® pico). CNV was scored as Grade 0: No visible vascularization. Grade 1: Annular vascularization at 1/5 distance to burn area. Grade 2: Annular vascularity at 2/5 distance to burn area. Grade 3: Annular vascularity 3/5 distance to burn area. Grade 4: Annular vascularization 4/5 distance to burn area. Grade 5: Annular vascularization to

the burn site 5/5. Besides burn stimulus response was scored as; 0: No blister formation, darkened burn area, 1: White, opaque and small blister formation with raised slightly above the corneal surface, 2: Medium blister formation with raised moderately above the corneal surface, 3: Large blister formation with raised seriously above the corneal surface.

Preparation of cornea homogenates and evaluation of protein content

Corneas were homogenized in lysis buffer and then centrifugation of the samples were carried out at $14.000 \times g$ for 10 min at 4 °C. The cytoplasmic and nuclear proteins were removed and COX2 enzyme activity and VEGFR1, VEGFR2, VEGFR3, NF- κ B and TNF α levels were determined in collected supernatants. Protein contents were assayed according to Lowry et al. method¹⁹.

Assessments of VEGFR1, VEGFR2 and VEGFR3 levels

Corneal VEGFR1, VEGFR2 and VEGFR3 levels were estimated by sandwich enzyme linked immunoassay (ELISA) kit purchased from Shanghai Sunred Biological Technology Co., Ltd. The absorbance of the samples were determined for VEGFR1, VEGFR2 and VEGFR3 at 450nm in a ELISA plate reader. VEGFR1, VEGFR2 and VEGFR3 results were expressed as ng/mg protein.

Assessments of NF- κ B, TNF α and COX2 levels

NF- κ B, TNF α and COX2 were assayed by ELISA kit purchased from Shanghai Sunred Biological Technology Co., Ltd as and procedure was carried out as described in the manufacturer's guidance. The intensity of color of the samples were determined for NF- κ B, TNF α and COX2 at 450 nm using ELISA plate reader. NF- κ B, TNF α and COX2 results were stated in ng/mg protein.

Light microscopic analysis of the cornea for histopathological features

The rat eyes were gathered and fixed in 10% buffered formaldehyde for 48 hours. The tissues were then routinely processed and cut at 5- μ m thickness. Hematoxylin & eosin stain was performed

for histological examinations. Sections were examined under a light microscope (Olympus BX50). Photomicrographs were taken from 10 randomly chosen areas by a camera attached to the microscope. The thickness of corneal stroma and total cornea were measured by using a software (LC Micro ©). Leukocyte infiltration was also examined. For this purpose, leukocytes were counted in sections from each cornea starting from limbal regions at high-power field (x40 objective).

Statistical analysis

Data of the study was analyzed using STATISTICA Version 13.3. Shapiro Wilk test was used to determine for normal distribution and Levene statistic were used for controlling the homogeneity of the variants of the groups. The ANOVA test, which is a parametric test, was used to compare the mean of multiple independent groups with normal distribution fit and group variance homogeneity. The Duncan test was used from the post hoc tests to determine the groups that differed in this comparison.

The Welch test was used for parametric tests in order to compare the mean of two independent groups with those of normal distribution but not group variances heterogeneity. The Games-Howell test was used from the post hoc tests to determine the groups that differ in the result of this comparison. For those who did not have normal distribution disagreement, more than two independent group medians were compared with Kruskal-Wallis test. The statistical significance level (p) for all comparisons was taken as <0.05.

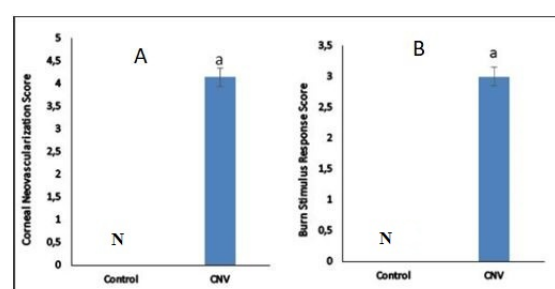


Figure 1. Evaluations of burn stimulus response and CNV Score.

Values are expressed as means \pm SD. $p < 0.05$ was considered to be significant. a Significantly different from Control.

RESULTS

Established burn stimulus response and CNV were clinically scored. As shown in Figure 1 A and B; burn stimulus response and CNV were significantly occurred in CNV group compared to control ($p < 0.05$) (Figure 1 A, B).

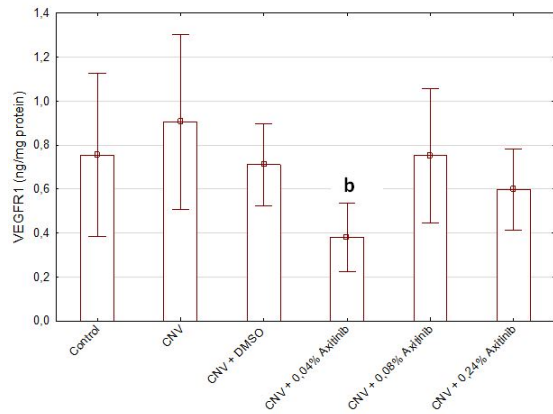


Figure 2. Effects of Axitinib on VEGFR1 in CNV experimental model. Values are expressed as means±SD. $p < 0.05$ was considered to be significant. ^b significantly different from CNV.

The effects of Axitinib, a multi-target tyrosine kinase inhibitor were assessed on corneal VEGFR1, VEGFR2 and VEGFR3.

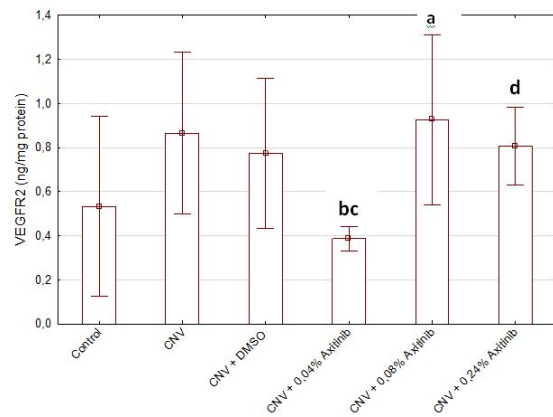


Figure 3. Inhibitory effect of Axitinib on VEGFR2 in CNV experimental model. Values are expressed as means±SD. $p < 0.05$ was considered to be significant. ^a Significantly different from Control, ^b significantly different from CNV, ^c significantly different from CNV+DMSO and ^d significantly different from CNV+0.04% Axitinib.

The most efficiency of axitinib treatment was confirmed on VEGFR2 and especially with 0.04% dose. VEGFR1 level was significantly reduced by

0.04% Axitinib treatment compared to CNV ($p < 0.05$) (Figure 2).

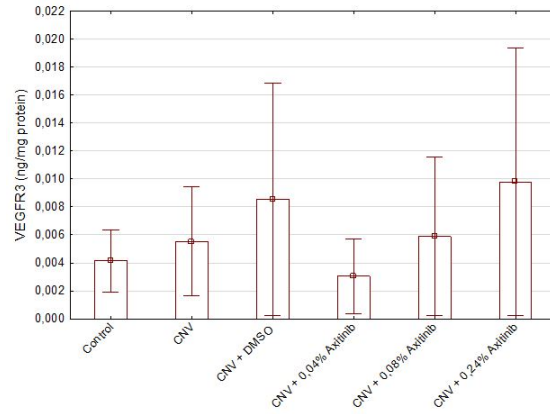


Figure 4. None significant effect was observed on VEGFR3 with Axitinib treatment. Values are expressed as means±SD. $p < 0.05$ was considered to be significant.

0.04% Axitinib treatment also significantly decreased VEGFR2 compared to both CNV and CNV+DMSO groups ($p < 0.05$). Interestingly, treatment with 0.08% Axitinib induced VEGFR2 levels compared to Control ($p < 0.05$) and besides 0.24% Axitinib treatment also augmented VEGFR2 levels compared to 0.04% Axitinib dose ($p < 0.05$) (Figure 3).

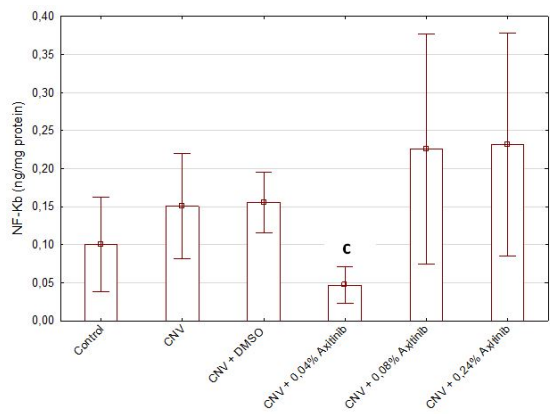


Figure 5. Effects of Axitinib on NF-kappa B in CNV experimental model. Values are expressed as means±SD. $p < 0.05$ was considered to be significant. ^c significantly different from CNV+DMSO.

While 0,04% Axitinib treatment suppressed VEGFR2 expression, 0.08% and 0.24% Axitinib exerted converse effect by inducing VEGFR2 levels. Although the results were not significant, VEGFR3

levels increased in both CNV and CNV+DMSO groups and these increases were reduced by 0.04% Axitinib treatment. Similar to VEGFR1 and VEGFR2 0.08% and 0.24% Axitinib treatments also induced the level of VEGFR3 (Figure 4).

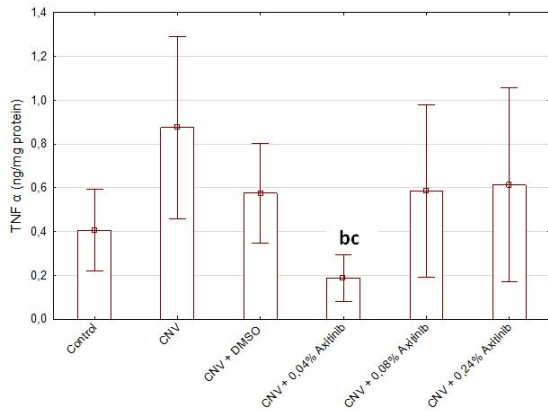


Figure 6. Effects of Axitinib on TNF α levels in CNV experimental model.

Values are expressed as means \pm SD. $p < 0.05$ was considered to be significant. ^b significantly different from CNV and ^c significantly different from CNV+DMSO.

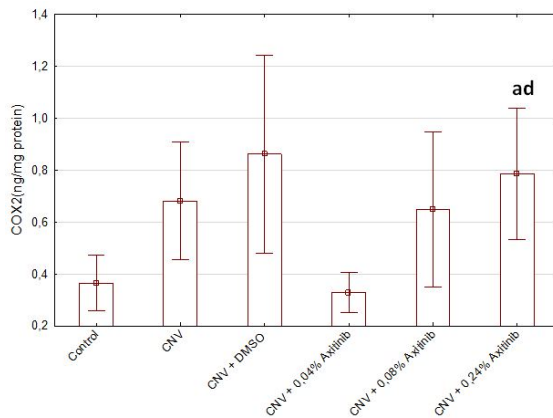


Figure 7. Effects of Axitinib on COX2 in CNV experimental model.

Values are expressed as means \pm SD. $p < 0.05$ was considered to be significant. ^a Significantly different from Control and ^d significantly different from CNV+0.04% Axitinib.

We evaluated NF- κ B, TNF α and COX2 levels as inflammatory markers in CNV experimental model. Although increased NF- κ B levels were observed in both CNV and CNV+DMSO groups (0.101 \pm 0.059 vs 0.151 \pm 0.066 and 0.101 \pm 0.059 vs 0.155 \pm 0.043 respectively), these were not significant. Increased NF- κ B level was reduced by 0.04% Axitinib

treatment compared to CNV+DMSO ($p < 0.05$) (Figure 5).

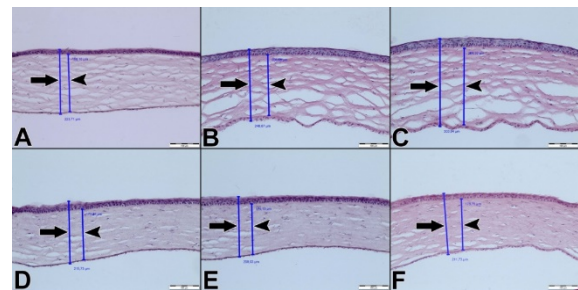


Figure 8. Representative photomicrographs for measurement of thickness of stroma (arrowhead) and cornea (thick arrow) (H&E staining) in control group and study groups

(A) Control, (B) CNV, (C) CNV + DMSO, (D) CNV + 0.04% Axitinib (E) CNV + 0.08% Axitinib (F) CNV + 0.24% Axitinib ($\times 100$, scale bar= 100 μ m).

0.04% Axitinib treatment was also effective significantly in reducing TNF α compared to both CNV and CNV+DMSO groups ($p < 0.05$) (Figure 6). Although 0.04% Axitinib treatment reduced COX2 levels compared to both CNV and CNV+DMSO groups these reductions were not significant. Again dose dependent augmentation was observed in COX2 level and moreover 0.24% Axitinib treatments significantly increased COX2 when compared to both Control and 0.04% Axitinib treatment ($p < 0.05$) (Figure 7).

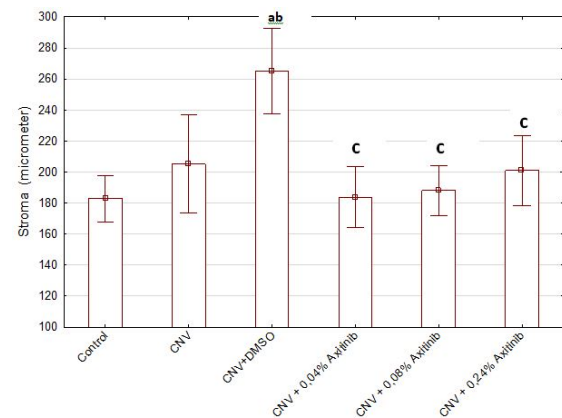


Figure 9. Effects of Axitinib on stroma in CNV model

Values are expressed as means \pm SD. $p < 0.05$ was considered to be significant. ^a Significantly different from Control, ^b significantly different from CNV and ^c significantly different from CNV+DMSO

Histopathological examination

The histological evaluation showed that the corneal stroma and total cornea thickness were significantly altered between the groups (Figure 8). CNV+DMSO leads to a significant increase in both stroma and the thickness of total cornea when compared with the control and CNV groups ($p < 0.001$). These increases were diminished by axitinib treatment at different doses ($p < 0.001$) (Figure 9 and 10).

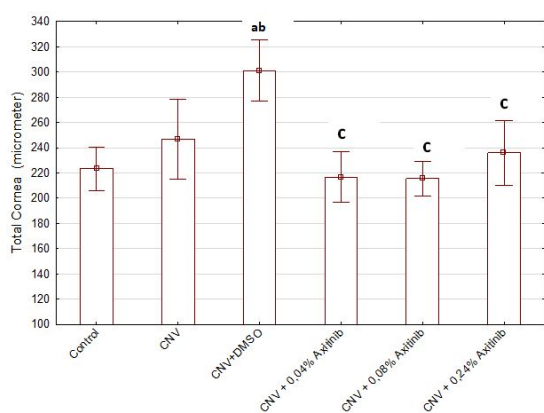


Figure 10. Effects of Axitinib on total cornea thickness in CNV model.

Values are expressed as means±SD. $p < 0.05$ was considered to be significant. ^a Significantly different from Control, ^b significantly different from CNV and ^c significantly different from CNV+DMSO.

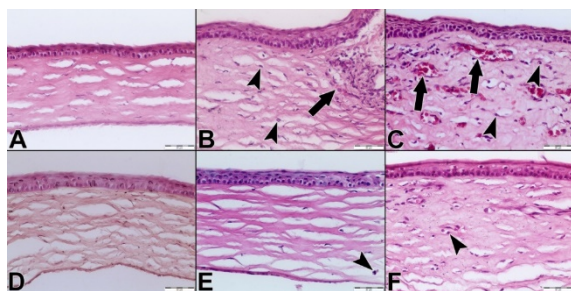


Figure 11. Representative photomicrographs for leukocyte infiltration (arrowhead) (H&E staining) in control group and study groups. (A) Control, (B) CNV, (C) CNV + DMSO, (D) CNV + 0.04% Axitinib (E) CNV + 0.08% Axitinib (F) CNV + 0.24% axitinib. Newly formed blood vessels were also shown (thick arrow) ($\times 200$, scale bar=50 μm).

Leukocyte infiltration was also examined between the groups (Figure 11). There was a significant increase in leukocyte number in both CNV and CNV+DMSO groups compared to the control

group ($p < 0.001$). Axitinib treatment reduced the number of leukocytes and prevent inflammation in different doses of axitinib ($p < 0.005$) (Figure 12).

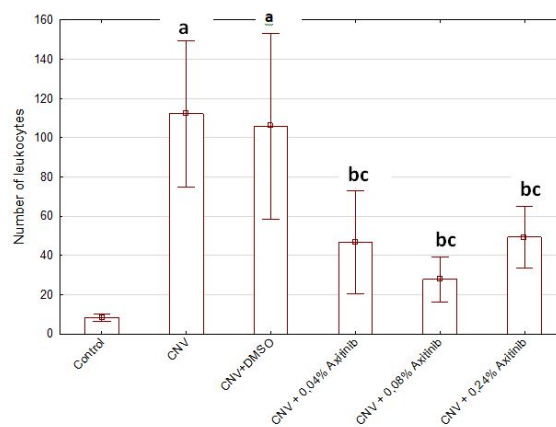


Figure 12. Leukocyte infiltration was reduced by topical Axitinib treatments.

Values are expressed as means±SD. $p < 0.05$ was considered to be significant. ^a Significantly different from Control, ^b significantly different from CNV and ^c significantly different from CNV+DMSO.

DISCUSSION

The results of the present study revealed that axitinib, a selective TKI inhibitor reduced inflammation in experimental CNV model. The anti-inflammatory effect of axitinib was demonstrated by reducing NF- κ B and TNF α . In addition, as a secondary finding, also increased number of leukocytes, thickness of stroma, and total cornea were attenuated by axitinib.

Axitinib is a potent TKI inhibitor which has been approved by FDA for advanced renal carcinoma treatment, prevent angiogenesis and vascular permeability, as well as induce apoptosis². Angiogenic mediators such as VEGF and VEGFRs play dominant role in CNV and VEGF was significantly increased in vascularized corneas²⁰. Angiogenesis is not only essential for promoting new blood vessel formation but also for inflammation^{21,22}. Since inflammation related with angiogenic pathway¹⁸ therefore we investigated the anti-inflammatory effects of axitinib, selective inhibitor of VEGFR tyrosine kinases in experimental CNV model.

We found out that increased VEGFR1 and VEGFR2 levels were significantly reduced by 0.04%

Axitinib treatment compared to CNV. Among in three receptors, the most efficient results were observed in VEGFR-2. VEGFR-2 has been reported as a selective target of axitinib versus other receptor tyrosine kinases in angiogenesis process.

Besides it was mentioned that kinase activity of VEGFR2 was 10-fold stronger than VEGFR1²³. Although the results were not significant, increased VEGFR3 was also suppressed by 0.04% Axitinib. VEGFR3 is known as a regulator of embryonic angiogenesis and lymphangiogenesis^{24,25}. The insignificant effect of axitinib on corneal VEGFR3 may be the result of this attribution. Riquelme et al. also demonstrated topical administration of different axitinib concentrations inhibited CNV by preventing both VEGF and platelet-derived growth factor pathways²⁶. It was indicated that not only the topical administration, oral use of axitinib also prevented laser-induced choroidal neovascularization²⁷. In addition to oral and topical applications of axitinib, it was represented that development of nanowafer was more effective in preventing CNV comparing topical eye drop use²⁸.

In this study increased NF- κ B level was reduced by 0.04% Axitinib treatment compared to CNV+DMSO. It is known that TNF α prompts NF- κ B transcription²⁹. Depending on our results, increased NF- κ B may be induced by TNF α . NF- κ B activation is regulated several various subunits such as proinflammatory cytokines, growth factors, bacterial lipopolysaccharides and antigen receptors. Both canonical and noncanonical pathways of NF- κ B activation conduces to the pathogenesis of several inflammatory and immune disorders³⁰. NF- κ B is the one of the important mediator which regulates cells of the vasculature³¹. It was also indicated that NF- κ B is a critical role formation of CNV by promoting the expression of metalloproteinase³². Several studies have demonstrated that NF- κ B pathway signaling is necessary for CNV³³⁻³⁵.

We found that 0.04% Axitinib treatment was significantly reduced TNF α compared to both CNV and CNV+DMSO groups. Expression of TNF α was indicated in epithelium, stroma and endothelium of cornea³⁶. Although the role of TNF α is CNV is unclear, Lu P. Et al indicated that CNV was suppressed in TNF receptor 1-deficient (TNF-Rp55-KO) mice by reducing expression of VEGF and iNOS by infiltrating macrophages. Besides, CNV was significantly diminished by the

application of TNF α antagonist or anti- TNF α antibodies³⁷. Similar to our results, proinflammatory cytokines such as interleukin-6, TNF α , and interferon- γ were also inhibited by Axitinib in melanoma by promoting antitumor immunity³⁸.

Although 0.04% Axitinib treatment reduced COX2 levels compared to both CNV and CNV+DMSO groups, these reductions were not significant. Again dose dependent augmentation was observed in COX2 level and moreover 0.24% Axitinib treatments significantly increased COX2 compared to both Control and 0.04% Axitinib treatment. Yamada et al. pointed out that COX2 stimulation in with silver/potassium nitrate cauterized corneas enhanced prostaglandin synthesis resulting with corneal angiogenesis³⁹. Inflammatory cytokines such as interleukin-1 β and TNF α augment COX2 expression in several human cell types and COX2 is stated as a key enzyme for inflammatory cytokine-induced angiogenesis^{40,41}. On the other hand, Amico et al. affirmed that differential expression of COX2 was observed in during wound healing of the cornea⁴². Insignificant results of us may be due to the differential expression of COX2 in the wound healing process.

Histopathological investigations also carried out by estimation of corneal stroma and total cornea thickness. It was found that CNV+DMSO lead to a significant increase in both stroma and the thickness of total cornea when compared with the control group and CNV. These increases were diminished by axitinib treatment at different doses. Corneal stroma is the thickest layer of the cornea with a critical role in clear visual function⁴³. The increase of the thickness in stroma and total cornea was thought to be related with edema formation. Corneal edema is always precedence of CNV with swelling of cornea⁴⁴.

There was a significant increase in leukocyte number in both CNV and CNV+DMSO groups compared to the control group. Axitinib treatment reduced the number of leukocytes and prevent inflammation in different doses of axitinib. As evidenced in several studies leukocytes have considerable role in corneal haemangiogenesis and lymphangiogenesis^{45,46}. It has been suggested that TNF α may lead release of angiogenic factors which induce angiogenesis process in CNV formation by enhancing edema, vasodilatation and leukocyte recruitment⁴⁷. According to our results induced TNF α may lead to increase leukocytes.

Although some of them were not significant same pattern was observed in high doses of axitinib treatment compared to low dose of axitinib in investigated analyzes. 0,04% Axitinib treatment was observed to be more beneficial. Giddabasappa et al. also mentioned that lower dose of axitinib significantly inhibited laser-induced retinal and choroidal neovascularization both in in vitro and in vivo models⁴⁸. Biocompatibility of axitinib, pazopanib, and sorafenib were investigated in ocular cells of the anterior and posterior segments, besides organ-cultured donor corneas. High doses were appeared more effective on cellular viability and induction of cell death⁴⁹. When these results are taken into account, it is observed that dose adjustment is important in axitinib use.

In summary, impact outcomes have been found for axitinib in reducing VEGFR1, VEGFR2, NF- κ B and TNF α , beside ameliorating in number of leucocytes, thickness of stroma, and total cornea in CNV experimental model. Axitinib may be suggested as a promising anti-inflammatory agent in CNV.

Acknowledgment

This research was funded by Mersin University, Research Foundation, Mersin, Turkey (Grant no. 2016-2-AP3-1922).

REFERENCES

- Chen Y, Tortorici MA, Garrett M, Hee B, Klamerus KJ, Pithavala YK. Clinical pharmacology of axitinib. *Clin Pharmacokinet*. 2013;52:713-25.
- Wei N, Liang J, Peng S, Sun Q, Dai Q, Dong M. Design, synthesis, and biological evaluation of axitinib derivatives. *Molecules*. 2018;23:747.
- Hu-Lowe DD, Zou HY, Grazzini ML, Hallin ME, Wickman GR, Amundson K et al. Nonclinical antiangiogenesis and antitumor activities of axitinib (AG013736), an oral, potent, and selective inhibitor of vascular endothelial growth factor receptor tyrosine kinases 1, 2, 3. *Clin. Cancer Res*. 2008;14:7272-83.
- Li KL, Wilmes IJ, Henry RG, Pallavicini MG, Park JW, Hu-Lowe DD et al. Heterogeneity in the angiogenic response of a Bt474 human breast cancer to a novel vascular endothelial growth factor-receptor tyrosine kinase inhibitor: assessment by voxel analysis of dynamic contrast-enhanced MRI. *J Magn Reson Imaging*. 2005;22:511-9.
- Liu G, Rugo HS, Wilding G, McShane TM, Evelhoch JL, Ng C et al. Dynamic contrast-enhanced magnetic resonance imaging as a pharmacodynamic measure of response after acute dosing of ag-013736, an oral angiogenesis inhibitor, in patients with advanced solid tumors: results from a phase I study. *J Clin Oncol*. 2005;23:5464-73.
- Atkins MB, Plimack ER, Puzanov I, Fishman MN, McDermott DF, Cho DC et al. Axitinib in combination with pembrolizumab in patients with advanced renal cell cancer: A non-randomised, open-label, dose-finding, and dose-expansion phase 1b trial. *Lancet Oncol*. 2018;19:405-15.
- Bellesoeur A, Carton E, Alexandre J, Goldwasser F, Huillard O. Axitinib in the treatment of renal cell carcinoma: Design, development, and place in therapy. *Drug Des Dev Ther*. 2017;11:2801-11.
- Sepehr F, Amir AA, Sharareh S. Therapeutic approaches for corneal neovascularization. *Eye Vis (Lond)*. 2017;4:28.
- Chang JH, Gabison EE, Kato T, Azar DT. Corneal neovascularization. *Curr Opin Ophthalmol*. 2001;12:242-9.
- Bachmann B, Taylor RS, Cursiefen C. The association between corneal neovascularization and visual acuity: a systematic review. *Acta Ophthalmol*. 2013;91:12-9.
- Liu X, Wang S, Wang X, Liang J, Zhang Y. Recent drug therapies for corneal neovascularization. *Chem Biol Drug Des*. 2017;90:653-64.
- Dana MR, Schaumberg DA, Kowal VO, Goren MB, Rapuano CJ, Laibson PR et al. Corneal neovascularization after penetrating keratoplasty. *Cornea*. 1995;14:604-9.
- Cursiefen C, Kuchle M, Naumann GO. Angiogenesis in corneal diseases: histopathologic evaluation of 254 human corneal buttons with neovascularization. *Cornea*. 1998;17:611-3.
- Gupta D, Illingworth C. Treatments for corneal neovascularization: a review. *Cornea*. 2011;30:927-38.
- Papathanassiou M, Theodoropoulou S, Analitis A, Tzonou A, Theodossiadis PG. Vascular endothelial growth factor inhibitors for treatment of corneal neovascularization: a meta-analysis. *Cornea*. 2013;32:435-44.
- Gan L, Fagerholm P, Palmblad J. Vascular endothelial growth factor (VEGF) and its receptor VEGFR-2 in the regulation of corneal neovascularization and wound healing. *Acta Ophthalmol Scand*. 2004;82:557-63.
- Philipp W, Speicher L, Humpel C. Expression of vascular endothelial growth factor and its receptors in inflamed and vascularized human corneas. *Invest Ophthalmol Vis Sci*. 2000;41:2514-22.
- Carmeliet P. Angiogenesis in health and disease. *Nat Med*. 2003;9:653-60.
- Lowry OH, Rosebrough NJ, Farr AL, Randall JR. Protein measurement with the folin phenol reagent. *J Biol Chem*. 1961;193:265-75.
- Zheng M, Deshpande S, Lee S, Ferrara N, Rouse BT.

- Contribution of vascular endothelial growth factor in the neovascularization process during the pathogenesis of herpetic stromal keratitis. *J Virol*. 2001;75:9828-35.
21. Lin WW, Karin M. A cytokine-mediated link between innate immunity, inflammation, and cancer. *J Clin Invest*. 2007;117:1175-83.
 22. Ono M. Molecular links between tumor angiogenesis and inflammation: inflammatory stimuli of macrophages and cancer cells as targets for therapeutic strategy. *Cancer Sci*. 2008;99:1501-6.
 23. Sondak VK, Smalley KSM, Kudchadkar R, Gripton S, Kirkpatrick P. Ipilimumab. *Nat Rev Drug Discov*. 2011;10:411-2.
 24. Waltenberger J, Claesson-Welsh L, Siegbahn A, Shibuya M, Heldin CH. Different signal transduction properties of KDR and Flt1, two receptors for vascular endothelial growth factor. *J Biol Chem*. 1994;269:26988-95.
 25. Shibuya M, Claesson-Welsh L. Signal transduction by VEGF receptors in regulation of angiogenesis and lymphangiogenesis. *Exp Cell Res*. 2006;312:549-60.
 26. Lledó Riquelme M, Campos-Mollo E, Fernández-Sánchez L. Topical axitinib is a potent inhibitor of corneal neovascularization. *Clin Exp Ophthalmol*. 2018; doi:10.1111/ceo.13333.
 27. Kang S, Roh CR, Cho WK, Park KC, Yang KJ, Choi HS et al. Antiangiogenic effects of axitinib, an inhibitor of vascular endothelial growth factor receptor tyrosine kinase, on laser-induced choroidal neovascularization in mice. *Curr Eye Res*. 2013;38:119-27.
 28. Yuan X, Marcano DC, Shin CS, Hua X, Isenhardt LC, Pflugfelder SC et al. Ocular drug delivery nanowafer with enhanced therapeutic efficacy. *ACS Nano*. 2015;9:1749-58.
 29. Kumar A, Takada Y, Boriek AM, Aggarwal BB. Nuclear factor-kappaB: Its role in health and disease. *J Mol Med (Berl)*. 2004;82:434-48.
 30. Liu T, Zhang L, Joo D, Sun SC. NF- κ B signaling in inflammation. *Signal Transduct Target Ther*. 2017;2:17023.
 31. De Martin R, Hoeth M, Hofer-Warbinek R, Schmid JA. The transcription factor NF-kappa B and the regulation of vascular cell function. *Arterioscler Thromb Vasc Biol*. 2000;20:E83-8.
 32. Kim H, Koh G. Lipopolysaccharide activates matrix metalloproteinase-2 in endothelial cells through an NF-kappaB-dependent pathway. *Biochem Biophys Res Commun*. 2000;269: 401-5.
 33. Yosbida A, Yosbida S, Isbibasbi T, Kuwano M, Inomata H. Suppression of retinal neovascularization by the NF-kB inhibitor pyrrolidine dithiocarbamate in mice. *Invest Ophthalmol Vis Sci*. 1999;40:1624-9.
 34. Zhang MC, Wang Y, Yang Y. The expression of nuclear factor kappa B in inflammation-induced rat corneal neovascularization. *Ocul Immunol Inflamm*. 2006;14:359-65.
 35. Jo N, Ogata N, Aoki M, Otsuji T, Morishita R, Kaneda Y et al. Effective transfection of a cis element "decoy" of the nuclear factor-kappaB binding site into the experimental choroidal neovascularization. *CurrEyeRes*. 2002;2:465-73.
 36. Mohan RR, Mohan RR, Kim WJ, Wilson SE. Modulation of TNF-alpha-induced apoptosis in corneal fibroblasts by transcription factor NF-kappaB. *Invest Ophthalmol Vis Sci*. 2000;41:1327-36.
 37. Lu P, Li L, Liu G, Baba T, Ishida Y, Nosaka M et al. Critical role of TNF-alpha-induced macrophage VEGF and iNOS production in the experimental corneal neovascularization. *Invest Ophthalmol Vis Sci*. 2012;53:3516-26.
 38. Zhang X, Fang X, Gao Z, Chen W, Tao F, Cai P et al. Axitinib, a selective inhibitor of vascular endothelial growth factor receptor, exerts an anticancer effect in melanoma through promoting antitumor immunity. *Anticancer Drugs*. 2014;25:204-11.
 39. Yamada M, Kawai M, Kawai Y, Mashima Y. The effect of selective cyclooxygenase-2 inhibitor on corneal angiogenesis in the rat. *Curr Eye Res*. 1999;19:300-4.
 40. Kuwano T, Nakao S, Yamamoto H, Tsuneyoshi M, Yamamoto T, Kuwano M et al. Cyclooxygenase 2 is a key enzyme for inflammatory cytokine-induced angiogenesis. *FASEB J*. 2004;18:300-10.
 41. Tsujii M, Kawano S, Tsuji S, Sawaoka H, Hori M, DuBois RN. Cyclooxygenase regulates angiogenesis induced by colon cancer cells. *Cell*. 1998;93:705-16.
 42. Amico C, Yakimov M, Catania MV, Giuffrida R, Pistone M, Enea V. Differential expression of cyclooxygenase-1 and cyclooxygenase-2 in the cornea during wound healing. *Tissue Cell*. 2004;36:1-12.
 43. Zhang L, Anderson MC, Liu CY. The role of corneal stroma: A potential nutritional source for the cornea. *J Nat Sci*. 2017;3:e428.
 44. Azar DT. Corneal angiogenic privilege: angiogenic and antiangiogenic factors in corneal avascularity, vasculogenesis, and wound healing (an American Ophthalmological Society thesis). *Trans Am Ophthalmol Soc*. 2006;104:264-302.
 45. Cursiefen C, Chen L, Borges LP, Jackson D, Cao J, Radziejewski C et al. VEGF-A stimulates lymphangiogenesis and hemangiogenesis in inflammatory neovascularization via macrophage recruitment. *J Clin Invest*. 2004;113:1040-50.
 46. Li S, Li B, Jiang H, Wang Y, Qu M, Duan H et al. Macrophage depletion impairs corneal wound healing after autologous transplantation in mice. *PLoS ONE*. 2013;8:e61799.
 47. Ferrari G, Bignami F, Rama P. Tumor necrosis factor- α inhibitors as a treatment of corneal hemangiogenesis and lymphangiogenesis. *Eye Contact Lens*. 2015;41:72-6.
 48. Giddabasappa A, Lalwani K, Norberg R, Gukasyan

- HJ, Paterson D, Schachar RA et al. Axitinib inhibits retinal and choroidal neovascularization in in vitro and in vivo models. *Exp Eye Res.* 2016;145:373–9.
49. Thiele S, Liegl RG, König S, Siedlecki J, Langer J, Eibl K et al. Multikinase inhibitors as a new approach in neovascular age-related macular degeneration (AMD) treatment: in vitro safety evaluations of axitinib, pazopanib and sorafenib for intraocular use. *Klin Monbl Augenheilkd.* 2013;230:247-54.