

Congenital coronary-pulmonary artery fistula originating from right and left coronary artery

Konjenital sağ ve sol koroner arter kaynaklı koroner-pulmoner arter fistülü

Ali Kemal Gür¹, Ahmet Karakurt², Yüksel Kaya²

ABSTRACT

Coronary artery fistula (CAF) is a rare congenital anomaly with an incidence of 1 in 50 000 live births. The fistula was observed at the right coronary artery in 53%, the left coronary artery in 42% and both coronary artery in 5% of the cases. Echocardiography examination in a 46 year-old woman with the symptoms of chest pain, palpitation and dyspnea revealed a severe mitral valve insufficiency and a moderate to severe tricuspid valve insufficiency. A CAF originating from the proximal part of the left anterior descending artery (LAD) and another fistula originating from osteal part of the right coronary artery (RCA) were detected by coronary angiography. Both fistulas were draining into the main pulmonary artery. The coronary artery fistula closed under cardiopulmonary by-pass. Mitral insufficiency originated from the posterior leaflet was diagnosed intra-operative exploration, and thereafter it was repaired with mitral annuloplasty including a quadrangular resection and use of a 32 No St Jude mitral ring. Tricuspid valve was repaired with Calangos Ring annuloplasty. Following six day hospital stay, the woman was discharged free of any symptom.

Key words: Dyspnea, double arteriovenous fistula, mitral and tricuspid insufficiency

INTRODUCTION

Fistula is defined as presence of blood flow from a high pressure point to a low pressure point [1]. Coronary artery fistula (CAF) is a rare anomaly and may be congenital, traumatic, or iatrogenic. The reported incidence is as 1 in 50 000 among live births [2]. The right coronary artery (RCA) or left coronary artery (LAD) are the most common site of origin, however, double CAF which were originated from these coronary arteries are rarely reported in

ÖZET

Koroner arter fistülü (CAF) , 50 000 canlı doğumda 1 görülen, nadir konjenital anomalidir. Fistül, vakaların %53 oranında sağ koroner arterde, %42 oranında sol koroner arterde ve %5 oranında iki koroner arterde görülmektedir. Göğüs ağrısı, çarpıntı ve nefes darlığı semptomlu 46 yaşında bayan hastanın ekokardiyografik muayenesinde, ileri mitral yetersizliği ve orta-ileri triküspid yetersizliği tespit edildi. Koroner anjiyografide, biri left anterior descending arter (LAD) proksimalinden ve diğeri right coronary artery (RCA) ostealinden kaynaklanan CAF tespit edildi. Her iki fistülde ana pulmoner artere drene olmaktadır. CAF kardiyopulmoner bypass altında kapatıldı. İntra-operatif eksplorasyonda mitral kapaktaki yetersizliğin posterior leaflete ait olduğunu tespit edildi ve sonrasında quadriangular rezeksiyon ve 32 No St Jude mitral halka kullanarak mitral annuloplasty yapıldı. Triküspid kapak Calangos Ring annuloplasty yapılarak tamir edildi. Her hangi bir semptomu olmayan hasta, altı gün hastanede takip edildikten sonra taburcu edildi.

Anahtar kelimeler: Dispne, çift arteriyovenöz fistül, mitral ve triküspit yetmezliği

adult [3]. We report very rare double CAF, which were originated LAD and RCA and its treatment option in a middle-aged woman, who was symptomatic for a long time.

CASE

A 46-year-old female patient was admitted to our clinic with symptoms of chest pain, palpitation and dyspnea. On her physical examination, she had 2/6 systolic murmur on mitral valve and a weak systole-

¹ Van Yüksek İhtisas Training And Research Hospital, Cardiovascular Surgery Clinics, Van, Turkey

² Kafkas University School of Medicine, Department of Cardiology, Kars, Turkey

Yazışma Adresi /Correspondence: Ali Kemal Gür,

Van Yüksek İhtisas Training And Research Hospital, Cardiovascular Surgery Clinics, Van, Turkey Email: dralikemal@gmail.com

Geliş Tarihi / Received: 15.04.2013, Kabul Tarihi / Accepted: 13.05.2013

Copyright © Dicle Tıp Dergisi 2013, Her hakkı saklıdır / All rights reserved

diastolic murmur on the left of midline. Electrocardiography revealed a ST elevation on derivations of DII, DIII, V1 and V2. Echocardiography revealed an ejection fraction of 40%, hypokinesia on inferoapical and septal parts of the left ventricle, moderate mitral insufficiency, moderate-severe tricuspid insufficiency and a systolic pulmonary artery pressure of 50 mmHg. A CAF originating from proximal part of LAD (Figure 1) and ostial part of RCA (Figure 2) was detected on coronary angiography and both were drained into main pulmonary artery. Coronary steal syndrome was considered and the patient was decided to be operated on. Operation was done following routine blood analysis and operation preparations had been completed.

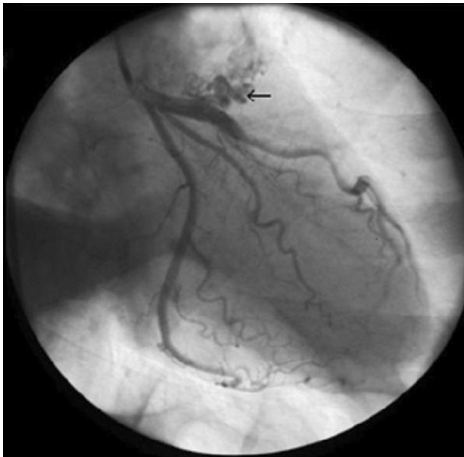

Figure 1. Coronary angiogram showing the CAF arising from the left anterior descending artery (LAD) to the main pulmonary artery (MPA)

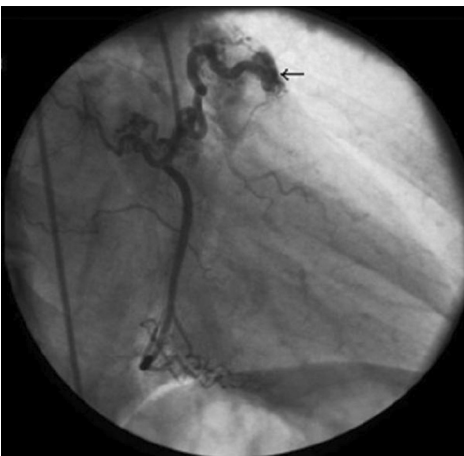

Figure 2. Coronary angiogram showing the CAF arising from the right coronary artery (RCA) to the main pulmonary artery (MPA)

Operative procedure

The patient was administered anesthesia in accordance with routine by-pass surgery protocol. Mediastinum was accessed through a standard median incision. After opening pericardium, an abnormal vascular structure which was originated from right coronary artery and preceded towards left over the main pulmonary artery was seen (Figure 3). Trill was palpated and the flow was seen to be continuous.

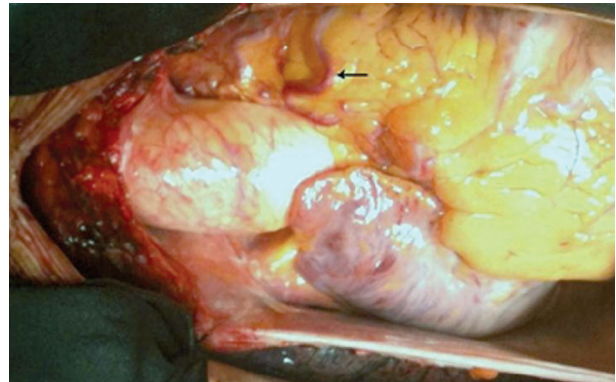


Figure 3. Intraoperative images show the right coronary-to-pulmonary artery fistula (black arrow).

Cardiopulmonary by-pass surgery was started following aortic and bicaval venous cannulation. The flow was blocked by placing medium clips from the parts of close to pulmonary artery to the CAF originating from RCA. Right atriotomy was done after snares had been tightened. Left atrium was accessed from fossa ovalis region located in interatrial septum. Insufficiency of mitral valve was detected to arise from posterior leaflet and repaired with quadrangular resection and 32 No St Jude mitral ring. Tricuspid valve was repaired by Calangos ring annuloplasty. Aortotomy was done and a longitudinal incision was done to the main pulmonary artery just above the level of valve in order to close the fistula on LAD and RCA. It was seen that there was not blood flow from the closed CAF to pulmonary artery when cardioplegic solution was given to RCA with the aid of ostial cannula of cardioplegic solution. Cardioplegic solution given to the left main coronary artery was seen to be drained at a level close to pulmonary valve (Figure 4). This ostium was closed with 5/0 prolene suture material. Pulmonary artery incision was closed after making sure that cardioplegic solution was not being drained to pulmonary artery. Cardiac incisions were closed. Cardiopulmonary by-pass was completed without

supportive therapy after the cardiac air had been evacuated. A transient epicardial pacemaker was placed. Mitral and tricuspid insufficiency was seen to be 1 (+) on postoperative echocardiography. The patient's symptoms improved and she was discharged. Echocardiography done on postoperative second month revealed 50% EF, 1(+) mitral insufficiency and 1(+) tricuspid insufficiency.

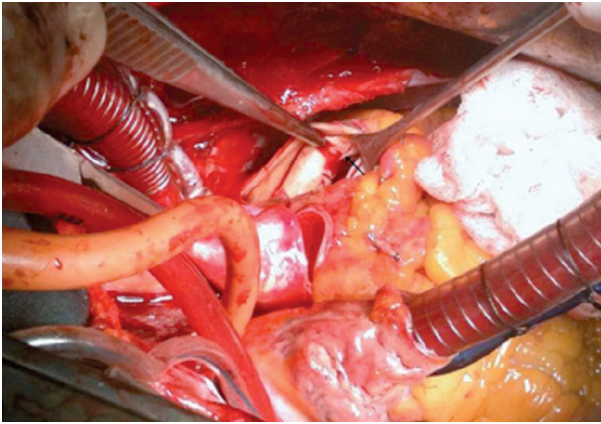


Figure 4. Intraoperative images show the left anterior descending artery (LAD) to the main pulmonary artery (MPA) (black arrow)

DISCUSSION

Fistula is defined as presence of blood flow from a high pressure point to a low pressure point [1]. CAF is a rare congenital anomaly, which was first defined by Krause in 18652. The first successful coronary fistula ligation was performed by Björk and Crafoord in 1947 [2]. Its incidence was found as 1 in 50 000 live births in a study of Schumacher et al. [3] CAF incidence was reported as 53% in right coronary artery, 42% in left coronary artery and 5% in both coronary arteries in a total of 50 000 cases. Of these fistulas, 92% are drained into right heart chambers and 8% into left heart chambers.

Although vast majority of the patients are asymptomatic, complaints begin to occur with the advancing age and due to other comorbidities (atherosclerotic heart disease, cardiac valve disease and cardiomyopathy). The main determinants of emergence of the symptoms are the size of the fistula and the amount of left-to-right shunting. The most common complaints include the symptoms like exertion dyspnea, tachycardia, fatigue, chest pain which mimic atherosclerotic heart disease. The reason for

this is the fistulas causing steal syndrome. Complications like congestive heart failure, myocardial infarction [4], bacterial endocarditis [5], cardiac tamponade due to the aneurismatic rupture of the fistula and pulmonary hypertension in advanced cases may be seen in untreated cases.

Diagnosis is made with coronary angiography done following a detailed echocardiography. Diagnosis of a CAF may be made incidentally even if the patients are asymptomatic. These lesions must be closed in the early period after diagnosis whether they are symptomatic or asymptomatic due to its complications. Closure may be done surgically or percutaneously. A consensus regarding the ideal treatment of fistula does not exist. Percutaneous closure was first performed by Reidy et al. [6] in 1983. Various techniques like coil embolization, plain microcoil or steel coils are being used for this purpose in recent years [7].

If the CAF is superficial and visible, the ligation or clipping of the beating heart is enough. The physician must wait for 10 min after blocking blood flow, ECG monitorization must be done carefully and trill must disappear [8]. However if the fistula is opened to one of the heart chambers and difficult to reach, closing the ostium with a prolene suture with the aid of cardiopulmonary by-pass, tangential arteriography and ligation and coronary artery by-pass grafting are among the treatment options [9]. In our case, CAFs were closed with cardiopulmonary by-pass due to the presence of CAF both on LAD and RCA, and coexistence of other cardiac pathologies.

In conclusion, CAF must be closed percutaneously or surgically in the early period to avoid the symptoms. We suggest the ligation or clipping on the beating heart if the CAF originating from LAD and RCA is superficial, visible or coexistence of other cardiac pathologies.

REFERENCES

1. Baim DS, Kline H, Silverman JF. Bilateral coronary artery-pulmonary artery fistulas. Report of five cases and review of the literature. *Circulation* 1982;65:810-815.
2. Dahida R, Copeland J, Butman SM. Myocardial ischemia and congestive heart failure from a left main to coronary sinus fistula. *Cardiol Rev* 2004;12:59-62.
3. Schumacher G, Roithmaier A, Lorenz HP, et al. Congenital coronary artery fistula in infancy and childhood: diagnostic and therapeutic aspects. *Thorac Cardiovasc Surg* 1997;45:287-294.

4. Elsayed H, Govindraj R, El-Dean I, et al. Acute coronary syndrome due to coronary artery-pulmonary artery fistula. *Asian Cardiovasc Thorac Ann* 2011;19:284.
5. Alkhulaifi AM, Horner SM, Pugsley WB, et al. Coronary artery fistulas presenting with bacterial endocarditis. *Ann Thorac Surg* 1995;60:202-204.
6. Reidy JF, Sowton E, Ross DN. Transcatheter occlusion of coronary to bronchial anastomosis by detachable balloon combined with coronary angioplasty at same procedure. *Br Heart J* 1983;49:284-287.
7. De Santis A, Cifarelli A, Violini R. Transcatheter closure of coronary artery fistula using the new Amplatzer vascular plug and a telescoping catheter technique. *J Cardiovasc Med* 2010;11:605-609.
8. Karabulut H, Toraman F, Alhan C, et al. Konjenital bilateral koroner-pulmoner arter fistülü. *TGKDCD* 1999;7:495-496.
9. Dimitrakakis G, Otto von Oppell U. Surgical treatment of coronary arteriovenous fistulas. *Interact Cardiovasc Thorac Surg* 2011;13:674-675.