







Evaluation of Early Healing and Complications Following Prescrotal and Scrotal Castration in Dogs

Zeynep CENGİZ¹ , Eser ÇAKMAKÇI^{1*} , Rahime YAYGINGÜL¹ , Zeynep BOZKAN ÜNAL¹ 

¹Aydın Adnan Menderes University, Faculty of Veterinary Medicine, Department of Surgery, Aydın, Türkiye

ABSTRACT

This study compared prescrotal and scrotal castration techniques in dogs with respect to operative time and early postoperative wound outcomes. Sixty clinically healthy male dogs (1–3 years) were randomly allocated to prescrotal (n=30) or scrotal (n=30) castration. Operative time was recorded, and surgical sites were evaluated on postoperative days 3, 7 and 14 for oedema, exudation and suture integrity using predefined ordinal scoring criteria. Operative time was significantly shorter in the scrotal group than in the prescrotal group (P<0.001). In contrast, early postoperative inflammatory scores were higher following scrotal castration. On day 3, oedema and exudation scores were greater in the scrotal group than in the prescrotal group (both P<0.001), and these differences remained significant on days 7 and 14 (oedema: P<0.001 and P=0.003; exudation: P<0.001 and P=0.011, respectively). Suture integrity on day 3 also differed between groups (P<0.001). By day 14, complete clinical wound healing was observed in all dogs. In summary, scrotal castration offers a markedly shorter operative time, whereas prescrotal castration is associated with lower early postoperative inflammatory signs. These findings suggest that incision location may predominantly influence the early inflammatory phase rather than the short-term healing outcome, and they may support clinical decision-making when balancing procedural efficiency against early postoperative tissue response.

Keywords: Castration, dog, wound healing

Köpeklerde Preskrotal ve Skrotal Kastrasyon Sonrası Erken İyileşme ve Komplikasyonların Değerlendirilmesi

ÖZET

Bu çalışma, köpeklerde preskrotal ve skrotal kastrasyon tekniklerini operasyon süresi ve erken dönem postoperatif yara bulguları açısından karşılaştırmak amacıyla yürütülmüştür. Yaşları 1–3 yıl arasında değişen, klinik olarak sağlıklı 60 erkek köpek rastgele olarak preskrotal (n=30) ve skrotal (n=30) kastrasyon gruplarına ayrılmıştır. Operasyon süresi kaydedilmiş ve cerrahi alanlar postoperatif 3., 7. ve 14. günlerde ödem, eksudasyon ve sütür bütünlüğü açısından önceden tanımlanmış ordinal skorlama kriterleri kullanılarak değerlendirilmiştir. Skrotal grupta operasyon süresi preskrotal gruba kıyasla anlamlı derecede daha kısa bulunmuştur (P<0,001). Buna karşılık, erken postoperatif dönemde inflamatuvar bulgular skrotal kastrasyon sonrasında daha belirgin olarak saptanmıştır. Postoperatif 3. günde skrotal grupta ödem ve eksudasyon skorları preskrotal gruba göre daha yüksek bulunmuş (her ikisi için P<0,001) ve bu farklılıklar 7. ve 14. günlerde de anlamlılığını korumuştur (ödem: sırasıyla P<0,001 ve P=0,003; eksudasyon: sırasıyla P<0,001 ve P=0,011). Ayrıca 3. gündeki sütür bütünlüğü de gruplar arasında anlamlı farklılık göstermiştir (P<0,001). Ondördüncü günde tüm köpeklerde klinik olarak tam yara iyileşmesi gözlenmiştir. Özetle, skrotal kastrasyon belirgin derecede daha kısa bir operasyon süresi sağlarken, preskrotal kastrasyon erken postoperatif inflamatuvar bulguların daha düşük olmasıyla ilişkilidir. Bu bulgular, insizyon lokalizasyonunun esas olarak erken inflamatuvar fazı etkilediğini, kısa dönem iyileşme sonucunu ise belirleyici ölçüde etkilemediğini düşündürmekte olup; klinisyenlerin prosedürel verimlilik ile erken postoperatif doku yanıtı arasındaki dengeyi gözeterek cerrahi teknik seçimine katkı sağlayabilir.

Anahtar Kelimeler: Kastrasyon, köpek, yara iyileşmesi

*Corresponding Author: Eser ÇAKMAKÇI, Aydın Adnan Menderes University, Faculty of Veterinary Medicine, Department of Surgery, Aydın, Türkiye. eser.cakmakci@adu.edu.tr

Received Date: 25.11.2025 - Accepted Date: 16.02.2026

DOI: 10.53913/aduveterinary.1830389

Introduction

Castration is among the most frequently performed surgical procedures in male dogs and remains a cornerstone of population control and preventive veterinary care. The surgical approach selected can influence both procedural efficiency and the nature of early postoperative tissue responses. The two principal techniques, prescrotal and scrotal castration, each present distinct advantages and limitations with respect to operative time, wound healing, and postoperative comfort (MacPhail, 2013; Hamilton et al., 2014; Van Goethem, 2016).

Available evidence suggests that, within the first 24 hours after surgery, scrotal incisions perform at least no worse than prescrotal incisions and may be associated with a reduction in mean operative time. However, robust comparative data extending beyond the immediate postoperative period, particularly beyond the first postoperative week, remain limited (Brunn, 2022). Large shelter-based cohorts and programmatic guidelines further indicate that both approaches are generally associated with low overall complication rates when strict aseptic technique, standardized perioperative care, and appropriate analgesia are applied. These sources emphasize that technique selection should be guided by patient conformation, surgeon experience, and the clinical setting rather than incision site alone (Kreisler et al., 2018; Romagnoli et al., 2024; ASPCA, 2025).

Conversely, clinical series and surgical textbooks note that incision placement within the dependent and highly mobile scrotum may predispose to postoperative swelling, bruising, and local discomfort, whereas prescrotal placement may mitigate early oedema and yield more favorable cosmetic healing when meticulous haemostasis and tension control are achieved (MacPhail, 2013; Hamilton et al., 2014). In parallel with contemporary efforts to minimize tissue handling and suture burden, modern refinements such as sutureless or reduced-manipulation techniques have been associated with low early complication rates while preserving procedural efficiency (Miller et al., 2018; Kim and Jeong, 2020).

Despite these observations, direct prospective comparisons that extend beyond the first few postoperative days and systematically assess early inflammatory wound changes using standardized clinical parameters remain scarce. In particular, there is a lack of controlled studies evaluating whether short-term differences in oedema, exudation, and suture-related irritation persist through the early healing phase and how these differences relate to operative time under routine clinical conditions.

Therefore, the objective of the present study was to compare prescrotal and scrotal castration techniques in dogs with respect to operative time and early postoperative wound outcomes over a 14-day follow-up period. We hypothesized that scrotal castration would result in a shorter operative time, whereas prescrotal castration would be associated with lower early postoperative inflammatory signs, without a clinically relevant difference

in short-term wound healing by the end of the follow-up period.

Materials and Methods

This randomized controlled study included 60 clinically healthy, mixed-breed male dogs aged 1–3 years. Dogs were allocated in a 1:1 ratio to prescrotal castration ($n = 30$) or scrotal castration ($n = 30$). Written informed consent was obtained from all owners prior to enrolment. The study protocol was approved by the Aydın Adnan Menderes University Institutional Animal Experiments Local Ethics Committee (Approval No. 64583101/2025/157; 06 November 2025), and all procedures were conducted in accordance with applicable national and international animal welfare guidelines.

Dogs were considered clinically healthy based on a standardized preoperative physical examination, including general attitude and body condition, rectal temperature, auscultation of the heart and lungs, and mucous membrane assessment/capillary refill time.

Group allocation was performed using a predefined computer-generated randomization list prepared prior to enrolment (1:1 allocation). All surgical procedures were performed by the same surgeon under standardized aseptic conditions. Postoperative clinical evaluations were performed by a single veterinarian according to a predefined assessment protocol.

Anaesthesia Protocol

Dogs were premedicated with xylazine hydrochloride (Rompun® 2%, Elanco Animal Health, USA) at 1–2 mg/kg intramuscularly. Approximately 10 minutes later, anaesthetic induction was achieved with ketamine (Ketasol® 10%, Interhas, Türkiye) at 5–10 mg/kg. The xylazine–ketamine combination has been reported as a safe and effective protocol in dogs when used appropriately (Silva et al., 2020). Dogs were not intubated and were allowed to breathe spontaneously; supplemental oxygen was not routinely administered. Intraoperative monitoring and supportive care were provided in accordance with the routine institutional anaesthesia and perioperative monitoring protocol to maintain clinically stable parameters throughout the procedure. Apnoea requiring rescue intervention was not observed.

Surgical Technique

Hair removal was performed using electric clippers (no razor shaving) immediately prior to antiseptic preparation. The surgical field was prepared using 0.05% chlorhexidine gluconate solution (Hibitanol®, Kimpa, Türkiye) for antisepsis. Dogs were positioned in dorsal recumbency in both groups.

Prescrotal Approach;

A 2–3 cm skin incision was made on the ventral midline immediately cranial to the scrotum. Subcutaneous tissues were bluntly dissected to access the spermatic cord structures, and each testis was exteriorized sequentially.

Each spermatic cord was ligated using a double ligature technique with polyglactin 910 (Vicryl®, USP 2-0; Ethicon, Johnson & Johnson, USA), followed by transection and removal of the testes. Haemostasis was achieved primarily by ligation and verified prior to closure. The skin was closed with a simple interrupted pattern using polyglactin 910. The number of skin sutures placed at closure was recorded for each dog to allow standardized follow-up assessment of suture status.

Scrotal Approach;

A single 2–3 cm incision was made along the ventral midline of the scrotum, centred between the two testes. The incision was placed between the testes with care to avoid unnecessary disruption of the intertesticular septum. After skin incision, the tunica dartos was bluntly dissected to access the closed vaginal tunic. Both testes were exteriorized sequentially through the same incision, and the procedure was performed as a closed technique with preservation of the parietal tunica vaginalis. Each spermatic cord was ligated using a double ligature technique with polyglactin 910, followed by transection and removal of the testes. Haemostasis was achieved primarily by ligation and verified prior to closure. The skin was closed with a simple interrupted pattern using polyglactin 910. The number of skin sutures placed at closure was recorded for each dog.

Postoperative Care

All dogs received amoxicillin–clavulanic acid (Synulox®, Zoetis, USA) at 8.75 mg/kg subcutaneously as a perioperative dose prior to surgery and once daily for the subsequent four days (total antibiotic course: 5 days), consistent with the routine perioperative protocol of the clinical setting. Postoperative analgesia consisted

of meloxicam (Maxicam®, Sanovel, Türkiye) at 0.2 mg/kg subcutaneously for three consecutive days. Surgical wounds were cleaned twice daily using hypochlorous acid solution (Crystalin®, NHP İlaç San. Tic. A.Ş., Türkiye) for seven days postoperatively. Owners were instructed to use an Elizabethan collar to minimize self-licking, and collars were provided as part of routine postoperative care.

Postoperative Assessment and Outcome Measures

Clinical evaluations were performed on postoperative days 3, 7, and 14. Wound outcomes were assessed using predefined ordinal scoring systems (Alvarenga et al., 2015; Marchegiani et al., 2024) for oedema (0–3) and exudation (1–4) applied consistently across all dogs and time points. Suture status was recorded as suture loss count, defined as the number of missing or loosened skin sutures observed at each time point relative to the number initially placed at closure (i.e., 0 indicates no suture loss). Because suture status may be influenced by local mechanical factors and self-trauma in addition to biological healing, suture loss count was treated as a secondary descriptive wound-related parameter.

Additional clinical variables recorded at each follow-up visit included presence of clinically suspected infection (yes/no), appetite (normal/reduced/absent), and defecation status (normal/diarrhoea/constipation). All assessments were performed by a single veterinarian.

Statistical Analysis

Statistical analyses were conducted using IBM SPSS Statistics (v27, IBM Corp., Armonk, NY, USA). Data are presented as mean ± standard deviation. Because oedema scores, exudation scores, and suture loss count were treated as ordinal/non-normally distributed variables,

Table 1. Postoperative wound outcomes and operative time in dogs undergoing prescrotal and scrotal castration (wound outcomes: median [IQR] and mean ± SD; operative time: mean ± SD).

| Day | Parameter | Prescrotal (median [IQR]; mean ± SD) | Scrotal (median [IQR]; mean ± SD) | P-value |
|----------------------|-------------------|--|---|---------|
| Day 3 | Oedema | 0 (0–0); 0.0 ± 0.0 | 2 (2–3); 2.2 ± 0.7 | <0.001 |
| | Exudation | 1 (1–1); 1.0 ± 0.0 | 3 (2–3); 2.8 ± 0.8 | <0.001 |
| | Suture loss count | 0 (0–0); 0.0 ± 0.0 | 1 (0–2); 0.9 ± 0.8 | <0.001 |
| Day 7 | Oedema | 0 (0–0); 0.0 ± 0.0 | 1 (0–1); 0.8 ± 0.8 | <0.001 |
| | Exudation | 1 (1–1); 1.0 ± 0.0 | 2 (2–3); 2.2 ± 0.7 | <0.001 |
| | Suture loss count | 0 (0–0); 0.0 ± 0.0 | 0 (0–1); 0.5 ± 0.5 | <0.001 |
| Day 14 | Oedema | 0 (0–0); 0.0 ± 0.0 | 0 (0–1); 0.3 ± 0.4 | 0.003 |
| | Exudation | 1 (1–1); 1.0 ± 0.0 | 1 (1–1); 1.2 ± 0.4 | 0.011 |
| | Suture loss count | 0 (0–0); 0.0 ± 0.0 | 0 (0–0); 0.0 ± 0.0 | 1.000 |
| Operative time (min) | | 33.03 ± 3.36 | 26.97 ± 4.25 | <0.001 |

Values are expressed as median (IQR: 25th–75th percentiles) and mean ± standard deviation. Oedema score, exudation score, and suture loss count were compared between the prescrotal and scrotal groups at each postoperative day (days 3, 7, and 14) using the Mann–Whitney U test. Operative time was compared using Welch’s t-test. For each wound outcome across the three time points, a Bonferroni-adjusted significance threshold was applied ($\alpha_{adj} = 0.0167$). P values below α_{adj} are considered statistically significant for wound outcomes.

between-group comparisons at each postoperative time point (days 3, 7, and 14) were performed using the Mann–Whitney U test. To control for multiplicity across the three time points for each wound outcome, a Bonferroni-adjusted significance threshold was applied ($\alpha_{\text{adj}}=0.05/3=0.0167$).

Operative time (minutes) was analysed as a continuous variable. Normality was assessed using the Shapiro–Wilk test, and homogeneity of variances was evaluated using Levene’s test. Because variances were unequal ($P=0.029$), operative time was compared between groups using Welch’s t-test. All tests were two-tailed, and P values <0.05 were considered statistically significant unless otherwise specified for multiplicity-adjusted analyses.

Results

According to the statistical analysis, postoperative wound outcomes differed significantly between the scrotal and prescrotal castration groups (Table 1). In the prescrotal group, oedema and exudation scores remained minimal across all follow-up visits (postoperative days 3, 7, and 14). In contrast, the scrotal group exhibited more pronounced early postoperative inflammatory findings.

On postoperative day 3, scrotal oedema (2.17 ± 0.70) (Figure 1) and exudation (2.80 ± 0.81) (Figure 2) were significantly higher in the scrotal group than in the prescrotal group (both $P < 0.001$).

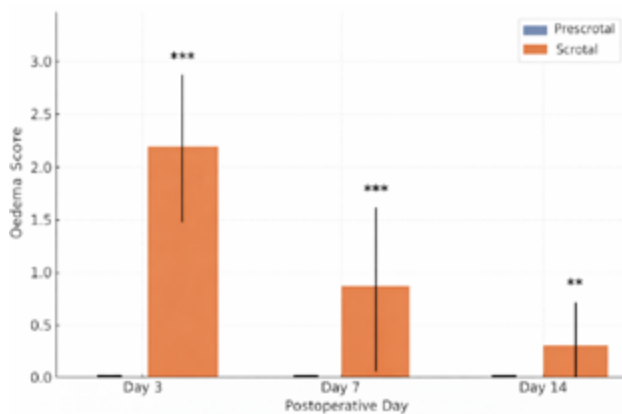


Figure 1. Oedema scores by postoperative day and castration technique. Mean oedema scores (\pm SD) are shown for dogs undergoing prescrotal and scrotal castration on postoperative days 3, 7, and 14. Between-group comparisons were performed separately at each time point using the Mann–Whitney U test. The scrotal group showed significantly higher oedema scores on days 3 and 7 (** $P < 0.001$) and on day 14 (** $P < 0.01$).

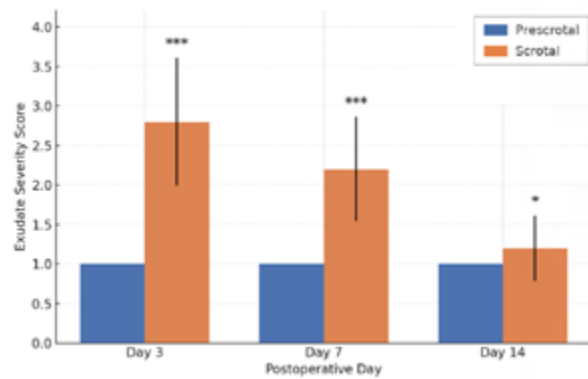


Figure 2. Postoperative exudation scores by day and castration technique. Mean exudation scores (\pm SD) are shown for dogs undergoing prescrotal and scrotal castration on postoperative days 3, 7, and 14. Exudation scores were significantly higher in the scrotal group at all time points (Mann–Whitney U test). For exudation and oedema scores, Bonferroni-adjusted significance was applied across time points ($\alpha_{\text{adj}} = 0.0167$). Significance level is indicated as $P < 0.05$ (*), $P < 0.01$ (**), and $P < 0.001$ (***).

In addition, suture loss count defined as the number of missing or loosened skin sutures relative to the number placed at closure (0 indicating no suture loss) was higher in the scrotal group (0.90 ± 0.84) than in the prescrotal group ($P < 0.001$) (Table 1; Figure 3).

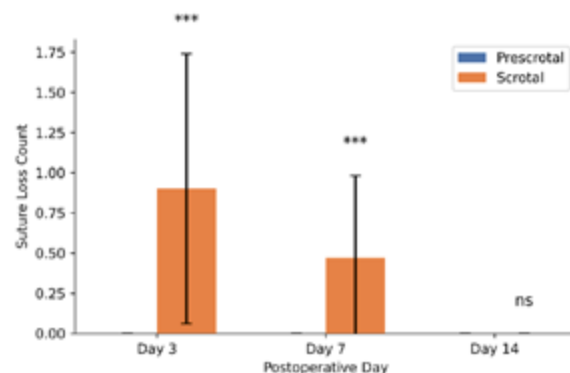


Figure 3. Suture loss count by postoperative day and castration technique. Mean suture loss count (\pm SD) on postoperative days 3, 7, and 14 in dogs undergoing prescrotal versus scrotal castration. Suture loss count was defined as the number of missing/loosened skin sutures relative to the number initially placed at closure (0 indicates no suture loss). Between-group comparisons were performed at each time point using the Mann–Whitney U test. The scrotal group showed higher suture loss counts on days 3 and 7 ($P < 0.001$), whereas no between-group difference was observed on day 14 (ns, $P = 1.000$). Significance level is indicated as $P < 0.05$ (*), $P < 0.01$ (**), and $P < 0.001$ (***); ns indicates not significant.

On postoperative day 7, oedema (0.83 ± 0.79) and exudation (2.20 ± 0.66) in the scrotal group remained significantly higher compared with the prescrotal group (both $P < 0.001$). Suture loss count also remained higher in the scrotal group on day 7 (0.47 ± 0.51 , $P < 0.001$) (Table 1; Figure 3).

By postoperative day 14, oedema (0.27 ± 0.45 , $P=0.003$) and exudation (1.20 ± 0.41 , $P=0.011$) remained high-

er in the scrotal group than in the prescrotal group, and both differences exceeded the Bonferroni-adjusted significance threshold applied across time points ($\alpha_{\text{adj}}=0.0167$) (Table 1). In contrast, there was no between-group difference in suture loss count at day 14 ($P=1.000$), indicating convergence of suture-related outcomes during the later stage of the short-term follow-up period (Table 1; Figure 3).

Operative time was significantly shorter in the scrotal group (26.97 ± 4.25 min) than in the prescrotal group (33.03 ± 3.36 min) (Welch's t-test, $P < 0.001$) (Table 1).

Discussion

In the present study, dogs undergoing scrotal castration exhibited higher oedema and exudation scores during the early postoperative period compared with dogs undergoing prescrotal castration. These differences were most evident on postoperative day 3 and persisted through day 14, although complete wound healing was observed in both groups by the end of the follow-up period. Collectively, these findings suggest that incision location may primarily influence the intensity and duration of the early inflammatory phase rather than the final short-term healing outcome.

Previous evidence syntheses and clinical series generally report comparable overall complication rates for scrotal and prescrotal approaches, particularly within the first 24 hours, while consistently noting shorter operative time with the scrotal technique (Brunn, 2022; Miller et al., 2018). Our results are in agreement with these reports regarding operative efficiency, and they further indicate that, under the conditions of this study, scrotal incisions were associated with more pronounced inflammatory findings during the short-term postoperative period.

Hamilton et al. (2014) compared open and closed orchidectomy techniques in healthy dogs and found that postoperative swelling and hematoma formation were more frequent when incisions were made in dependent regions such as the scrotum. Similarly, Adin (2011) described that orchidectomy complications such as haemorrhage, oedema, and local irritation are usually self-limiting but occur more often following scrotal approaches due to the area's higher vascularity and tissue mobility. In our investigation, the presence of oedema and exudation lasting until day 14 in the scrotal group supports this notion.

In a retrospective study, Pollari et al. (1996) analysed more than 3,000 elective surgeries and found that inflammation, seroma, and minor wound infections were among the most prevalent postoperative complications in routine castration procedures, highlighting the need for meticulous surgical techniques and careful postoperative observation. Additionally, Van Goethem (2016) pointed out that scrotal incisions enable natural drainage and reduce operative time, but they are also linked to increased early tissue reactivity compared to prescro-

tal methods. These observations align with the findings of MacPhail (2013) and Fossum (2002), who indicated that prescrotal castration can lead to less swelling and better cosmetic results when haemostasis and tension on the tissues are adequately managed.

Clinical reports focused on scrotal castration techniques emphasize that scrotal access can be a feasible and efficient approach when performed under standardized surgical principles. Woodruff (2013) described scrotal orchidectomy as a safe and practical alternative to prescrotal castration, particularly in shelter and high-throughput clinical environments, noting that scrotal incisions can facilitate testicular exteriorization and reduce operative complexity. Similarly, in a large prospective observational series, scrotal orchidectomy performed using a vessel-sealing device was reported as clinically applicable in a high number of cases, with outcomes indicating that scrotal access can be used effectively in routine practice (Yiapanis et al., 2024). These findings are consistent with the concept that scrotal approaches can offer procedural efficiency, while early postoperative tissue response may vary depending on local tissue characteristics and surgical handling.

Comparative wound-assessment studies further indicate that early postoperative changes are not determined solely by incision location, but rather reflect a combination of technical factors, including the open versus closed nature of the approach, ligature strategy, and the degree of tissue manipulation. Eze et al. (2017) evaluated wound outcomes following different canine castration techniques and demonstrated measurable differences in early postoperative wound appearance depending on the surgical method employed. This literature supports framing our results as differences in early wound inflammatory profile, rather than definitive superiority in overall healing, especially when final wound outcomes converge within the short-term follow-up window.

Interpretation of wound scores benefits from emphasizing standardized evaluation criteria. The development and validation of structured models and grading rubrics for canine castration training underscore the importance of clearly defined scoring domains and consistent assessment logic to improve interpretability and reproducibility (Hunt et al., 2020). Accordingly, the present study's ordinal wound outcomes are best interpreted as structured clinical observations reflecting short-term differences between approaches under a standardized follow-up protocol.

Finally, perioperative management can influence postoperative tissue perfusion and recovery dynamics, and prescrotal castration is frequently used as the surgical context in controlled clinical anesthesia studies. For example, a randomized clinical study evaluating intraoperative microcirculation changes in dogs anesthetized for prescrotal castration highlights that physiologic parameters and anesthetic choices can be directly relevant to tissue perfusion during this procedure (Honkavaara &

Ranki, 2025). Therefore, technique comparisons should be interpreted within the broader perioperative context, and conclusions should remain appropriately conservative when follow-up is limited to short-term healing.

Brunn (2022) concluded that scrotal incision does not result in poorer short-term recovery compared to pre-scrotal incision, and the procedure duration is typically shorter. However, the author noted that studies extending beyond 7 days are scarce. The present study addresses this gap by assessing wound healing progress up to day 14, showing that the pre-scrotal approach leads to quicker resolution of inflammation and more consistent epithelial healing over time. These results also align with the guidelines from Romagnoli et al. (2024), which suggest that the selection of surgical technique should be based on the patient's conformation, tissue characteristics, and postoperative care rather than solely on the location of the incision.

Moreover, extensive sterilization programs outlined by Kreisler et al. (2018) and the ASPCA (2025) have demonstrated that both pre-scrotal and scrotal techniques can be executed safely with low complication rates (less than 2%) when appropriate aseptic measures, pain management, and postoperative care are utilized. Similarly, Howe (2006) and Feldman and Nelson (2004) noted that while there are slight variations in the inflammatory response, both techniques are clinically effective when carried out by skilled surgeons.

In summary, the current findings indicate that although the scrotal approach facilitates a shorter surgical time and efficient drainage, the pre-scrotal technique significantly reduces postoperative oedema, exudation, and irritation, resulting in improved wound healing. By the 14th day after surgery, the healing results for both techniques were similar, implying that the location of the incision mainly affects the initial inflammatory phase instead of the ultimate wound healing outcome.

Limitations

This study has several limitations that should be acknowledged. First, postoperative assessments were performed by a single veterinarian and were not blinded to group allocation, which may introduce observer bias in ordinal scoring outcomes. Second, follow-up was limited to 14 days; therefore, the study does not address long-term cosmetic or dermatological outcomes, including remodelling-phase changes that may become evident at later time points. Third, oxidative stress parameters were not assessed and bacteriological cultures were not performed; thus, the study cannot characterize underlying biochemical pathways or confirm the microbiological status of wounds. Finally, perioperative management reflected routine clinical practice at the study setting (including a 5-day amoxicillin–clavulanic acid protocol, and anaesthetic management relied on injectable protocols without endotracheal intubation in this specific cohort, which differs from standards in referral settings.

Conclusion

In conclusion, scrotal castration was associated with a significantly shorter operative time, whereas pre-scrotal castration was associated with lower oedema and exudation scores during the early postoperative period. By postoperative day 14, complete wound healing was observed in both groups, indicating that the observed differences primarily reflect short-term inflammatory response rather than divergent short-term healing outcomes. Accordingly, technique selection should consider both operative efficiency and expected early postoperative tissue response, together with patient factors, surgeon preference, and the capacity for postoperative monitoring and wound care.

Acknowledgements

The authors would like to thank the staff of the Aydın Adnan Menderes University Veterinary Faculty Animal Hospital for their assistance during the clinical procedures.

Conflict of Interest

The authors declare that they have no conflict of interest related to this manuscript.

Author Contribution Statement

Z.C. contributed to the study conception and design; performed clinical data collection, postoperative follow-up and assessments; organized the dataset; and drafted the manuscript. E.Ç, Z.B.Ü. and R.Y. contributed to the development of the study design and methodology, conduct of the clinical procedures and data acquisition, interpretation of the findings, and critical revision of the manuscript. All authors read and approved the final manuscript.

References

- Adin, C.A. (2011). Complications of ovariohysterectomy and orchietomy in companion animals. *Veterinary Clinics of North America: Small Animal Practice*, 41(5), 1023–1039. <https://doi.org/10.1016/j.cvsm.2011.05.004>
- Alvarenga M.B., Francisco A.A., de Oliveira S.M., da Silva F.M., Shimoda G.T., Damiani L.P. (2015). Episiotomy healing assessment: Redness, Oedema, Ecchymosis, Discharge, Approximation (REEDA) scale reliability. *Revista Latino-Americana de Enfermagem*, 23(1):162-8. <https://doi.org/10.1590/0104-1169.3633.2538>.
- American Society for the Prevention of Cruelty to Animals (ASPCA). (2025). High-quality, high-volume spay/neuter surgical techniques. https://www.aspcapro.org/sites/default/files/hqhvsn_surgical_techniques.pdf
- Brunn, A. (2022). Surgical castration in dogs: Does the incision approach influence postoperative recovery? *Veterinary Evidence*, 7(4), 1–7. <https://doi.org/10.18849/ve.v7i4.587>
- Eze, C. A., Ugwu, N. E., Okpe, G. C., & Aguiyi, M. J. (2017). Evaluation of changes in wound assessment parameters associated with contralateral spermatic cord as ligature in open and closed pre-scrotal and scrotal castrations. *Comparative Clinical Pathology*, 26, 651–655. <https://doi.org/10.1007/s00580-017-2435-1>
- Feldman, E. C., Nelson, R. W., Reusch, C., & Scott-Moncrieff, J. C. (2014). *Canine and feline endocrinology-e-book*. Elsevier health sciences.
- Fossum, T.W. (Ed.). (2002). *Small animal surgery* (2nd ed.). Elsevier Mosby.
- Hamilton, K.H., Henderson, E.R., Toscano, M., & Chanoit, G.P. (2014). Comparison of postoperative complications in healthy dogs

- undergoing open and closed orchidectomy. *Journal of Small Animal Practice*, 55(10), 521–526. <https://doi.org/10.1111/jsap.12266>
- Honkavaara, J., & Ranki, J. S. (2025). Vatinoxan increases microcirculation in dogs anaesthetised with medetomidine-methadone-propofol-iso-flurane for prescrotal castration – A randomized, clinical study. *The Veterinary Journal*, 314, 106454. <https://doi.org/10.1016/j.tvjl.2025.106454>
- Howe, L.M. (2006). Surgical methods of contraception and sterilization. *Theriogenology*, 66(3), 500–509. <https://doi.org/10.1016/j.theriogenology.2006.04.014>
- Hunt, J. A., Heydenburg, M., Kelly, C. K., Anderson, S. L., & Dascanio, J. J. (2020). Development and validation of a canine castration model and rubric. *Journal of Veterinary Medical Education*, 47, 78–90. <https://doi.org/10.3138/jvme.1117-158r1>
- Kim, J.I., & Jeong, S.W. (2020). Evaluation of autoligation technique for castration in small breed dogs. *Journal of Veterinary Clinics*, 37(2), 75–81. <https://doi.org/10.17555/jvc.2020.04.37.2.75>
- Kreisler, R.E., Shaver, S.L., & Holmes, J.H. (2018). Outcomes of elective gonadectomy procedures performed on dogs and cats by veterinary students and shelter veterinarians in a shelter environment. *Journal of the American Veterinary Medical Association*, 253(10), 1294–1299. <https://doi.org/10.2460/javma.253.10.1294>
- MacPhail, C. (2013). Surgery of the reproductive and genital systems. In T. W. Fossum (Ed.), *Small Animal Surgery* (4th ed., pp. 794–795). Elsevier Mosby.
- Marchegiani, A., Troisi, A., Bazzano, M., Spaterna, A., & Fruganti, A. (2024). A Prospective, Blinded, Open-Label Clinical Trial to Assess the Ability of Fluorescent Light Energy to Enhance Wound Healing after Mastectomy in Female Dogs. *Animals*, 14(8), 1250. <https://doi.org/10.3390/ani14081250>
- Miller, K.P., Rekers, W.L., DeTar, L.G., Blanchette, J.M., & Milovancev, M. (2018). Evaluation of sutureless scrotal castration for pediatric and juvenile dogs. *Journal of the American Veterinary Medical Association*, 253(12), 1589–1593. <https://doi.org/10.2460/javma.253.12.1589>
- Pollari, F.L., Bonnett, B.N., Bamsey, S.C., Meek, A.H., & Allen, D.G. (1996). Postoperative complications of elective surgeries in dogs and cats determined by examining electronic and paper medical records. *Journal of the American Veterinary Medical Association*, 208(11), 1882–1886. <https://doi.org/10.2460/javma.1996.208.11.1882>
- Romagnoli, S., Krekeler, N., de Cramer, K., Kutzler, M., McCarthy, R., & Schaefer-Somi, S. (2024). WSAVA guidelines for the control of reproduction in dogs and cats. *Journal of Small Animal Practice*, 65(7), 424–559. <https://doi.org/10.1111/jsap.13724>
- Silva, E., Schumacher, J., & Passler, T. (2020). Castration of dogs using local anesthesia after sedating with xylazine and sub-anesthetic doses of ketamine. *Frontiers in Veterinary Science*, 6, 478. <https://doi.org/10.3389/fvets.2019.00478>
- Van Goethem, B. (2016). Orchiectomy. In D. Griffon & A. Hamaide (Eds.), *Complications in Small Animal Surgery* (2nd ed., pp. 528–532). Wiley.
- Yiapanis, C., Ober, C., Psyllaki, M., Attipa, C., Potamopoulou, M., Vasilakis, T., & Milram, J. (2024). Canine orchiectomy via scrotal approach using vessel-sealing device: prospective observational study of 200 cases. *Journal of the Hellenic Veterinary Medical Society*, 75(1), 6831–6838.
- Woodruff, K. A. (2013). *Scrotal castration as a safe and effective means of male canine sterilization* (Graduate thesis, Mississippi State University). Scholars Junction. <https://scholarsjunction.msstate.edu/td/3870>