

Coincidence of right adrenal vein and retroaortic left renal vein variations in a patient undergoing laparoscopic adrenalectomy

Laparoskopik adrenalektomi yapılan bir hastada sol retroaortik renal ven ve sağ sürrenal ven varyasyonunun rastlantısal birlikteliği

Haldun Kar, Necat Cin, Yasin Peker, Evren Durak, Özgün Akgül, Halis Bağ, Fatma Tatar

ABSTRACT

In this case, we report an interesting right adrenal vein variation with renovascular variations discovered during the laparoscopic right adrenalectomy. A Sixth eight-year-old woman was referred for treatment of a right adrenal mass. Computed tomography sections revealed 3x4.5x3.5 cm well defined right adrenal mass and retroaortic left renal vein. Conventional laparoscopic transabdominal approach was scheduled. During the laparoscopic exploration It was noted that there was no vein drainage from adrenal gland to the inferior vena cava. As this dissection completed, right adrenal vein was exposed arisen from accessory right hepatic vein. In some reports it has been reported that adrenal vein variations can be associated with retroaortic left renal vein, but the right adrenal vein joined with an accessory right hepatic vein and retroaortic left renal vein combination is extremely uncommon condition.

Key words: Adrenal vein variation, retroaortic left renal vein, accessory right hepatic vein, laparoscopic adrenal surgery

INTRODUCTION

The laparoscopic approach is accepted as a standard technique in adrenal surgery. The safe performance of laparoscopic adrenal resection requires a thorough knowledge of the anatomy of the adrenal gland, as well as its anatomic variations [1,2]. The anatomical variations in the drainage of the principal adrenal vein were seen with a frequency of about 5% on both right and left sides. On the right, the variations were isolated ectopic opening of the

ÖZET

Bu olguda, laparoskopik sağ adrenalektomi sırasında karşılaşılan dikkate değer sağ adrenal ven varyasyonu ile birlikte renovasküler varyasyonu sunmayı amaçladık. Altmış sekiz yaşında bayan hasta, sağ adrenal kitle tanısı ile tedavi amaçlı kliniğimize yatırıldı. Batın tomografisinde sağ adrenal bezde 3x4.5x3.5 cm boyutlarında solid kitle ve retroaortik sol renal ven tespit edildi. Hastaya laparoskopik transabdominal sağ adrenalektomi planlandı. Laparoskopik eksplorasyon sırasında adrenal bezden vena cava inferiora venöz drenaj izlenmedi. Disseksiyon tamamlandığında sağ adrenal venin aksesuar sağ hepatik vene açıldığı görüldü. Adrenal ven varyasyonları ile ilişkili sol retroaortik renal ven varyasyonu literatürde birkaç yayında rapor edilmekle birlikte, aksesuar sağ hepatik vene açılan sağ adrenal ven varyasyonu ile sol retroaortik renal ven varyasyon kombinasyonu çok daha nadir görülen bir durumdur.

Anahtar kelimeler: Adrenal ven varyasyonu, retroaortik sol renal ven, aksesuar sağ hepatik ven, laparoskopik adrenal cerrahi

principal adrenal vein. On the left, they were more complex, accompanied by an anomaly of the left renal vein [3]. A left renal vein passing behind the abdominal aorta is termed a retroaortic left renal vein (RLRV) and its variation is a relatively uncommon condition [4]. The incidence of isolated RLRV ranged from 0.5 to 3.5% in cadaver dissection, and from 0.4 to 9.3 % in clinical reports [5].

During a laparoscopic right adrenalectomy we encountered a right adrenal vein that joined with

an accessory right hepatic vein. In some reports it has been reported that adrenal vein variations can be associated with RLRV, but the right adrenal vein joined with an accessory right hepatic vein and RLRV combination is extremely uncommon condition [3]. In this case, we report an interesting right adrenal vein variation with renovascular variations discovered during the laparoscopic right adrenalectomy.

CASE

A Sixth eight-year-old woman was referred for treatment of a right adrenal mass. Computed tomography (CT) sections revealed 3x4.5x3.5 cm well defined right adrenal mass and RLRV (Figure 1). This mass was hormone inactive during preoperative evaluation. Conventional laparoscopic transabdominal approach was scheduled.

During the laparoscopic exploration the mass was freed from medial attachments and partially mobilized. It was noted that there was no vein drainage from adrenal gland to the inferior vena cava (IVC). Once the mass was gently retracted laterally, an aberrant 0,5 cm wide vein was observed on the superior border of adrenal tissue. This vein was dissected meticulously from the adjacent tissues by using hook cautery. As this dissection completed, right adrenal vein was exposed arisen from accessory right hepatic vein (Figure 2). Adrenal vein was gently ligation with titanium clips and was then divided. Adrenalectomy was completed in a usual fashion. Total blood loss was less than 30 cc. Myelolipoma was rendered in histopathologic investigation.

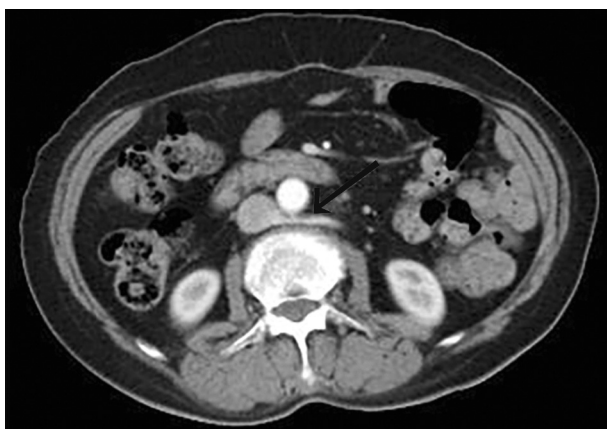

Figure 1. CT images revealed RLRV (red arrow) passing posteriorly to the abdominal aorta

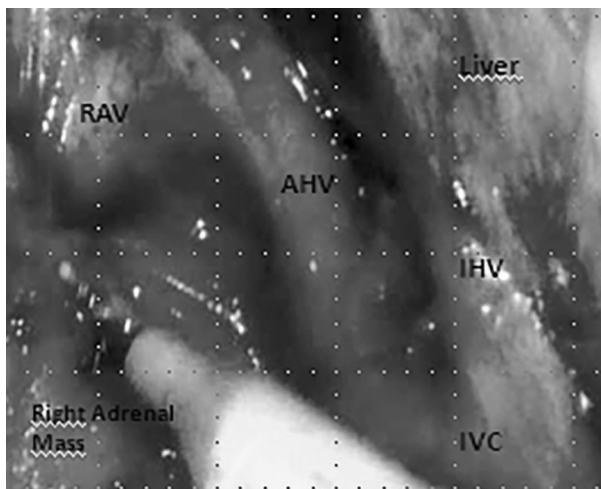


Figure 2. Laparoscopic dissection along the inferior vena cava (IVC) demonstrating large accessory hepatic vein (AHV), inferior hepatic vein (IHV) and right adrenal vein (RAV)

DISCUSSION

The anatomic variations of right adrenal vein have been documented in cadaver studies, a few clinical studies and case reports. Scholten et al reported 70 (13%) adrenal vein variations in 546 laparoscopic adrenalectomies. They have found 3(0.55%) patients with variant anatomy of the right adrenal vein joining with an accessory right hepatic vein [6]. This was also found in 8 (9.63%) patient in the study by Nakamura and Tsuzuki [7]. Matsuura et al reported a common trunk of the right adrenal vein arisen from an accessory hepatic vein in 6 (7.59%) of the 79 patients in their MDCT series [8]. Sebe et al reported 1 (1.13%) cases of right adrenal vein joining with an accessory hepatic vein for diagnosis of hyperaldosteronism in their 88 venograms [3].

Previous studies on variations of adrenal venous drainage showed that the right side is more susceptible than from the the left side. On the left, the variations may be anticipated since they are linked to an variation of the adrenal vein identifiable on preoperative imaging such as CT scanning. On the right, preoperative diagnosis is more difficult since the variation is mostly isolated on radiologic pictures [3]. Also as another venous variation was associated in our patient, and this variation(RLRV) is usually asymptomatic. Most of them incidentally detected by imaging as in our case [4,9]. The coincidence of both anomalies has been reported in few publications [3].

The adrenal veins originate during the formation of the prerenal inferior vena cava and are remnants of caudal portion of the subcardinal veins, cranial to the subcardinal sinus in the embryo. A section of the right subcardinal veins, cranial to the subcardinal sinus and caudal to the hepato-subcardinal junction, integrates with right the adrenal gland and later becomes the right adrenal vein. The many communications between the posterior cardinal, supracardinal, and subcardinal veins of the primordial venous system provide an explanation for the variable anatomy. Most commonly one central vein drains each adrenal gland. In some instances the long left adrenal vein joins the inferior phrenic vein and drains into the left renal vein, while the short right adrenal vein drains immediately in to the IVC. The right adrenal vein courses transversely to directly enter the IVC posterolaterally, 3-5 cm superior to the right renal vein [10]. Development of the renal vein occurs between the fourth and eight gestational weeks by the sequential formation, anastomoses, and regression of the three paired veins (posterior cardinal, subcardinal and supracardinal veins). Usually the ventral portion of the circum-aortic plexus persists as the normal left renal vein. If the dorsal portion of the plexus persists, then the left renal vein is posterior to the aorta (RLRV) [4,11].

Right adrenalectomy has a potentially greater risk for intraoperative hemorrhage than on the left side. The most crucial step during the operation is to identify the adrenal vein at the point where it meets the IVC. The extreme proximity between the right adrenal vein and the IVC and the variants of the right adrenal vein present major risks of iatrogenic injury during surgical procedures [10]. Intraoperative dissection should be taken to the hepatic vein if the principle adrenal vein is not identified on the right lateral aspect of the retrohepatic IVC [3].

Laparoscopic right adrenalectomy also requires more extensive mobilization and medial retraction of the right lobe of the liver [1]. The meticulous attention should be focused to the fibrotic attachments between right adrenal vein and hepatic vein during the dissection since an even pinpoint hole may cause catastrophic scenarios.

Diagnosis of the renal vein variations is important information in retroperitoneal surgery. Detection of the renal vein variations can decrease the

rate of surgical complications such as bleeding, nephrectomy and even death [4,11].

In Conclusion, the anatomic variations of right adrenal vein are rare. These variations could make vascular dissection quite difficult. In this case vascular dissection of right adrenal gland should be performed cautiously to avoid intraoperative unpredicted hemorrhage. Vascular anatomic variations may be coexisted with other renovascular variations. As it was determined in our patient before the operation, left renal vein variations may have predictive value to detect adrenal vein variations both preoperatively and during the procedure. Once the adrenal vein variation is detected incidentally the attention should be spend for preservation of the anatomic integrity of the vessels surrounding right adrenal gland.

REFERENCE

1. MacGillivray DC, Khwaja K, Shickman SJ. Confluence of the right adrenal vein with the accessory right hepatic veins. A potential hazard in laparoscopic right adrenalectomy. *Surg Endosc* 1996;10:1095-1096.
2. Penbegül N, Kılınc F, Yıldırım K, et al. Laparoscopic adrenalectomy: Our clinical experiences with the first 10 patients. *Dicle Medical Journal* 2012;39:567-570
3. Sèbe P, Peyromaure M, Raynaud A, Delmas V. Anatomical variations in the drainage of the principal adrenal veins: the results of 88 venograms. *Surg Radiol Anat* 2002;24:222-225.
4. Nam JK, Park SW, Lee SD, Chung MK. The clinical significance of a retroaortic left renal vein. *Korean J Urol* 2010;51:276-280.
5. Yi SQ, Ueno Y, Naito M, et al. The three most common variations of the left renal vein: a review and meta-analysis. *Surg Radiol Anat* 2012;34:799-804.
6. Scholten A, Cisco RM, Vriens MR, et al. Variant Adrenal Venous Anatomy in 546 Laparoscopic Adrenalectomies. *JAMA Surg* 2013;148:378-383.
7. Nakamura S, Tsuzuki T. Surgical anatomy of the hepatic veins and the inferior vena cava. *Surg Gynecol Obstet* 1981;152:43-50.
8. Matsuura T, Takase K, Ota H, et al. Radiologic anatomy of the right adrenal vein: preliminary experience with MDCT. *AJR Am J Roentgenol* 2008;191:402-408.
9. Dilli A, Ayaz UY, Kaplanoglu H, et al. Evaluation of the left renal vein variations and inferior vena cava variations by means of helical computed tomography. *Clinical Imaging* 2013;37:530-535.
10. Cesmebası A, Plessis MD, Iannatuono M, et al. A review of the anatomy and clinical significance of adrenal veins. *Clin Anatomy* 2014;27:1253-1263
11. Satyapal KS, Kalideen JM, Haffjee AA, et al. Left renal vein variations. *Surg Radiol Anat* 1999;21:77-81.