

## An unusual pacemaker malposition and delayed diagnosis

### *Sıradışı pacemaker malpozisyonu ve gecikmiş tanı*

Bircan Alan<sup>1</sup>, Abdurrahim Dusak<sup>1</sup>, Mehmet G. Çetinçakmak<sup>1</sup>, Sait Alan<sup>2</sup>

#### ABSTRACT

Transvenous right ventricular pacing usually shows a left bundle branch block (LBBB) pattern. When right bundle branch block (RBBB) pattern appears after the insertion of an electrode, perforation or malposition of the pacing lead usually occurs. However, when the pacing lead that is inserted into the coronary sinus or right ventricle extends to right ventricle septum, RBBB pattern may appear. Echocardiography, due to inadequate echo images or reflections, may result in early clinical misdiagnosis since it cannot be evaluated well. Another reason for the errors in diagnosis is that cardiologists generally relegate telegraphy evaluations to a second plan. Here, we present a case of pacemaker malposition, which was diagnosed using X-ray radiography after multiple failed evaluations with echocardiography.

**Key words:** Pacemaker malposition, cerebrovascular event, delayed diagnosis

#### INTRODUCTION

Inadequate Echocardiography images or reflections, may result in early clinical misdiagnosis since it cannot be evaluated well. Another reason for the errors in diagnosis Pacemaker Malposition is that cardiologists generally relegate telegraphy evaluations to a second plan. In our country in the controls of cardiac pacemaker, the first preference of cardiologists is generally echocardiography. However, due to restrictions such as inadequate echo images or reflections, this procedure often yields improper echocardiographic outcomes.

#### ÖZET

Sağventrikül Pace maker yerleştirilmesi ile EKG de sol dal bloğu (LBBB) tablosu gözükür, Pace lead'inin yanlış yerleşimi veya perforasyonunda EKG de sağ dal bloğu tablosu görülür. Buna rağmen bazen Pace maker lead'inin koroner sinüse yerleşmesi veya sağventrikül septumuna yönelmeside EKG de RBB tablosuna neden olabilir. Ekokardiografik incelemelerde, yetersiz eko görüntüleri veya eko yansımaları nedeniyle hatalı değerlendirmelere neden olarak yanlış tanıları konulabilmektedir. Yanlış tanı konulmasında bir diğer önemli neden kardiyologların TELE değerlendirmelerini genellikle ikinci plana itmeleri, ihmal etmeleridir. Bu vakamızda birçok değerlendirme ve Ekokardiografi ile atlanmış, TELE grafi ile tanı konulmuş yanlış yerleşimli Pace maker olgusunu sunduk.

**Anahtar kelimeler:** Yanlış yerleşimli kalp pili, serebrovasküler olay, gecikmiş tanı

#### CASE REPORT

We report a case of a 71 year-old woman who underwent permanent transvenous VDD pacemaker implantation thirteen years ago and had a pacemaker battery change at another institution (four years ago). She was admitted for transient ischemic attacks (TIA). Until this time, only a few attacks were determined to have occurred. Physical examination was normal. An electrocardiogram (ECG) showed a typical right bundle branch block (RBBB) configuration (Figure 1).

<sup>1</sup> Dicle University, School of Medicine, Radiology Department, Diyarbakir, Turkey

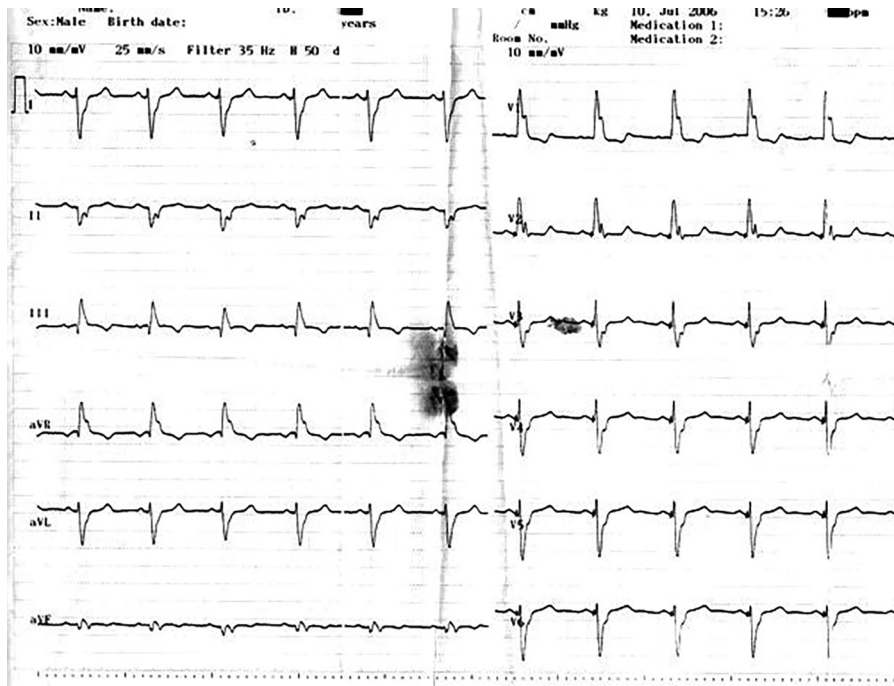
<sup>2</sup> Dicle University, School of Medicine, Cardiology Department, Diyarbakir, Turkey

**Yazışma Adresi /Correspondence:** Bircan Alan,

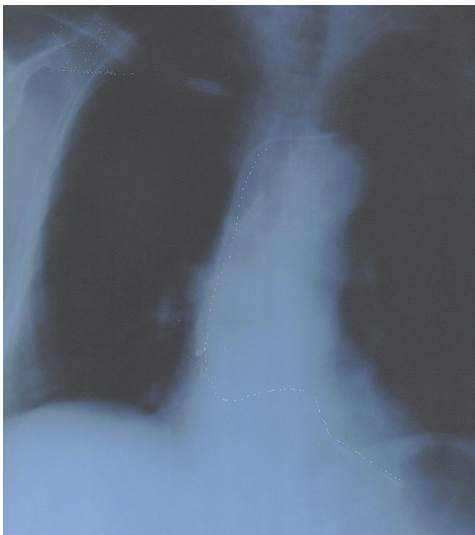Dicle University Faculty of Medicine, Department of Radiology, Diyarbakir, Turkey Email: bircanalan@hotmail.com

Geliş Tarihi / Received: 04.11.2014, Kabul Tarihi / Accepted: 07.01.2015

Copyright © Dicle Tıp Dergisi 2015, Her hakkı saklıdır / All rights reserved



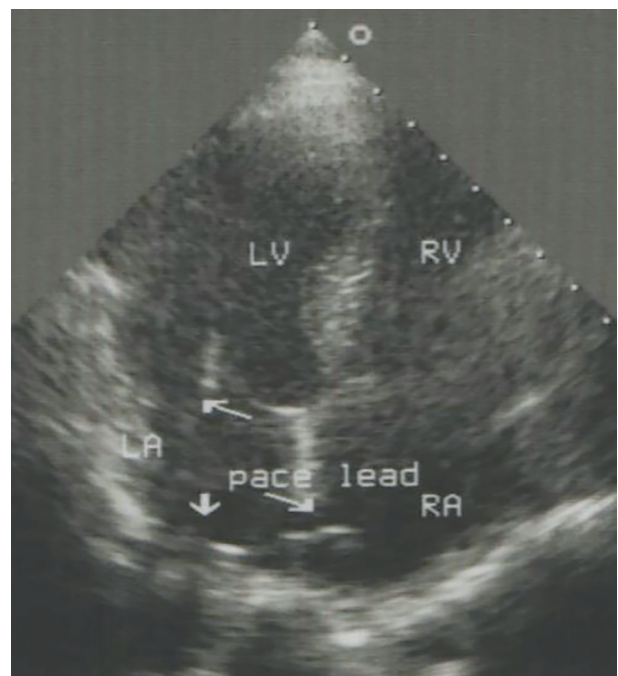
**Figure 1.** Electrocardiogram showed a typical right bundle branch block pattern



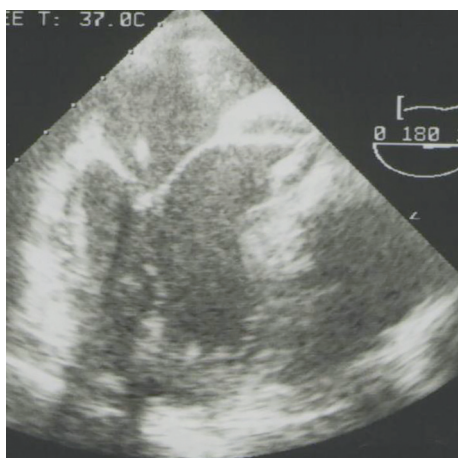
**Figure 2.** Anteroposterior chest X-ray shows a malpositioned left ventricular lead.

Even with repeated echocardiography examinations, the pathology was not noticed due to inadequate echo images. In addition, the patient could not tolerate transoesophageal echo imaging procedure to be performed under polyclinic conditions. Cranial CT was detected to be normal, and the pacing lead was found to be placed in the left ventricle in an X-Ray radiography performed for another reason (Figure 2). Transoesophageal echocardiog-

raphy performed under anesthesia showed that the lead perforates the interatrial septum going from the right atrium to the left atrium and through the mitral valve into the left ventricle (Figure 3A, 3B).



**Figure 3A.** Echocardiography shows the pacing lead going from the RA to the LA and the LV (RA, right atrium; LA, left atrium; LV, left ventricle)



**Figure 3B.** Transesophageal echocardiography shows the pacing lead going from the LA to the LV (thick arrow). (RA, right atrium; LA, left atrium; LV, left ventricle)

## DISCUSSION

Transvenous right ventricular pacing usually shows a LBBB pattern. When the QRS complex changes from LBBB to RBBB in cases, a complication occurs such as perforation of the free RV wall or of the interventricular septum by the pacing lead [1,2]. Placement of the pacing lead in the coronary sinus may also yield a RBBB pattern, and RBBB may be seen in ECG when pacemaker lead extends to the right ventricle [3]. Rarely, malposition may occur when the lead perforates the interatrial septum or is passed through an atrial septal defect inadvertently and extends across the left atrium and through the mitral valve into the left ventricle [4].

As a result of inadequate echo images or reflections in patients, satisfactory evaluations cannot be made. In this respect, Transoesophageal Echocardiography (TEE) should be recommended. TEE was also recommended to our case, but she could not tolerate it. Due to inadequate Transthoracic Echocardiography images of the patient, his transthoracic echo images were determined to be normal, yet X-Ray, which is fairly easy and cheap, was not performed. In our country, a cardiologists' first preference is generally echocardiography as a cardiac pacemaker control. Due to restrictions such as inadequate echo imaging or reflections, sometimes satisfactory echocardiographic outcomes are likely not to be obtained. As the reason of RBBB pattern in ECG, a pacemaker lead is supposed to be extended

to the right ventricle septum or inserted into coronary sinus.

The left ventricular location of the lead has been shown to be a predisposition to thrombus formation and development of any neurologic symptoms in a patient with a pacemaker [5]. Given the repeated TIAs, cranial CT was taken and found to be normal. A Cranial CT may appear normal for small emboli when taken at early period [6]. Thus, they often fall short for the correct diagnosis. In a standard X-Ray radiography taken in the outpatient clinic examination for another purpose, the placed pacing lead was observed in the LV position. TEE was performed under anesthesia and showed that the lead perforates the interatrial septum going from the right atrium to the left atrium and through the mitral valve into the left ventricle (figure 3A, 3B).

In conclusion, patients with RBBB pattern after transvenous RV pacing require careful evaluation to distinguish leads that are correctly placed and those that are improperly placed. Therefore, when the 12-lead ECG is noticed, one should be insistent to clarify the ECG changes. On the other hand, chest X-rays should not be overlooked or too simplistic for diagnosis. Echocardiography can facilitate the recognition of the lead position but in difficult cases, Transoesophageal Echocardiography might be needed.

## REFERENCES

1. Engstrom A, Holmberg B, Mansson A, et al. Inadvertent malposition of a transvenous pacing lead in the left ventricle. *Herzschrittmacherther Elektrophysiol* 2006;17:221-224.
2. Vanhercke D, Heytens W, Verloove H. Eight years of left ventricle pacing due to inadvertent malposition of a transvenous pacemaker lead in the left ventricle. *Eur J Echocardiogr* 2008;9:825-7. doi: 10.1093/ejehocard/jen187.
3. Meyer JA, Millar K. Malplacement of pacemaker catheters into the coronary sinus. *J Thorac Cardiovasc Surg* 57:511;1969.
4. Ghani M, Thakur RK, Boughner D, et al. Malposition of transvenous pacing lead in the left ventricle. *PACE* 16:1800;1993.
5. Kumral E, Omac T, Orhan K, et al. An unusual cause of stroke in a patient with permanent transvenous pacemaker. *Jpn Heart J* 2004;45:873-875.
6. Islam MN1, Kuddus R, Chowdhury NS, et al. Radiologic evaluation of hyperacute brain infarction: A review. *Myensingh Med J* 2014;23:621-635.