




# Aydın Dental Journal

Journal homepage: <http://dergipark.ulakbim.gov.tr/adj>



## ***A MULTIDISCIPLINARY ORTHODONTIC CASE: ORTHODONTICS, PERIODONTICS, IMPLANT AND PROSTHODONTICS***

**DergiPark**  
AKADEMİK

*Fatma YILDIRIM<sup>1</sup>, Orhan AKSOY<sup>1</sup>, Utku Gaye DİKME GÜVELİ<sup>2</sup>, Erol AKIN<sup>3</sup>*

### ABSTRACT

Diastemas are frequent orthodontic problems caused by multiple etiologies which can be physiologic and dentoalveolar like missing tooth, peg lateral, supernumerary teeth, prominent frenulum, proclination of the labial dental segment; or self-inflicted pathologies. The continuing presence of an anterior diastema in adults, has often been considered as an aesthetic problem. In this case, a multidisciplinary treatment of an adult patient who had a missing tooth and a prominent upper labial frenulum, which includes orthodontics, periodontics, implants and prosthetics will be presented.

**Keywords:** *Diastema, Labial Frenulum, Multidisciplinary Treatment*

### ÖZET

Diastemalar; diş kaybı, kama lateral, süpernumerer diş, belirgin frenulum ve labial dental segmentin proklinasyonu gibi fizyolojik nedenlerle veya patolojik sebeplere bağlı olarak sık görülen ortodontik problemlerdir. Yetişkinlerde anterior diastemanın varlığı, sıklıkla estetik bir sorun olarak kabul edilir. Bu vakada, yetişkin bir hastada, diş kaybına ve belirgin labial frenulumuna bağlı ortaya çıkan diastemanın; ortodontik, periodontal, implant ve protetik işlemlerini içeren multidisipliner bir tedavisi sunulacaktır.

**Anahtar Kelimeler:** *Diastema, labial frenulum, multidisipliner tedavi*

<sup>1</sup> *Istanbul Aydın University, Faculty of Dentistry, Department of Orthodontics*

<sup>2</sup> *Istanbul Aydın University, Faculty of Dentistry, Department of Periodontics*

<sup>3</sup> *Private Practice, Orthodontist*

## INTRODUCTION

A space between adjacent teeth is called a diastema. Diastemas are frequent orthodontic problems caused by multiple etiologies which can be physiologic and dentoalveolar like missing tooth, peg lateral, supernumerary teeth, prominent frenulum, proclination of the labial dental segment; or self-inflicted pathologies.<sup>1</sup> Midline diastema refers to anterior midline spacing between the two central incisors. Midline diastema occurs in approximately 98% of 6 year olds, 49% of 11 year olds and 7% of 12–18 year olds.<sup>2</sup> It is a part of normal dental development during mixed dentition which is called ugly duckling stage by Broadbent.<sup>4</sup> It is a self-correcting anomaly after the eruption of the permanent canines. The continuing presence of a midline diastema is not physiologic and considered as an aesthetic problem in adults. Numerous etiologies have been proposed for maxillary midline diastema including tooth size or jaw size discrepancies, parafunctional habits, tooth loss, periodontal disease, deep bites, aberrant labial frenulum attachments and maxillary midline pathologies.<sup>3, 5-12</sup>

The frenulum is a mucous membrane fold that attaches the lip and the cheek to the alveolar mucosa, the gingiva, and the underlying periosteum<sup>3</sup>. The aberrant labial frenulum is a problem which creates midline diastema and it can be treated by frenectomy or by frenotomy procedures. These procedures are technically different from each other. Frenectomy is the complete removal of the frenulum, including its attachment to the underlying bone, while frenotomy is the incision and the relocation of the frenal attachment<sup>3</sup>.

A healthy and attractive smile is very important in today's society. Many patients

seek closure of a diastema for aesthetic reasons. Many treatment options have been used, varying from restorative procedures to surgery (frenectomy) and orthodontics. A carefully developed differential diagnosis allows the practitioner to choose the most effective treatment objectives. In this case, a multidisciplinary treatment of an adult patient who had a missing tooth and a prominent upper labial frenulum, which includes orthodontics, periodontics, implants and prosthetics will be presented.

## CASE REPORT

A 26 year old female reported to the orthodontic clinic with the chief complaint of upper jaw midline diastema. She has Angle Class I malocclusion and diastemas due to missing upper left second premolar teeth and prominent upper labial frenulum attachment. In lateral cephalometric examination, we determined skeletal Class I relationship and normal vertical pattern. The patient's past medical and dental history were not contributory; but in family history, she noted that her sister also had upper prominent labial frenulum and this information led us to think that genetic factors can be contributing factor in diastema etiology. (Fig. 1)

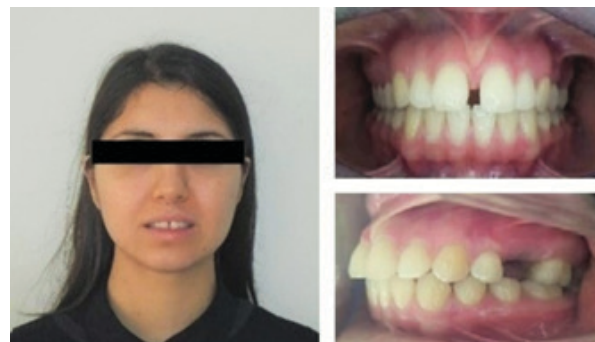

Figure 1. The initial photographic records

Multidisciplinary treatment which includes orthodontics, periodontics, implants, and prosthetics was planned for the case. Orthodontic treatment was started at first and the midline diastema was closed with fixed bonded braces and mechanics. The space caused by tooth extraction was maintained for dental implant procedures. Before the finishing phase, when the upper midline diastema closed, patient was directed to the periodontology department. Because of the width and thickness of the frenulum attachment frenectomy was chosen instead of frenotomy. Frenectomy was carried out by periodontist under local anesthesia with incision using No. 15 Bard Parker blade. Sutures were placed and periodontal pack was placed for a week. Healing was successful and pleasant. (Fig. 2, 3)

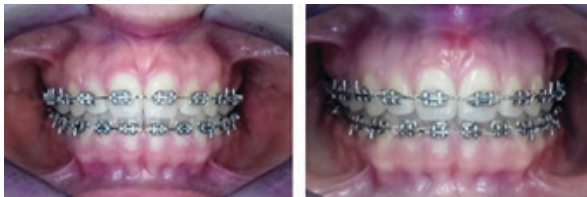


Figure 2. The photographic records before upper labial frenectomy and after healing.

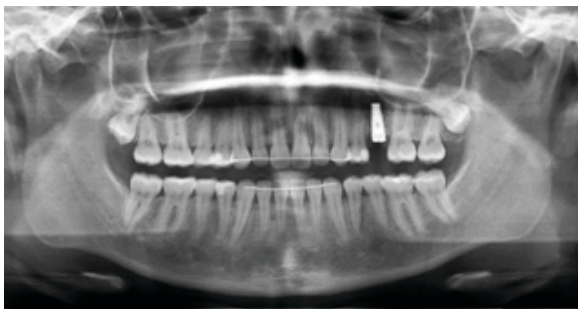


Figure 3. The panoramic radiographs after orthodontic debonding and implant surgery.

After these procedures, braces were removed and fixed lingual retainers were bonded

canine to canine on lower arch and between first premolars on upper arch. Implant surgery was performed and a week later sutures were removed. A removable Hawley appliance used for retention until the osseointegration process was complete. After osseointegration, the patient was rehabilitated with crown prosthesis. At the end of the treatment, the upper third molars were extracted. (Fig. 4)

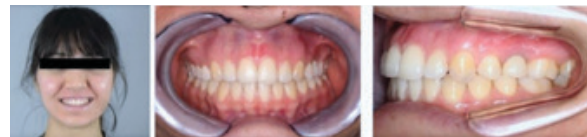

Figure 4. The photographic records after 1 year retention period.

## DISCUSSION

In the recent times, due to increasing expectations of the patients for an esthetically and functionally stable treatment result, an interdisciplinary treatment will yield the best result for the patient and the clinicians. Evaluating the patient history prior to treatment is vital for the treatment planning. In this case, we determine the upper labial frenulum as an etiological cause of upper midline diastema. Patient also stated that her sister has a similar midline diastema hence it suggests that genetic factors may be contributing factor in this etiology. Gaas et al.<sup>13</sup> reported that, heritability of maxillary midline diastemas was estimated to be %32 in white population and % 0,4 in black population. According to their study, the pedigree data suggest an autosomal dominant mode of inheritance for maxillary midline diastema and a possible genetic influence in the expression of maxillary midline diastema in both the black and the white sample populations. In this case, the diastema was closed orthodontically and then frenectomy

performed. We should not do frenectomy prior to orthodontic treatment because the scar tissue can inhibit the tooth movement. In these types of cases, the fixed retainers are recommended to curb the high possibility of relapse.<sup>14</sup>

In the treatment of midline diastema and other diastemas due to missing tooth, a multidisciplinary approach is necessary to achieve a successful outcome. All specialists should set realistic treatment objectives in order to meet the needs of the patient.

## CONCLUSION

Today, many adults demand orthodontic treatment to improve their appearance and dental health. Multidisciplinary treatment approaches should be offered to these patients. Orthodontic procedures are routinely used to close diastemas; however more stable and aesthetic results can be achieved with interdisciplinary treatments which includes orthodontics, periodontics, implants, and prosthetics.

## REFERENCES

- [1] Hussain, U., Ayub, A., & Farhan, M. (2013). Etiology and treatment of midline diastema: A review of literature. *Pakistan Orthodontic Journal*, 5(1), 27-33.
- [2] Foster TD, Grundy MC. Occlusal changes from primary to permanent dentitions. *J Ortho*. 1986; 13: 187-93.
- [3] Devishree, Gujjari SK, Shubhashini PV. Frenectomy: A Review with the Reports of Surgical Techniques. *Journal of Clinical and Diagnostic Research* : JCDR. 2012; 6(9):1587-1592.
- [4] Broadbent BH: The face of the normal child (diagnosis, development). *Angle Orthod* 1937; 7:183-208.
- [5] Angle EH. Treatment of malocclusion of the teeth. 7th ed. Philadelphia: S.S. White Dental Manufacturing Co; 1907.
- [6] Sicher H. Oral anatomy. 2nd ed. St. Louis: C. V. Mosby; 1952.
- [7] Gardiner JH. Midline spaces. *Dent Pract Dent Rec* 1967; 17:287-97.
- [8] Edwards JG. The diastema, the frenum, the frenectomy: a clinical study. *Am J Orthod* 1977; 71:489-508.
- [9] Sullivan TC, Turpin DL, Artun J. A postretention study of patients presenting with a maxillary median diastema. *Angle Orthod* 1996; 66:131-8.
- [10] Tait CH. The median frenum of the upper lip and its influence on the spacing of the upper central incisor teeth. *Dent Cosmos* 1934; 76:991-2.
- [11] James GA. Clinical implications of a follow-up study after frenectomy. *Dent Pract Dent Rec* 1967; 17:299-305.
- [12] Oesterle LJ, Shellhart WC. Maxillary midline diastemas: a look at the causes. *J Am Dent Assoc* 1999; 130:85-94.
- [13] Gass, J. R., Valiathan, M., Tiwari, H. K., Hans, M. G., & Elston, R. C. (2003). Familial correlations and heritability of maxillary midline diastema. *American journal of orthodontics and dentofacial orthopedics*, 123(1), 35-39.
- [14] De Morais, J. F., de Freitas, M. R., de Freitas, K. M. S., Janson, G., & Castello Branco, N. (2014). Postretention stability after orthodontic closure of maxillary interincisor diastemas. *Journal of Applied Oral Science*, 22(5), 409-415.