



## EAGLE SYNDROME: REPORT OF A CASE AND A REVIEW OF LITERATURE

### EAGLE SENDROMU: OLGU SUNUMU VE LİTERATÜR DERLEMESİ

Dt. Ayşenur YILDIZ\*

Dt. Berceste POLAT AKMANSOY\*

Prof. Dr. Filiz NAMDAR PEKİNER \*

**Makale Kodu/Article code:** 2912  
**Makale Gönderilme tarihi:** 30.06.2016  
**Kabul Tarihi:** 02.12.2016

#### ABSTRACT

Eagle's syndrome is defined as the symptomatic elongation of the styloid process or mineralization of the styloid ligament complex. It can be presented as a variety of different symptoms which can mislead the otolaryngologist and the dentist in diagnosing this condition. The objective of this report is to present a case report of Eagle Syndrome in a female patient and review of literature.

**Keywords:** Eagle's syndrome, styloid process, cone beam computerized tomography

#### ÖZ

Eagle sendromu stiloid sürecin semptomatik olarak uzaması veya stilohyoid ya da stilomandibular ligamanın mineralizasyonu ile karakterize bir sendrom olarak ifade edilmektedir. Bu sendrom kulak burun boğaz uzmanı ve diş hekimlerini tanı bakımından yanıltabilecek farklı belirtilerle ortaya çıkabilir. Bu makalede Eagle sendromlu bir kadın olgu literatür bilgileri doğrultusunda sunulmuştur.

**Anahtar Kelimeler:** Eagle sendromu, stiloid sürec, konik ışınli bilgisayarlı tomografi

#### INTRODUCTION

Enlarged styloid process or calcified styloid ligament causing mass effect on the adjacent structures, the nerves and vessels resulting in cervical and craniofacial pain along with other symptoms is stated as Eagle syndrome.<sup>1</sup> This syndrome was described in 1937 by the Watt Weems Eagle, an otolaryngologist.<sup>2,3</sup> The etiology of Eagle syndrome has not been known clearly, and Eagle considered any styloid process longer than 25 mm to be abnormal.<sup>4</sup>

Although panoramic radiography and conventional radiographs can provide idea about the abnormality, but the studies are very limited due to superimposed structures and incomplete details, 3D-computed tomography allows for the precise measurement of the styloid process length, direction, and anatomic variance, and to evaluation of the styloid ligament ossification.<sup>5,6</sup>

The purpose of this report is to present a case report of Eagle Syndrome in a female patient and review of literature.

#### CASE REPORT

A 52 years old female patient was admitted to the Department of Oral Diagnosis and Radiology, Marmara University faculty of dentistry, Istanbul, Turkey with pain. Her past medical history was angio for cardiac problem in 2014. The family history was unremarkable.

The patient was informed and consent was obtained from the patient.

She has been experiencing limitation of motion in the neck, and lower jaw and neck pain on both side of the body for over five years. A recurrence of pain was present 2 to 3 times a month and had worsened for the past a year. It aggravated on chewing and turning the head on both side. The patient had used non-steroidal anti-inflammatory medicaments for the pain multiple times without a definitive diagnosis or treatment.

On extraoral examination, no abnormalities were detected with the temporomandibular joint and the regionally lymph nodes were not palpable. Mouth opening was adequate, but patient reported irritation

\* Department of Oral Diagnosis and Radiology, Marmara University, Faculty of Dentistry, İstanbul.



in her throat on opening the mouth wide. On intraoral examination revealed no abnormal findings. The patient gave no history of any past trauma and surgical treatment of head and neck region.

An OPTG was taken by Morita panoramic radiography machine (Morita, veraviewepocs 2D, USA). OPTG machine was operated at 72 kV, 9 mA and 8 sec. The OPTG revealed the presence of bilateral elongated styloid process (Fig.1). Therefore, cone-beam computed tomography (CBCT) was taken for differential diagnosis of Eagle Syndrome. The CBCT image was acquired using a Planmeca CBCT machine (Planmeca, Promax 3D max, Helsinki, Finland). CBCT machine was operated at 90 kV and 10 mA with a 9x16 cm field of view. Images were reconstructed with Romexis, the proprietary software of Planmeca. Voxel edge length was 0.2 mm and slice thickness was 1 mm.

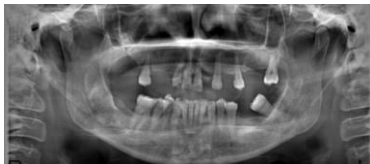

Figure-1. Panoramic radiograph shows bilateral elongated styloid process.

The length of styloid process were measured bilaterally in the CBCT sagittal plane. The bilateral outline of external auditory canal were drawn with aid of the brightness and contrast adjustments. The lowest point of the contour acoustic meatus was drawn under a horizontal line. The results showed that the right styloid process was approximately 68 mm, the left styloid process was approximately 45 mm (Fig 2A-B and 3A-B). Length of styloid process greater than 30 mm was recorded on bilateral elongation. This patient was diagnosed with Eagle's Syndrome by clinic and radiographic exams. The patient was redirected to an otolaryngologist for the treatment.

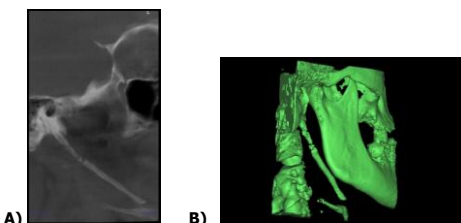


Figure-2. **A.** Sagittal CBCT image shows elongated styloid process at right side.  
**B.** CBCT 3D reconstructed image of the elongated styloid process on the right side.

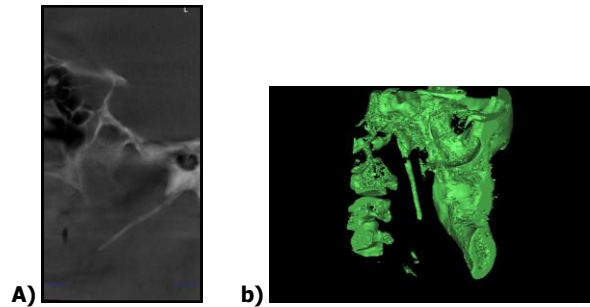


Figure-3. **A.** Sagittal CBCT image shows elongated styloid process at left side.  
**B.** CBCT 3D reconstructed image of the elongated styloid process on the left side.

## DISCUSSION

The styloid process is derived from the second branchial arch of Reichert's cartilage. This cartilage consist of four components: 1) the tympanohyale, a process attached to the inferior surface of the petrous part of the temporal bone and arises from the periotic capsule of the temporal bone; 2) stylohyale, a component which forms the greater part of the styloid process proper; 3) the ceratohyale, which forms the stylohyoid ligament; 4) the hypohyale, forming the lesser cornu of the hyoid bone.<sup>4,7</sup>

Styloid process belongs to the temporal bone of the skull and it lies anterior to the stylomastoid foramen. Being cylindrical in shape, the styloid process gradually tapers towards the apex just like a pinnacle. Its apex is located next to the tonsillar area in the lateral wall of pharynx, between external and internal carotid arteries. Its tip provides attachment to the stylohyoid ligament. There are few structures blended to the styloid process, which are in relation to the nerves and vessels. The stylopharyngeus, stylohyoid and styloglossus are the muscles which attach to the base, middle part and tip of the styloid process respectively. These muscles get the innervations from the 9<sup>th</sup>, 7<sup>th</sup> and 12<sup>th</sup> cranial nerves. Spinal accessory and vagus nerves run medial to the styloid process. The facial nerve runs anteromedial to this process before piercing the substance of the parotid gland. Glossopharyngeal nerve curves in close proximity to the styloid process.<sup>8,9</sup>

Prevalence of elongated styloid process or calcified stylohyoid ligament is about 4% of the general population, however; only a few of these

cases are symptomatic. There is no specific sex predilection for elongated of the styloid process, but female patient are known to be more symptomatic as compared to the male counterparts.<sup>10,11</sup>

It's morbidity ranges from 1,4% to 30% most of which consists of middle-aged people and females.<sup>2,3,13</sup>

In 1652, Pietro Marchetti introduced an elongated styloid process related to an ossifying process of the stylohyoid ligament. In 1937, Eagle, an otolaryngologist, later described Eagle's syndrome.<sup>3,4</sup> Eagle reported<sup>14</sup> that a normal styloid process measures between 25 mm to 30 mm and any length more than the above mentioned values, is considered as the pathogenic factor for Eagle Syndrome. Keur at al.<sup>9</sup> suggested that the styloid process length and its mineralized stylohyoid ligament, if appears more than 30 mm in a radiograph film, is considered as a significant predisposing factor. However, Jung et al.<sup>15</sup> suggested that, a styloid process of only more than 45 mm length should be considered be elongated.

Balbuena et al.<sup>16</sup> portrayed three etiologic theories to express the development of this syndrome. Congenital elongation of the styloid process due to the persistence of the cartilaginous precursor is defined as the first theory; the second one is the calcification of the stylohyoid ligament by a inexplicable process, and the third theory is the growth of osseous tissue at the insertion of the stylohyoid ligament.

Steinmann<sup>17</sup> presented three mechanisms which might case ossification: 1) the theory of reactive hyperplasia, when trauma stimulates the remnants of the original connective and fibrocartilaginous cells; 2) the theory of reactive metaplasia, or an abnormal healing following a trauma that activates ossification of the stylohyoid ligament; and 3) the theory of anatomic variance, which occurs without any different trauma.

The syndrome was divided into two types by Eagle: classic type and carotid artery type. The classic form develop after tonsillectomy, when scar tissue under the tonsillar fossa compresses and stretches cranial nerves V, VII, IX, and X. This form of Eagle Syndrome includes symptoms such as pain referred to the ear, foreign body sensation, and dysphagia. In rare cases, it can be accompanied by vocal changes. A second form of this condition which is not dependent upon tonsillectomy. The second type, carotid artery

type, occurs with other symptoms, such as migraines, and neurological symptoms, cause by irritation of the sympathetic nerve plexus. In addition , if the internal carotid artery is compressed, ipsilateral headaches may occur. If the external carotid artery is compressed, then there can be pain in the temporal and maxillary branch areas.<sup>7,18,19</sup>

The pathophysiological mechanisms for the pain of the eagle's syndrome as explained by Ceylan et al.<sup>20</sup> include:

- compression of the neural components, the glossopharyngeal nerve, the lower branch of the trigeminal nerve, and/or the chorda tympani nerve by the elongated styloid process
- fracture of the ossifiedstyloid ligament, followed by proliferation of granulation tissue which results in pressure on surrounding structures and occurrence of pain
- breaching on the carotid vessels by the styloid process resulting irritation of the sympathetic nerves in the arterial sheath
- degeneration and inflammatory changes in the tendinous part of the stylohyoid insertion, a condition defined as insertion tendinosis
- irritation of the pharyngeal mucosa due to direct compression by the styloid process
- in the post-tonsillectomy period, stretching and fibrosis involving the 5<sup>th</sup>, 7<sup>th</sup>, 9<sup>th</sup> and 10<sup>th</sup> cranial nerves

Diagnosis of Eagle's Syndrome is guided by the clinical history and physical and radiographic examinations. Palpation of the tonsillar fossa and local infiltration anesthesia are involved in physical examination. A bony projection and reproduced the characteristic pain is demonstrated on transpharyngeal palpation. Anesthetic injection in the tonsillar fossa results in symptom relief. For radiologic interpretation, panoramic radiography, lateral cephalometry, towne projection film or computed tomography (CT) may be used. In the panoramic view, the styloid process is visualized posteriorly to the external acoustic meatus with a descendant and anterior trajectory. When ligament is elongated, it reaches over one third of the length of the mandibular ramus.<sup>4,6</sup> Panoramic radiograph (OPTG) are a low-cost procedure with lower radiation exposure compared to the CT and are easy to interpret. However, caution is recommended when analysing and performing absolute



measurements and relative comparisons for this type examination because of the possible overlapping of anatomical structures (mandibular bone and teeth) and the occurrence of distortion and magnifications.<sup>21,22</sup> The OPTG can easily miss the findings, especially if styloid processes are not so long, due to superimposed teeth and mandible. Similarly, the conventional radiographs are also very non-specific and limited this context. Ultrasound and CT-scanning confirmed the diagnosis and MRA was used to determine the location of blood vessels in the surrounding area. Currently, CT can be defined as the standard method for the diagnosis of the Eagle's syndrome.<sup>22</sup> Multislice CT and 3D reconstruction is considered the best modality as it provides information about the actual length of the processes and their tract, and whether deviated medially or laterally along with the details of their relationships with other anatomical structures. Other related anatomical variants can also be documented before any surgical planning and intervention.<sup>1, 22, 23</sup>

Differential diagnoses of Eagle's syndrome include unerupted molar tooth, dental prosthesis implantation, diseases of temporomandibular joint, tumors in the oropharynx and laryngopharynx, and prosopalgia, sphenopalatine neuralgia, glossopharyngeal neuralgia, myofascial pain, mastoiditis, dentalgia, chronic amygdalitis, pharyngitis.<sup>3,8,24</sup> In our patient, we have determined that the appropriate with literature by her clinical symptoms and radiological features.

The treatment plan includes both medical and surgical options. Medical therapy includes reassurance, analgesics and anti-inflammatory medications. Severe cases are dealt with surgically using two approaches, intraoral and external, with both having their own advantages and disadvantages.<sup>1</sup>

**Ayşenur Yıldız:** ORCID ID:0000-0002-7041-2819.

**Berçeste Polat Akmansoy:** ORCID ID:0000-0003-2330-7745.

**Filiz Namdar Pekiner:** ORCID ID: 0000-0001-7426-5587.

## REFERENCES

1. Kamal A, Nazir R, Usman M, Salam B, Sana F. Eagle syndrome; radiological evaluation and management. J Pak Med Assoc 2014;64: 1315-17.
2. Werhun EL, Weindenhaft MC, Palacios E, Neitzschmann H. Styloid syndrome, also known as Eagle syndrome: an uncommon cause of facial pain. Ear Nose Throat J. 2014;93:384-5.
3. Dou G, Zhang Y, Zong CL, Chen YL, Guo YX, Tian L. Application of surgical navigation in styloidectomy for treating Eagle's syndrome. Therapeutics and clinic risk management 2016;12 575-83.
4. Moon CS, Lee BS, Kwon YD, Choi BJ, Lee HW, Yun SU, Ohe JY. Eagle's syndrome: a case report J Korean Assoc Oral maxillofac Surg 2014;40;43-47.
5. Valerio CS, Peyneau PD, de Sousa AC, Cardoso FO, de Oliveira DR, Taitson PF, et al. Stylohyoid syndrome: surgical approach. J Craniofac Surg 2012;23:e138-140.
6. Murtagh RD, Caracciolo JT, Fernandez G. CT findings associated with Eagle syndrome. AJNR Am J Neuroradiol 2001;22:1401-2.
7. Ghosh LM, Dubey SP. The syndrome of elongated styloid process. Auris Nasus Larynx 1999;26:169-175.
8. Vadgaonkar R, Murlimanju BV, Prabhu LV, Rai R, Pai MM, Tonse Mi Jiji PJ. Morphological study of styloid process of the temporal bone and its clinical implications. Anat Cell Biol. 2015; 48: 195-200.
9. Keur JJ, Campbell JP, McCarthy JF, Ralph WJ. The clinical significance of the elongated styloid process. Oral Surg Oral Med Oral Pathol 1986;61:399-404.
10. Ramachandra KK, Krishnan SA, and Reddy SSP. Carotid type of Eagle's syndrome. J Indian Soc Periodontol. 2015; 19: 336-8.
11. Langlais RP, Miles DA, Van Dis ML. Elongated and mineralized stylohyoid ligament complex: A proposed classification and report of Eagle's syndrome. Oral Surg Oral Med Oral Pathol. 1986;61:527-32.
12. Becker C, Pfeiffer J. Eagle's syndrome. Am J Med. 2013;126:e3-e4.
13. Eagle WW. The symptoms, diagnosis and treatment of the elongated styloid process. Am Surg. 1962;28:1-5.
14. Jung T, Tschernitschek H, Hippen H, Schneider B, Borchers L. Elongated styloid process: when is it really elongated? Dentomaxillofac Radiol. 2004; 33: 119-124.
15. Balbuena L, Hayes D, Ramirez SG, Johnson R. Eagle syndrome (elongated styloid process). South Med J 1997;90:331-4.



16. Steinmann EP. Styloid process in absence of an elongated process. *Acta Otolaryngol.* 1968;66:347-56.
17. Shahoon H, Kianbakht C. Symptomatic Elongated Styloid Process or Eagle's Syndrome: A Case Report. *J Dent Res Dent Clin Dent Prospects.* 2008; 2: 102–5.
18. Min Kyu Han, MD, Do Wan Kim, MD, and Jong Yeun Yang, MD. Non Surgical Treatment of Eagle's Syndrome - A Case Report -. *Korean J Pain.* 2013; 26: 169–72.
19. Ceylan A, Köybaşıoğlu A, Celenk F, Yılmaz O, Uslu S. Surgical treatment of elongated styloid process: experience of 61 cases. *Skull base* 2008;18:289-95.
20. **21.** Vieira EMM, Guedes OA, De Morais S, De Musis CR, De Albuquerque PA, Borges AH. Prevalence of Elongated Styloid Process in a Central Brazilian Population. *J Clin Diagn Res.* 2015; 9: ZC90–ZC92.
21. Thoenissen P, Bittermann G, Schmelzeisen R, Oshima T, Fretwurst T. Eagle's syndrome-A non-perceived differential diagnosis of temporomandibular disorder. *Int J Surg Case Rep.* 2015;15:123-6.
22. Karam C, Koussa S. Eagle Syndrome: the role of CT scan with 3D reconstructions. *J Neuroradiol* 2007;34: 344-5.
23. Dunn-Ryznyk LR, Kelly CW. Eagle syndrome: a rare cause of dysphagia and head and neck pain. *JAAPA* 2010;23:31-32.
24. Ciorba A, Savini S, Morolli F, et al. Orafacial pain and Eagle syndrome: cues from a clinical series. *Minerva Stomatol.* 2014;63:361-7.

#### **Yazışma Adresi**

Filiz Namdar Pekiner,  
Marmara University,  
Faculty of Dentistry,  
Department of Oral Diagnosis and Radiology,  
Başibüyük Sağlık Yerleşkesi  
Başibüyük Yolu 9/3  
34854, Maltepe/ Istanbul - Turkey  
E-mail address:fpekiner@gmail.com

