

BALIKESIR MEDICAL JOURNAL

Kolorektal Poliplerin Klinikopatolojik Özellikleri: Türkiye'nin Kuzey-Doğu Anadolu Bölgesinden Retrospektif Bir Çalışma

Clinicopathologic Features Of Colorectal Polyps: A Retrospective Study From North-Eastern Anatolia Region Of Turkey

Enver YARIKKAYA¹, Şenay ERDOĞAN DURMUŞ², Rabia DEMİRTAŞ³

1- İstanbul Eğitim ve Araştırma Hastanesi, Patoloji Bölümü

2- İstanbul Üniversitesi Cerrahpaşa Tıp Fakültesi, Patoloji Anabilim Dalı

3- Erzurum Bölge Eğitim ve Araştırma Hastanesi, Patoloji Bölümü

Öz

Amaç: Bu çalışmanın amacı kolon poliplerinin lokalizasyon, prezentasyon ve histopatolojik özelliklerini incelemektir.

Gereç ve Yöntemler: 2014-2016 yılları arasında Ağrı Devlet Hastanesi ve Erzurum Bölge Eğitim ve Araştırma Hastanesi'nde kolon polibi nedeni ile kolonoskopi yapılan 123 hastanın 153 biyopsi örneğini retrospektif olarak inceledik.

Bulgular: Ortalama yaş 58.9 ± 15.6 yıldır (Dağılım: 19-90 yıl). Hastaların 78'i (% 63,4) erkek, 45'i (% 36,6) kadındır. 25 (% 20.3) hastada iki veya üç (çoklu) polip vardı. 4 biyopsi örneğinde (% 2.6) tübüler adenomadan karsinom tanısı kondu. En yaygın polip türü adenomatöz polip (n: 123, % 80.3) idi. Poliplerin en sık anatomik lokasyonları 45 (% 29.4) olguda rektum, 45 (% 29.4) olguda sigmoid kolon idi. Poliplerin ortalama büyüklüğü 4,1 mm (aralık: 1 mm-20 mm) idi. Yüksek dereceli displazi, 123 (% 13.2) adenomatöz polipten 20'sinde saptandı. Yüksek dereceli displazi ve düşük dereceli displazili adenomatöz poliplerde ortalama çaplar anlamlı olarak farklıydı (p < 0.05).

Sonuç: Poliplerin çoğu 50 yaş ve üzerindeki hastalarda tanımlandı. Poliplerin % 50'sinden fazlası kolonun rektosigmoid bölümünde bulundu. Poliplerin çoğunluğu adenomatöz idi ve geniş çaplı poliplerde yüksek dereceli displazi saptandı.

Anahtar kelimeler: Adenomatöz polipler; adenoma; displazi

Abstract

Objectives: The aim of this study is to examine the patient characteristics, locations, presentations and histopathological features of colon polyps.

Material and methods: We analyzed 153 biopsy specimens of 123 patients who underwent colonoscopy with biopsy of colonic polyps during a two-year period from 2014 to 2016, in Ağrı State Hospital and Erzurum Regional Training and Research Hospital, retrospectively.

Results: The mean age was 58.9±15.6 years (Range: 19-90 years). 78 (63.4%) patients were males and 45 (36.6%) patients were females. 25 (20.3%) patients had two or three (multiple) polyps. In 4 biopsy specimens (2.6%) were diagnosed with carcinoma arose from tubular adenomas. The most common type of polyp was the adenomatous polyp (n:123, 80.3%). The most common anatomical locations of polyps were the rectum in 45 (29.4%) cases and the sigmoid colon in 45 (29.4%) cases. The mean size of polyps was 4.1 mm (range: 1mm-20 mm). High-grade dysplasia was found in 20 of 123 (13.2%) adenomatous polyps. Mean diameters were significantly different in adenomatous polyps with high-grade dysplasia and low-grade dysplasia (p<0.05).

Conclusion: Most of the polyps were identified in patients aged 50 years or older. More than 50% of the polyps were found in the rektosigmoid part of the colon. The majority of the polyps were adenomatous and high-grade dysplasia was detected in large diameter polyps.

Key words: adenomatous polyps; adenoma; dysplasia

Gönderilme Tarihi: 5-8-2018

Kabul Tarihi: 7-9-2018

Atıf İçin: Enver YARIKKAYA, Şenay ERDOĞAN DURMUŞ, Rabia DEMİRTAŞ. Kolorektal Poliplerin Klinikopatolojik Özellikleri: Türkiye'nin Kuzey-Doğu Anadolu Bölgesinden Retrospektif Bir Çalışma, Balıkesir Medical Journal, 2018 2(3):178-179

Sorumlu Yazar: Enver YARIKKAYA

İstanbul Eğitim ve Araştırma Hastanesi, Patoloji Bölümü, Samatya, 34098 İstanbul.

Phone: 0554 773 82 75

e-mail: enveryarikkaya@gmail.com

INTRODUCTION

Colorectal cancer (CRC) is one of the most commonly diagnosed cancers, after lung and breast cancers and is responsible for significant mortality and morbidity (1). Adenocarcinoma constitutes 85% of colorectal malignancies and originates from adenomatous polyps (2). It is well established that colorectal cancer develops from a series of precursor epithelial polyps, which include conventional adenomas, incorporating tubular adenomas (TA) and villous/tubulovillous adenomas (VA/TVA) and serrated polyps, incorporating hyperplastic polyps (HP), sessile serrated adenomas/polyps (SSA) and traditional serrated adenomas (TSA) (3). The neoplastic polyps are of primary importance because they harbor a malignant potential, which represents a stage in the development of colorectal cancer. For this reason, it is essential to identify these polyps at a sufficiently early stage when a simple office procedure to remove them can stop the development of colorectal cancer and prevent disease and death (4).

Serrated polyps are lesions characterized by the presence of elongated crypts with a luminal saw tooth growth pattern ('serration'). Serrated polyps are categorized as hyperplastic polyps, sessile serrated adenomas and traditional serrated adenomas according to the WHO (5).

Hyperplastic polyps are the most common type of polyps in the colon (6). They tend to be small (<5 mm), sessile, and are most common in the left colon and rectum (5). They are found with increasing frequency in individuals older than 40 years of age, are more common in men than in women, and are more common in westernized populations (7). Hyperplastic polyps are usually considered inconsequential and are not described as part of adenoma-carcinoma pathway (8). However, it is now recognized that some types of hyperplastic polyps may progress to malignancy (6).

In contrast to left-sided "hyperplastic" polyps, right-sided "serrated" polyps are often larger (>0.5 cm) (6). SSA account for 2–15% of all colon polyps (5). Recognition and differentiation of SSA from hyperplastic polyps are of clinical importance, because SSA are associated with an increased risk for colorectal neoplasia (7).

TSA are a rare and unique type of serrated polyp. They account for <1% of all colon polyps, and tend to occur in the distal colon and rectum (5). TSAs are equally distributed between the genders and usually diagnosed in the sixth to seventh decade of life (3). The absolute risk for neoplastic transformation in a TSA is unknown. However, as high-grade dysplasia or carcinoma has been found in association with TSA, they are best managed as classic adenomatous polyps (7).

Hamartomatous polyps are characterized by a disorganized growth of tissue indigenous to the site; they can be solitary or syndromic (9).

Adenomas are common lesions that are almost always asymptomatic and may be broadly classified as conventional (tubular, tubulovillous, or villous), serrated, or flat (6). Adenomas smaller than 1 cm in diameter tend to be evenly distributed throughout the colorectum. In contrast, adenomas 1 cm or larger in diameter are more commonly found in the sigmoid colon and rectum (7). In adenomatous polyps, dysplasia ranges from low-grade to high-grade dysplasia (10). All adenomatous polyps can transform into carcinoma.

The risk of malignancy with adenomatous polyps is interconnected with histological architecture, polyp size, and the grade of dysplasia (10).

Our study is first of its kind in the region of Eastern Anatolia, Turkey, giving a detailed analysis of the epithelial colorectal polyps as diagnosed in the histopathology laboratory of Erzurum Regional Training and Research Hospital and Ağrı State Hospital.

MATERIAL METHODS

We reviewed 153 biopsy specimens of 123 patients who underwent colonoscopy with biopsy of colonic polyps during a two-year period from 2014 to 2016, in Ağrı State Hospital and Erzurum Regional Training and Research Hospital. Data was collected from two pathology departments. Parameters, such as the gender and age of the patients, and clinical information, such as the site of polyps, were obtained from the information systems of hospitals. Hematoxylin and Eosin (H&E) stained slides were reviewed by three pathologists. The polyps were categorized depending on the histological type into hamartomatous polyps, serrated polyps (hyperplastic polyps, SSA, TSA) and adenomatous polyps (tubular, tubulo-villous and villous) with high/low grade dysplasia.

Data analysis was performed using the SPSS 20.0 program. In the evaluation of results, descriptive statistics were shown in the form of mean \pm standard deviation, nominal variables were shown as number of cases and the percentage (%).

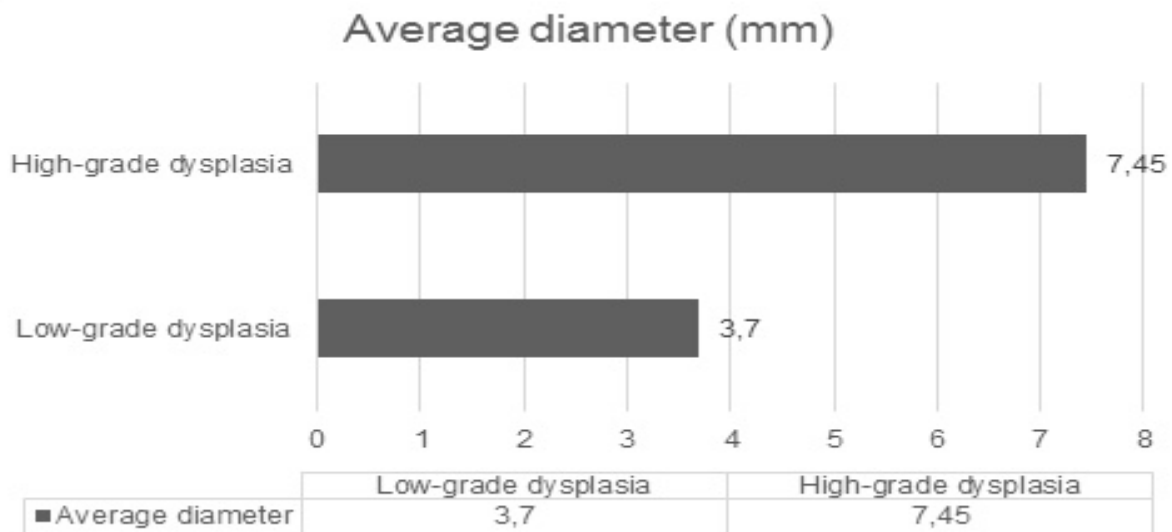


Figure 1 Mean diameters were not very different for adenomatous polyps and serrated polyps.

RESULTS

The mean age was 58.9 ± 15.6 years (range: 19-90 years). 78 (63.4%) patients were males and 45 (36.6%) patients were females. 25 (20.3%) patients had two or three (multiple) polyps. In 4 biopsy specimens (2.6%) were diagnosed as carcinoma arose from tubular adenomas. The most common type of polyp was the adenomatous polyp (n:123, 80.3%). 118 out of 153 polyps (77.1%) were TA, and 5 out of 153 polyps (3.3%) were TVA. These were followed by serrated polyps such as hyperplastic

polyps 21(13.7%) and SSA 1 (0.7%). 4 out of 153 polyps (2.6%) were diagnosed as hamartomatous polyps. There was no case of villous adenoma and traditional serrated adenoma (Table 1).

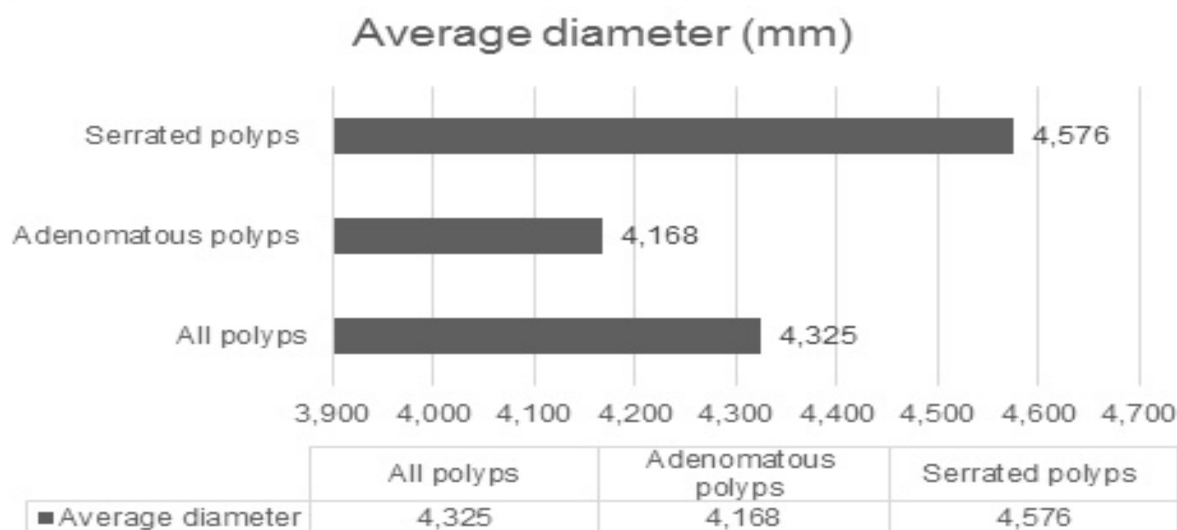


Figure 2 Mean diameters were significantly different in adenomatous polyps with high-grade dysplasia and low-grade dysplasia ($p < 0.05$)

The most common anatomical locations of polyps were the rectum in 45 (29.4%) cases and the sigmoid colon in 45 (29.4%) cases, followed by the descending colon in 29 (19.0%), the transverse colon in 14 (9.1%), the ascending colon in 13 (8.5%), the splenic flexure in 4 (2.6%) and the hepatic flexure in 3 (2.0%) cases.

For adenomatous polyps, the most common location was the sigmoid colon in 39 (31.8%) cases followed by the rectum in 30 (24.4%), the descending colon in 23 (18.7%), the transverse colon in 14 (11.4%), the ascending colon in 11 (8.9%), the splenic flexure in 3 (2.4%) and the hepatic flexure in 3(2.4%) cases. The most common location of serrated polyps was the rectum in 11 (50%) cases and followed by the descending colon in 5 (22.7%), the sigmoid colon in 3 (13.7%), the ascending colon in 2 (9.1%) and the splenic flexure in 1 (4.5%) of the cases. Of the 4 hamartomatous polyps, 2 were located in the sigmoid colon and 2, in the rectum.

Type of polyps	M/F	Mean age	No (%)
Hamartomatous	3/1	49.7	4 (2.6%)
Serrated polyps			
-Hyperplastic	12/8	62.1	21 (13.7%)
-Sessile Serrated Adenoma/Polyp	1/-	26	1 (0.7%)
Adenomatous			
-Tubular	62/36	59.3	118 (77.1%)
-Tubulovillous	3/2	71.6	5 (3.3%)
Carcinoma arisen from tubular adenomas	2/2	58.2	4 (2.6%)
Total	83/49	58.9±15.6	153 (100%)

Table 1 Classification and demographic characteristics of polyps

The mean size of polyps was 4.1 mm (range: 1mm-20 mm). Mean diameters were not very different for adenomatous polyps and serrated polyps (Figure 1). Ten (6.5%) polyps were >10 mm. 4 (40%) of them were tubular adenomas; 4 (40%) of them were hamartomatous polyps, and 2 (20%) of them were tubulovillous adenomas. 3 out of 10 high-size polyps which were >10 mm showed high-grade dysplasia (2 TA and 1 TV).

	Low grade dysplasia	High grade dysplasia
Gender		
-Male	56 (86.1%)	9 (13.9%)
-Female	30 (78.9%)	8 (21.1%)
Age range		
-≤25	3 (100.0%)	0 (0.0%)
-26-50	14 (77.8%)	4 (22.2%)
-≥51	69 (84.1%)	13 (15.9%)
Histological type		
-Tubular	100 (84.7%)	18 (15.3%)
-Tubulovillous	3 (60.0%)	2 (40.0%)
Location		
-Right side colon (AC, HF, TC)	24 (77.4%)	7 (22.6%)
-Left side colon (SF, DC, SC, R)	79 (85.9%)	13 (14.1%)

(AC: Ascending colon, HF: Hepatic flexure, TC: Transverse colon, SF: Splenic flexure, DC: Descending colon, SC: Sigmoid colon, R: Rectum)

Table 2 The correlations between dysplasia and gender, age, histological types and locations of polyps.

High-grade dysplasia was found in 20 out of 123 (13.2%) adenomatous polyps and in 17 patients. High-grade dysplasia was found in 9 males and 8 females ($p>0.05$). Higher rate of high-grade dysplasia was associated with tubulovillous architecture (40.0%) compared to tubular type (15.3%) (Table 2). Mean diameters were significantly different in adenomatous polyps with high grade dysplasia and low-grade dysplasia ($p<0.05$) (Figure 2).

The majority of adenomatous polyps with high-grade dysplasia were located on the left side of the colon. 5 out of 20 adenomatous polyps with high-grade dysplasia were located in the rectum; 5 of them located in the sigmoid colon and 3 of them located in the descending colon.

DISCUSSION

Colorectal cancer remains one of the three most common cancers with a lifetime incidence of about 5%. Colonoscopy remains the gold-standard screening tool for colon cancer by removing precancerous adenomas, thus halting the adenoma-carcinoma sequence (11).

During the two-year study period (2014-2016), we evaluated 153 colorectal polyps reviewed by three pathologists; where 63,4% of the cases were men and 36,6% were women. Male domination in our study was consistent with many studies from this region and the world in general (1). However, one scientist group from Romania have reported slight female preponderance (56.6%) in their study of 795 colonoscopies having 183 cases

of colorectal polyps (12). Similarly, another group from Iran, despite giving a male predominance figures in the total count of polyps, further qualifies that neoplastic polyps were more frequent in women; and non-neoplastic polyps were more common in males (13).

In the recent literature of colorectal polyps, mean age has been reported as above 50 years, reaching up to a maximum of 58 years (14, 15). One group from Hong Kong studying advanced polyps and CRC, found the mean age of 69.2 for advanced polyps (16). In our study, the average age of the colorectal polyp patients was 58,9 years.

Out of 153 polyps, there were 123 adenomatous polyps (80.3%), followed by 21 hyperplastic polyps (13.7%). Nearly all the recently reviewed literature involving patients from the Middle East reported similar outcomes (1, 13, 17, 18).

Concerning the histological subtypes of 123 adenomatous polyps; in our study, 77.1% were tubular adenoma, followed by 3.1% tubulovillous. There was no case of villous adenoma. The tubular type was the most common histological feature of adenomas in the present study, in accordance with the results of other reports (1).

Anatomical distribution of polyps can give an idea about the risk of colorectal cancer development (19). We followed the anatomic distribution of the polyps at the level of the colon and found 29.4% of polyps in the sigmoid colon and equally by 29.4% in the rectum. For adenomatous polyps, the most common location was the sigmoid colon in 39 (31.8%) cases followed by the rectum in 30 (24.4%) and the descending colon in 23(18.7%), which is in accordance with other studies. On the other hand, Santos et al. found a higher number of polyps, which were located in the right colon in their study (20).

This was not a screening study, but it has shown that in our study population a significant number of adenomas lie distal to the splenic flexure. However, in the absence of right-sided lesions, it is expected that an analysis of the colon limited to the splenic flexure would miss 22,2% of the polyp's present.

In the majority of studies, high-grade dysplasia was associated with polyp size (1, 10). Similarly, in our study mean diameters were significantly different in adenomatous polyps with high-grade dysplasia and low-grade dysplasia. On the other hand, out of all polyps, in our study only 6.5% were greater than 10mm in diameter and 93.5% were less than 10 mm in size and 3 out of 10 high-size polyps which >10 mm showed high-grade dysplasia. This difference from literature may explained with sampling of polyps. When the biopsy was taken, the polyp was not sampled entirely.

In our study, 86.8% of adenomatous polyps had low-grade dysplasia and 13.2% had high-grade dysplasia. This study found that a higher rate of dysplasia was associated with tubulovillous (40.0%) compared to tubular type (15.3%). A similar observation was made in a Saudi Arabian study of 166 adenomatous polyps, which concluded that the villous (95.7%) and tubulovillous (66.7%) structures were strongly associated with high-grade dysplasia (10).

The study faced some limitations. Our sample included mostly symptomatic patients, in which the estimates may be different from screening studies with asymptomatic

individuals. Nevertheless, the results of this study can provide a good infrastructure for the next preventive program and have clinical implications for CRC screening.

In conclusion, most of the polyps were identified in patients aged 50 years or older. More than 50% of the polyps were found in the recto sigmoid part of the colon. The majority of the polyps were adenomatous. Mean diameters were significantly different in adenomatous polyps with high-grade dysplasia and low-grade dysplasia ($p < 0.05$).

REFERENCES

1. Albasri A, Yosef H, Hussainy A, et al. Profile of colorectal polyps: a retrospective study from King Fahad Hospital, Madinah, Saudi Arabia. *Asian Pac J Cancer Prev.* 2014; 15 (6): 2669-2673.
2. Mirzaie AZ, Abolhasani M, Aryamanesh A. Left sided colorectal adenomatous polyps have more risk for high grade dysplasia. *Acta Medica Iranica.* 2013; 51(3): 172-177.
3. Kalimuthu SN, Chelliah A, Chetty R. From traditional serrated adenoma to tubulovillous adenoma and beyond. *World J Gastrointest Oncol.* 2016; 8(12): 805–809.
4. Shussman N, Wexner SD. Colorectal polyps and polyposis syndromes. *Gastroenterol Rep (Oxf).* 2014; 2(1): 1-15.
5. Gibson JA, Odze RD. Pathology of premalignant colorectal neoplasia. *Digestive Endoscopy.* 2016; 28: 312–323.
6. Hornick JL, Odze RD. Polyps of large intestine. In: Odze RD, Hornick JL (eds). *Odze and Goldblum surgical pathology of the GI tract, liver, biliary tract, and pancreas.* 3rd edition. China: Saunders-Elsevier; 2015, 607-657.
7. Iacobuzio-Donahue CA. Epithelial neoplasms of the colorectum. In: Iacobuzio-Donahue CA, Montgomery E. (eds). *Gastrointestinal and Liver Pathology.* 2nd edition. China: Saunders-Elsevier; 2012, 410-441.
8. Nouraie M, Hosseinkhah F, Zamanifekri B, et al. Clinicopathological features colon polyps from African- Americans. *Dig Dis Sci.* 2010; 55(5): 1442–1449.
9. Vyas M, Yang X, Zhang X. Gastric hamartomatous polyps—Review and update. *Clin Med Insights Gastroenterol.* 2016; 9: 3–10.
10. Qureshi A, Shihi SA, Ali Z. A retrospective study of clinico-pathological characteristics of colonic polyps in adults seen at a tertiary care centre. *J Pak Med Assoc.* 2017; 67: 12-14.
11. Qumseya BJ, Coe S, Wallace MB. The effect of polyp location and patient gender on the presence of dysplasia in colonic polyps. *Clin Transl Gastroenterol.* 2012; 3(7): e20.
12. Munteanu M, Serban C, Savoiu G, Popescu A, Sporea I. Clinical, endoscopic and morphological study of colorectal polyps. *Ann RSCB.* 2009; 14, 1-4.
13. Zahir ST, Binesh F, Hashemian Z, Hakimi A. Demographic survey on colorectal polyps in Shahid Sadoughi Hospital, Yazd, Iran. *Rawal Medical Journal.* 2010; 35, 31-3.
14. Wisedopas N, Thirabanjasak D, Tawevisit M. A retrospective study of colonic polyps in King Chulalongkorn Memorial Hospital. *J Med Assoc Thai.* 2005; 88, 36-41.
15. Bafandeh Y, Daghestani D, Esmaili H. Demographic and anatomical survey of colorectal polyps in an Iranian population. *Asian Pac J Cancer Prev.* 2005; 6, 537-40.
16. Lam TJ, Wong BC, Mulder CJ, et al. Increasing prevalence of advanced colonic polyps in young patients undergoing colonoscopy in a referral academic hospital in Hong Kong. *World J Gastroenterol.* 2007 13, 3873-7.
17. Al-Enezi SA, Alsurayei SA, Ismail AE. Adenomatous colorectal polyps in patients referred for colonoscopy in a regional hospital in Kuwait. *Saudi J Gastroenterol.* 2010; 16: 188-93.
18. Al-Rashed RS, Al-Amri SM. Colonic polyps: Experience from King Khalid University Hospital. *Ann Saudi Med.* 1996; 16: 180-3.
19. Zare-Mirzaie A, Abolhasani M, Aryamanesh A. Left Sided Colorectal Adenomatous Polyps Have More Risk for High Grade Dysplasia. *Acta Med Iran.* 2013; 51:172-7.
20. Valarini SBM, Bortoli VT, Wassano NS, et al. Correlation between location, size and histologic type of colorectal polyps at the presence of dysplasia and adenocarcinoma. *J. Coloproctol.* 2011; 31:3.