

## Is there a relationship between migraine disease and the skull base angles?

*Migren hastalığı ile kafa tabanı açıları arasında bir ilişki var mı?*

Neşe Asal, Mehmet Hamdi Şahan

Kırıkkale University, Faculty of Medicine, Department of Radiology, Kırıkkale, Turkey

Received: 30.03.2017

Accepted: 08.08.2017

Doi: 10.21601/ortadogutipdergisi.411138

### Abstract

**Aim:** The aim of the study was to determine whether there were variability in the skull base according to magnetic resonance images in migraine patients.

**Material and Method:** A total of 130 magnetic resonans images including 65 migraine and 65 control groups in the age range 18-50 years were evaluated retrospectively. Modified basal angle (MBA), clivo-axial angle in migraine and control groups were measured by a radiologist in magnetic resonans images. The independent t test was used to compare between the groups. The level of significance was set at  $p < 0.05$ . In addition, basilar invagination (according to McGregor and Chamberlain line) was evaluated.

**Results:** The migraine group was 13 male, 52 female (mean age of male  $30.38 \pm 11.5$ , mean age of female  $32.54 \pm 9$  years). The control group was 15 males, 50 females (mean age of male  $34.4 \pm 8.6$ , mean age of female  $33.14 \pm 9.7$  years). In the migraine group; the modified basal angle average was  $123.78 \pm 6.06^\circ$  and the clivo-axial angle average was  $142.65 \pm 8.73^\circ$ . In the control group; the modified basal angle average was  $121.6 \pm 5.5^\circ$  and the clivo-axial angle average was  $153.66 \pm 6.35^\circ$ . Significant differences were detected between the groups. There was no difference between the genders for both groups. In the migraine group; according to McGregor line in 3 patients and McGregor and Chamberlain line in 2 patients, basilar invagination was observed. Basilar invagination was not detected in the control group.

**Conclusion:** Changes in the skull base angles (modified basal angle and clivo-axial angle) are observed in migraine patients according to magnetic resonance images.

**Keywords:** Magnetic resonans imaging, migraine, skull base

## Öz

**Amaç:** Migren hastalarında, manyetik rezonans görüntülerine göre kafa tabanı açılarında değişkenliğin olup olmadığının belirlenmesi amaçlandı.

**Gereç ve Yöntem:** 18-50 yaş aralığında 65 migren tanılı ve 65 kontrol grubu olmak üzere toplam 130 manyetik rezonans görüntüleri retrospektif olarak incelendi. Migren ve kontrol grubu arasında modifiye bazal açı, klivo-aksiyal açı manyetik rezonans görüntülerde tek radyolog tarafından ölçüldü. Gruplar arasında karşılaştırmada bağımsız t testi kullanıldı.  $P < 0.05$  istatistiksel olarak anlamlı olarak kabul edildi. Ayrıca baziler invajinasyon (McGregor ve Chamberline hattına göre) açısından değerlendirme yapıldı.

**Bulgular:** Migren grubu 13 erkek, 52 kadını (yaş ortalaması erkek  $30.38 \pm 11.5$ , kadın  $32.54 \pm 9$  yıl). Kontrol grubu 15 erkek, 50 kadını (yaş ortalaması erkek  $34.4 \pm 8.6$ , kadın  $33.14 \pm 9.7$  yıl). Migren grubunda; modifiye bazal açı ortalaması  $123.78 \pm 6.06^\circ$ , klivo-aksiyal açı ortalaması  $142.65 \pm 8.73^\circ$  idi. Kontrol grubunda; modifiye bazal açı ortalaması  $121.6 \pm 5.5^\circ$ , klivo-aksiyal açı ortalaması  $153.66 \pm 6.35^\circ$  idi. Gruplar arasında anlamlı farklılık saptandı ( $p < 0.05$ ). Her iki grup için cinsiyetler arasında farklılık saptanmadı. Ayrıca migren grubunda; 3 hastada McGregor hattına göre ve 2 hastada McGregor ve Chamberline hattına göre baziler invajinasyon izlendi. Kontrol grubunda baziler invajinasyon saptanmadı.

**Sonuç:** Migren hastalarında, manyetik rezonans görüntülerine göre kafa tabanı açılarında (modifiye bazal açı ve klivo-aksiyal açı) değişiklikler görülmektedir.

**Anahtar Kelimeler:** Manyetik rezonans görüntüleme; migren; kafa tabanı

## Introduction

Migraine is a chronic, paroxysmal and neurovascular disease [1]. Although there are changes in cerebral vascular reactivity, the etiology is controversial [2]. There are many studies on structural changes in the brain of migraine patients. They are usually based on findings of microvascular changes in gray and white matter [2]. The skull base interconnects vascular structures and cerebrospinal fluid (CSF) between spinal canal and cranium. Craniospinal hydrodynamic values may vary depending on the relationship of pressure, flow of blood and CSF between cranium and spinal canal [3]. As far as we know about skull base angles in migraine disease, no information is available in the literature.

The aim of the study was to determine whether there were variability in the skull base according to magnetic resonance images (MRI) in migraine patients.

## Material and Method

In this study, a total of 130 cranial MRI including in which 65 migraine and 65 control groups in the age range of 18-50 years were examined retrospectively between January 2014 and December 2017 in our clinic. Migraine patients were selected from patients diagnosed with migraine according

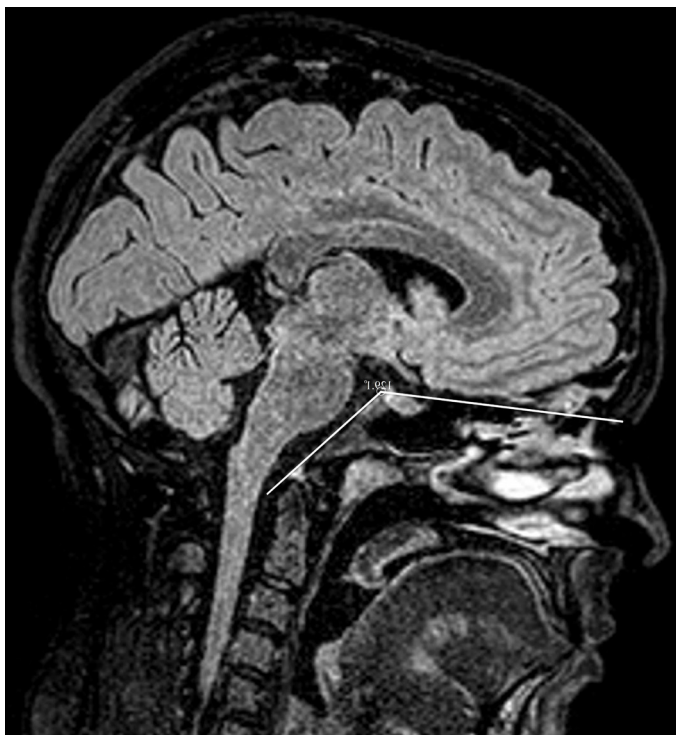to the International Headache Society (IHS) criteria [4]. The study included all migraine patients and no distinction was made between subgroups. The control group was selected from those with normal cranial MRI performed for any reason. Ethics committee approval was obtained from Kırıkkale University Faculty of Medicine was also taken (Date: 20.03.2018 Number: 06/06).

Exclusion criteries: Clinical conditions such as craniofacial anomaly, osteogenesis imperfecta, craniocleidodysostosis, Chiari malformation, Hurler's syndrome, Paget's disease, osteomalacia, rickets, rheumatoid arthritis, neurofibromatosis, infection and trauma and tumors that could cause changes in the angle of the skull base were excluded from the study. Patients older than 50 years were not included in the study due to ischemic and degenerative changes.

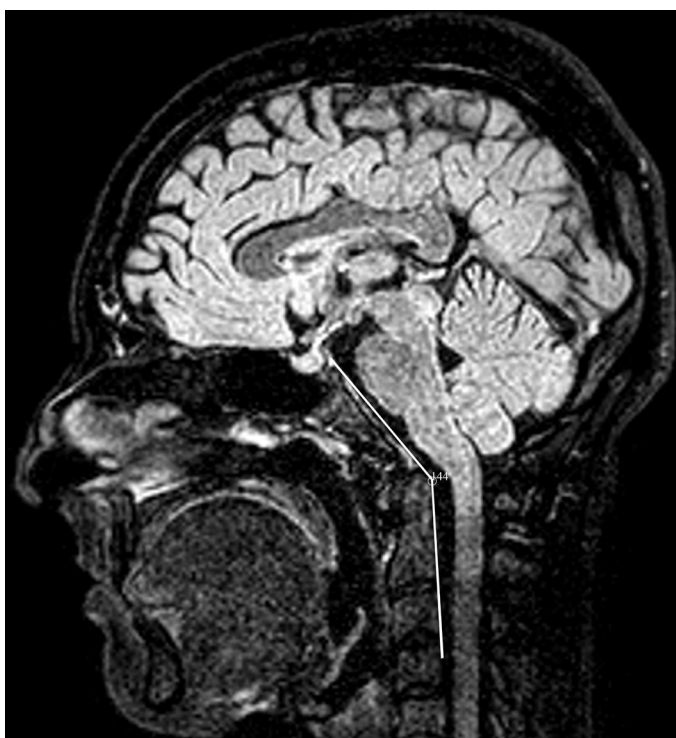MRI imaging and examination technique: MRI images were performed using a 1.5 Tesla MRI (Philips MRI Systems, Achiava Release 3,2 Level 2013-10-21, Philips Medical Systems Nederland B.V.) with a cranial coil. Evaluation was performed on T1 sagittal or FLAIR sagittal images.

## Examination technique

1.Modified basal angle (MBA); is the angle between the line extending from dorsum sella to nasiona and the line drawn along posterior boundary of the clivus [3,5] (fig 1).

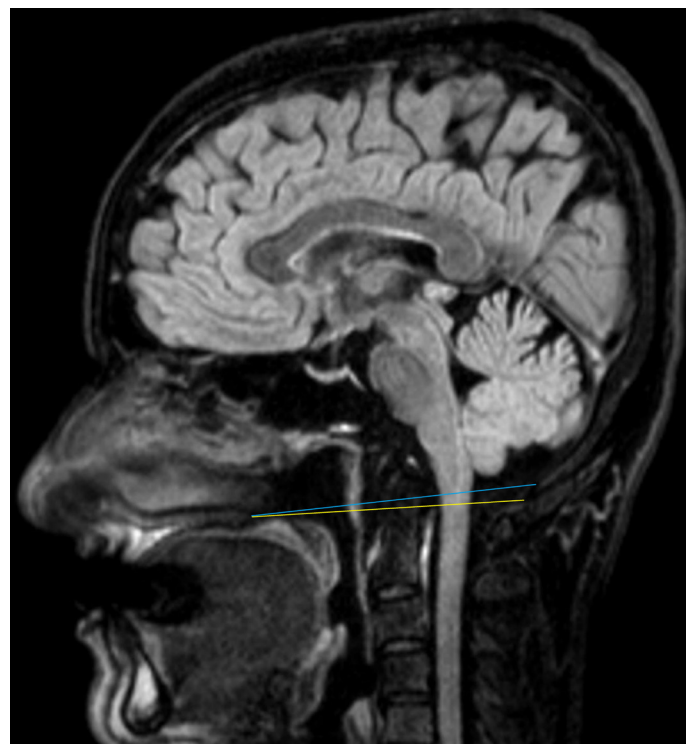

**Figure 1.** Modified basal angle in sagittal FLAIR weighted-image  
 2. Clivo-axial angle (CAA); is the angle between the line extending from dorsum sellae to basion and the line drawn along the boundary superoposterior and inferoposterior corners of the C2 vertebrae [3,6-8] (fig 2).



**Figure 2.** Clivo-axial angle in sagittal FLAIR weighted-image

3. Basilar invagination; according to McGregor and Chamberlain line, the superiority of the odontoid process was evaluated (fig 3).



**Figure 3.** Basilar invagination in sagittal FLAIR weighted-image, the Chamberlain line (blue), the McGregor line (yellow)

a. The McGregor line extends from the hard palate to the lowest point of the occipital squama [7,8]

b. The Chamberlain line extends from the hard palate to the midpoint of the posterior margin of the foramen magnum [7,8].

In the study, all measurements on MRI were performed by the same radiologist, experienced in neuroradiology, without knowledge of migraine disease (N.A.).

Statistical analysis: Statistical analyses were performed using SPSS version 20 software (SPSS, Chicago, IL, U.S.A). Data were expressed as mean  $\pm$  standard deviation (SD) or median (range). Categorical changes such as sex between the groups were compared with the chi-square test. Non-categorical changes were compared between the age, MBA and CAA groups by the independent t test. The level of significance was set at  $p < 0.05$ .

**Results**

The migraine group were included 13 male and 52 female of patients (mean age of male  $30.38 \pm 11.5$ , mean age of female  $32.54 \pm 9$  years). The control group were included 15 males and 50 females (mean age of male  $34.4 \pm 8.6$ , mean age of

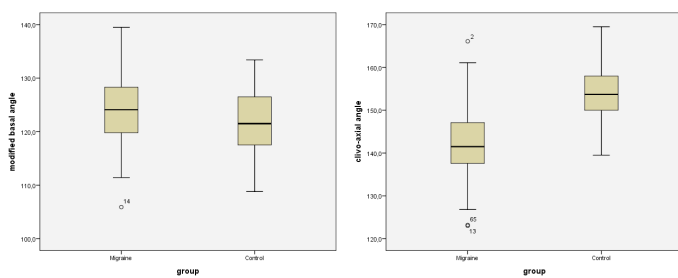
female  $33.14 \pm 9.7$  years). In migraine and control groups MBA and CAA measurement results are shown on Table 1. MBA values were in the normal range in both groups but there was a low increase in angle values in the migraine group compared to the control group. Furthermore, there was a decrease in the CAA values in the migraine group compared to the control group. There was significant difference was found between the groups ( $p < 0.05$ ).

**Table 1.** In migraine and control groups modified basal and clivo-axial angle measurement results

	Migraine group	Control group	P value
	Mean±SD (Range) (°)	Mean±SD (Range) (°)	
Modified basal angle	123.78±6.06 (105.9-139.5)	121.60±5.50 (108.8-133.4)	<0.05
Clivo-axial angle	142.65±8.73 (123-166.1)	153.66±6.35 (139.5-169.5)	<0.05

The results are expressed as mean ± standard deviation (SD) and range

Comparisons of the MBA and the CAA between migraine and control group with Boxplot graphy is shown in fig 4. There was no difference between the genders for both groups. In both groups, superior extension of the odontoid process was evaluated according to McGregor and Chamberlain line. Migraine group; according to McGregor line in 3 patients and McGregor and Chamberlain line in 2 patients, basilar invagination was observed. Basilar invagination was not detected in the control group.



**Figure 4.** Comparisons of the modified basal angle and the clivo-axial angle between groups with Boxplot graphy

## Discussion

Migraine is a chronic, paroxysmal and neurovascular disease that is twice as common in women. This disease starts at any age, the frequency decreases in later ages [1,9]. Craniocervical junction (CCJ), contains a number of anatomical structures, such as foramen magnum, C1, C2 vertebrae, and muscle-connective tissues that provide the connection between the cervical spine and the cranium. Furthermore, it contains important foraminae for vascular and cerebrospinal fluid

between the spinal canal and the cranium [10]. Congenital anomalies (such as Chiari malformation, craniosynostosis, Dandy-Walker malformation), physical deformities due to posture-false movements, neurodegenerative diseases (such as Alzheimer's, Parkinson's, Multiple Sclerosis) may be occur variability in the anatomy of the skull base [8,10-12]. These changes can cause compression in the brain stem, cerebellum, cervical spinal cord, lower cranial and upper cervical nerves [11,12]. In addition, malformations and deformations of CCJ affect craniocervical hydrodynamic changes due to obstruction and stenosis in blood and CSF flow pathways [8,10,11]. Developing hydrodynamic changes have been associated with clinical manifestations such as migraine, ischemia, dizziness, and psychotic disorders also [10-16]. Due to the process, chronic ischemia, edema, atrophy, hydrocephalus can occur [10]. In our study, we determined variability in MBA, CAA from skull base angles that were involved in migraine pathophysiology.

Secondary to the congenital or acquired skull base deformities, MBA, CAA changes and basilar invagination may be occur [3]. MBA; is the angle between the line extending from dorsum sella to nasion and the line drawn along posterior boundary of the clivus, and has been used to evaluate the platibasis [5]. In the literature there are variations between studies and races at normal angle values. In many studies in the literature, the normal range of angle is in the range of  $125^{\circ}$ - $143^{\circ}$  for adults and it is accepted as platybasia over  $143^{\circ}$  [5,17]. Koenigsberg et al. the normal MBA values were found at  $100^{\circ}$ - $127^{\circ}$  in adults [5,17]. In our study, the MBA was  $105^{\circ}$ - $139^{\circ}$  in migraine patients with a mean of  $123.78 \pm 6.06^{\circ}$ . In the control group, it ranged from  $108^{\circ}$  to  $133^{\circ}$ , with a mean of  $121.6 \pm 5.5^{\circ}$ . There was a significant difference between the two groups ( $p < 0.05$ ).

The CAA is important for craniocervical instability [12]. The CAA is the angle between the line extending from dorsum sella to basion and the line drawn along the boundary superoposterior and inferoposterior corners of the C2 vertebrae [18]. The CAA varies from  $150^{\circ}$  in flexion to  $180^{\circ}$  in extension. The CAA has a normal range of  $145^{\circ}$  to  $160^{\circ}$  in the neutral position [12]. Van Gilder reported that the CAA of less than  $150^{\circ}$  was associated with neurological changes [19,20]. Nagashima and Kubota reported that it was important for anterior spinal cord pressure when the CAA is below  $130^{\circ}$  [21]. In our study, the CAA was  $123$ - $166^{\circ}$  in migraine patients with a mean



of  $142.65 \pm 8.73^\circ$ . In the control group, it ranged from  $139^\circ$  to  $169^\circ$ , with a mean of  $153.66 \pm 6.35^\circ$ . There was a significant difference between the two groups ( $p < 0.05$ ).

Basilar invagination is a developmental anomaly of CCJ, in which displaced to the superior direction of the odontoid process [3,22]. The process can lead to compression of the cervicomedullary junction, so may be change in vasculature-CSF flow rate at this level, and muscle spasm [3]. McGregor and Chamberlain line have been used to evaluate basilar invagination. The Chamberlain line extends from the hard palate to the midpoint of the posterior margin of the foramen magnum. The McGregor line extends from the hard palate to the lowest point of the occipital squama. Basilar invagination is considered if the odontoid tip extends more than 5 mm above the Chamberlain line and more than 7 mm above the McGregor line [3,22-24]. In our study, basilar invagination was observed according to the McGregor line in 3 patients and McGregor and Chamberlain line in 2 patients. Basilar invagination was not detected in the control group.

Limitations of the study: first, included all migraine patients in the patient group and no distinction was made between the subgroups. Second, no evaluated comparing white matter findings and skull base angles. Third, the lower number of male genders in migraine and control group is another limitation of study. Comprehensive studies in which involving migraine subgroups, gender balance, comparison of white matter findings and including other aspects of the cranium such as Boogard's angle, cranial lordosis angle and morphometric distance measurements, will contribute.

## Conclusion

Our study observed that are there changes in the angle of the skull base (MBA and CAA) in migraine patients according to magnetic resonance images. We observed significant a decrease in CAA values and a small increase in MBA values in migraine patients according to control group. It is important to may be cause craniospinal hydrodynamic changes. Craniospinal hydrodynamic changes are associated with white matter changes in migraine disease. According to these findings, there is a significant relationship between migraine disease and skull base angle especially reduced CAA angle. This is the first pilot evaluating study skull base angle variabilities

in migraine patients. However, these findings need to be supported by other studies with more comprehensive studies using a larger patient series. In addition, we recommend that evaluation of skull base angles on MRI in terms of craniovertebral instability in migraine patients.

Conflict of interest: The authors declare no conflicts of interest.

## References

1. Yücel Y. Migren baş ağrısında tanı ve tedavi yaklaşımları. Dicle Tıp Dergisi 2008; 35 (4): 281-286.
2. Palm-Meinders IH, Koppen H, Terwindt GM et al. Structural brain changes in migraine. JAMA 2012; 14: 308(18): 1889-1897. Doi: 10.1001/jama.2012.14276.
3. Pinter NK, McVige J, Mechtler L. Basilar invagination, basilar Impression and platybasia: clinical and imaging aspects. Curr Pain Headache Rep 2016; 20(8): 49. Doi: 10.1007/s11916-016-0580-x.
4. Headache classification subcommittee of the International Headache Society. The international classification of headache disorders. Cephalalgia 3rd edition (beta version) 2013; 33(9): 629-808. Doi: 10.1177/0333102413485658
5. Hirunpat S, Wimolsiri N and Sanghan N. Normal value of skull base angle using the modified magnetic resonance imaging technique in Thai population. J Oral Health Craniofac Sci 2017; 2: 017-021.
6. Martin JE, Bookland M, Moote D, Cebulla C. Standardized method for the measurement of Grabb's line and clival-canal angle. J Neurosurg Pediatr 2017; 20(4): 352-356. Doi: 10.3171/2017.5.PEDS17181
7. Xu S, Gong R. Clivodens angle: A new diagnostic method for basilar Invagination at computed tomography. Spine (Phila Pa 1976) 2016; 41(17): 1365-1371.
8. Ferreira JA and Botelho RV. The odontoid process invagination in normal subjects, Chiari malformation and basilar invagination patients: pathophysiologic correlations with angular craniometry. Surg Neurol Int 2015; 6: 118. Doi: 10.4103/2152-7806.160322
9. Ertas M, Baykan B, Orhan EK et al. One-year prevalence and the impact of migraine and tension-type headache in Turkey: a nationwide home-based study in adults. J Headache Pain 2012; 13(2): 147-157. Doi: 10.1007/s10194-011-0414-5
10. Flanagan MF. The Role of the Craniocervical junction in craniospinal hydrodynamics and neurodegenerative conditions. Neurol Res Int 2015; 2015: 794829. Doi: 10.1155/2015/794829

11. Menezes AH. Craniovertebral junction database analysis: incidence, classification, presentation, and treatment algorithms. *Childs Nerv Syst* 2008; 24(10): 1101-1108. Doi: 10.1007/s00381-008-0605-9
12. Henderson FC Sr, Henderson FC Jr, Wilson WA IV, Mark AS, Koby M. Utility of the clivo-axial angle in assessing brainstem deformity: pilot study and literature review. *Neurosurg Rev* 2018; 41(1): 149-163. Doi: 10.1007/s10143-017-0830-3
13. Vieira DS, Masruha MR, Gonçalves AL et al. Idiopathic intracranial hypertension with and without papilloedema in a consecutive series of patients with chronic migraine. *Cephalalgia* 2008; 28(6): 609-613. Doi: 10.1111/j.1468-2982.2008.01564.x.
14. Koerte IK, Schankin CJ, Immler S et al. Altered cerebrovenous drainage in patients with migraine as assessed by phasecontrast magnetic resonance imaging. *Invest Radiol* 2011; 46(7): 434-440. Doi: 10.1097/RLI.0b013e318210ecf5
15. Flanagan MF. Migraines, strokes and chiropractic. *Dynamic chiropractic* 2002; 20(21)
16. Kruit MC, Van Buchem MA, Hofman PA et al. Migraine as a risk factor for subclinical brain lesions. *The Journal of the American Medical Association* 2004; 291(4): 427-434
17. Koenigsberg RA, Vakil N, Hong TA et al. Evaluation of platybasia with MR imaging. *AJNR Am J Neuroradiol* 2005; 26 (1): 89-92
18. Botelho RV, Ferreira ED. Angular craniometry in craniocervical junction malformation. *Neurosurg Rev* 2013; 36(4): 603- 610. Doi: 10.1007/s10143-013-0471-0
19. Pappas CT, Harrington T, Sonntag VK. Outcome analysis in 654 surgically treated lumbar disc herniations. *Neurosurgery* 1992; 30(6): 862-866
20. Reid CS, Pyeritz RE, Kopits SE et al. Cervicomedullary compression in young patients with achondroplasia: value of comprehensive neurologic and respiratory evaluation. *J Pediatr* 1987; 110(4): 522-530
21. Nagashima C, Kubota S. Craniocervical abnormalities. Modern diagnosis and a comprehensive surgical approach. *Neurosurg Rev* 1983; 6(4): 187-197
22. Smith JS, Shaffrey CI, Abel MF, Menezes AH. Basilar invagination. *Neurosurgery* 2010; 66(3): 39-47. Doi: 10.1227/01.NEU.0000365770.10690.6F.
23. Smoker WR. Craniovertebral junction- normal anatomy, craniometry and congenital anomalies. *Radiographics* 1994; 14(2): 255-277.
24. Ross JS. Specialty imaging: craniocervical junction. Lippincott Williams & Wilkins; 2013

Corresponding Author: Neşe Asal, Kırıkkale University, Faculty of Medicine, Department of Radiology, 71450, Yahşihan, Kırıkkale, Turkey

E-mail: nese\_asal@yahoo.com.tr