



Comparison of efficiency of serratus anterior plane block and thoracic epidural block for thoracotomy analgesia

Torakotomi analjezisi için uygulanan serratus anterior alan ve torakal epidural blok etkinliklerinin karşılaştırılması

Korgün Ökmen¹

Abstract

Aim: Currently, regional anesthesia methods are frequently used for post-thoracotomy pain. In this study, we aimed to compare the efficacy of serratus anterior plane block and thoracic epidural block for pain after thoracotomy.

Methods: This retrospective study included 120 patients who underwent thoracotomy. Seventy patients who met the inclusion criteria were evaluated in two groups as Group E (thoracic epidural block) (n=37) and Group S (serratus anterior plane block) (n=33). Postoperative 2nd, 6th, 12th and 24 hour visual analogue scale scores and total analgesic consumption for 24 hours were evaluated. Secondary outcomes were determined as side effects, additional analgesic drug requirement and complications.

Results: In the comparison between the groups, there were no statistically significant differences between two groups in terms of postoperative 2nd (p=0.417), 6th (p=0.271), 12th (p=0.734) and 24th hour (p=0.157) visual analogue scale scores and the amount of total analgesic consumption for 24 hours (p=0.714). There was no statistically significant difference between two groups with regard to the side effects nausea and vomiting (p=0.714), pruritus (p=N/A), respiratory depression (p=N/A) levels.

Conclusion: The results of this study demonstrate that use of serratus anterior plane block and thoracic epidural block administration has similar outcomes for post-thoracotomy analgesia.

Keywords: Thoracotomy, bupivacaine, analgesia, pain management, epidural anesthesia

Öz

Amaç: Post-torakotomi ağrısı için günümüzde rejyonal anestezi yöntemleri sıklıkla kullanılmaktadır. Bu çalışmada torakotomi sonrası ağrı için serratus anterior alan bloğunun (SAPB) ve torakal epidural bloğun etkinliğini karşılaştırmayı amaçladık.

Yöntemler: Bu retrospektif çalışmada torakotomi yapılan 120 hasta çalışmaya alındı. Dahil etme kriterlerini karşılayan 70 hasta Grup E (torasik epidural blok) (n=37) ve Grup S (serratus anterior alan blok) (n=33) olmak üzere iki grupta değerlendirildi. Postoperatif 2., 6., 12. ve 24. saatlerde görsel analog skala skorları ve 24 saatlik toplam analjezik tüketimi değerlendirildi. İkincil sonuçlar yan etkiler, ek analjezik ilaç gereksinimi ve komplikasyon olarak belirlendi.

Bulgular: Gruplar arasında yapılan karşılaştırmalarda ameliyat sonrası 2. saat (p=0.417), 6. saat (p=0.271), 12. saat (p=0.734) ve 24. saat (p=0.157) görsel analog skala skorları ve 24 saatlik toplam analjezik tüketimi miktarları (p=0.714) karşılaştırıldığında, 2 grup arasında istatistiksel olarak anlamlı fark yoktu. İki grup arasında yan etkiler, bulantı ve kusma (p=0.714), kaşıntı (p=N/A), solunum depresyonu (p=N/A) düzeyleri açısından istatistiksel olarak anlamlı fark yoktu.

Sonuç: Bu çalışmanın sonuçları, serratus anterior alan bloğu ve torasik epidural blok uygulamasının torakotomi sonrası analjezi için benzer sonuçlara sahip olduğunu göstermektedir.

Anahtar kelimeler: Torakotomi, bupivakain, analjezi, ağrı yönetimi, epidural anestezi

¹ University of Health Sciences, Bursa Yüksek İhtisas Training and Research Hospital, Department of Anesthesiology and Reanimation, Bursa, Turkey.

Ethics Committee Approval: The study was approved by the local ethical authority.

Etik Kurul Onayı: Çalışma lokal etik komite tarafından onaylanmıştır.

Conflict of Interest: No conflict of interest was declared by the author.

Çıkar Çatışması: Yazar çıkar çatışması bildirmemiştir.

Financial Disclosure: The authors declared that this study has received no financial support.

Finansal Destek: Yazarlar bu çalışma için finansal destek almadıklarını beyan etmişlerdir.

Geliş Tarihi / Received: 21.06.2018

Kabul Tarihi / Accepted: 10.09.2018

Yayın Tarihi / Published: 30.11.2018

Sorumlu yazar / Corresponding author: Korgün Ökmen

Adres/Address: University of Health Sciences, Bursa Yüksek İhtisas Training and Research Hospital, Department of Anesthesiology and Reanimation, Mimar Sinan Quarter, Emniyet Street. 16130 Bursa, Turkey.

e-posta: korgunokmen@gmail.com

Tel/Phone: +90 5057081021

Copyright © ACEM

Introduction

Currently, multimodal approaches are used for post-operative analgesia. Regional anesthesia methods are frequently combined with nonsteroidal anti-inflammatory drugs (NSAID) and opioids as analgesia after major surgery. Pain after thoracotomy can cause ventilation perfusion disorder and hypoxemia together with changes in the lung mechanics [1, 2]. Early causes of the pain were determined as soft tissue damage, incision line, drain entry sites and rib fractures [3]. Multimodal analgesia is required to block sensory signals from all areas due to the large number of pain-producing areas [3]. For thoracic surgery, thoracic epidural block (TEB), paravertebral block and intercostal block are the methods that commonly used [3]. They can be used alone or as a part of a multimodal analgesia. The frequent use of ultrasound (US) in regional anesthesia allows the application of different area blocks. Some of these are the quadratus lumborum block (QLB), pectoral nerves block (PECS), transversus abdominis plane (TAP) block and serratus anterior plane block, which can also be used in surgeries related to abdominal and thoracic wall [4-6].

Serratus anterior plane block (SAPB), which can provide analgesia between the second thoracic vertebra (T2) and the ninth thoracic vertebra (T9) levels, is one of the new plane blocks that can be applied with the coexistence of US that may be a suitable approach for thoracic surgery analgesia [7]. It has been reported that application of local anesthetic drugs to the area between serratus anterior muscle and intercostal muscle can block the cutaneous branches of intercostal muscles in T2-T9 dermatomes [7]. Apart from the thoracic surgery, it has been found that approximately 12 hours of sensory block can be obtained using SAPB which can be used for post-operative analgesia related with the thoracic wall [8].

In this study, we aimed to detect the effects of SAPB and TEB for posterolateral thoracotomy analgesia with regard to the amount of analgesic consumption and visual analogue scale (VAS) scores.

Material and methods

Patients

In this retrospective study, files of the patients who had undergone thoracotomy operation between 2016 and 2018 were reviewed after approval of the local ethics committee (2011-KAEK-25 2018/6-24). The study was performed in accordance with the Declaration of Helsinki. Written consent could not be taken due to the retrospective design of the study.

A total of 120 patients that undergone thoracotomy operation between 18 and 65 years and with American Society of Anesthesiologist (ASA) I-III risk class were included in the study. Exclusion criteria were determined as opioid use before the operation, the second operation history which can change VAS scores, emergency operation and complications which would prolong duration of the surgery and require additional interventions.

27 patients had the lack of the data, ten patients had opioid use before the operation, four patients underwent recurrent surgery, five patients had prolonged surgery due to anatomic difficulties or caused by hemorrhage and four patients were excluded from the study due to emergency surgery.

After exclusion of the patients with these criteria, a total of 70 patients with SAPB (Group S, n= 33) and TEB (Group E, n= 37) were included in the study.

Management of anesthesia

All patients were monitored for non-invasive blood pressure, electrocardiography, heart rate and peripheral oxygen

saturation. For induction, 2-2.5 mg /kg intravenous propofol (Propofol 2% Fresenius®, Fresenius Kabi, Bad Homburg, Germany) and 0.6-0.8 mg/kg IV rocuronium bromide (Curon®, Mustafa Nevzat, Istanbul, Turkey) were used. The patients were intubated with double-lumen tube at the appropriate size (35-37 French) and mechanical ventilation was applied to keep end-tidal carbon dioxide as 30-35 mmHg.

For maintenance of general anesthesia, sevoflurane (Sevorane®Likit %100, AbbVie, Queenborough Kent, England) at a concentration of 2-2.5% was given within oxygen-air mixture at a rate of 3 L/min. Additional analgesic requirement was sustained with 1mcg/kg fentanyl (Talinat®, Vem, Istanbul, Turkey).

Treatment of pain

Group E (TEB)

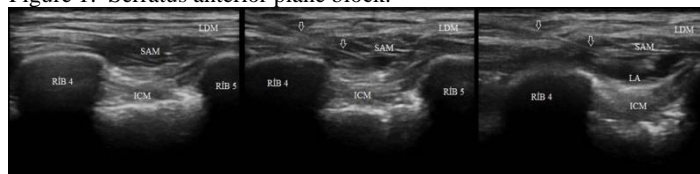The epidural area was reached in the midline in the 6th (T6) and 7th (T7) thoracic vertebrae with an 18 gauge (G) epidural needle (Braun, Melsungen, Germany) by the method of loss of resistance after appropriate site cleaning before the operation. A 20 G epidural catheter was pushed through the needle after placing the tip of the needle in the epidural space. The needle was then pulled over the catheter and the catheter was placed 3 cm in the epidural space.

After 2 ml of 2% lidocaine (Aritmal®, Osel, Istanbul, Turkey) was administered as a test dose, the patient underwent general anesthesia. At the end of the operation, 15 mL of 0.25 % bupivacain (Marcain® %0,5, AstraZeneca PLC, England) bolus dose was applied after the skin incision was closed.

Group S (SAPB)

SAPB was applied in the lateral decubitus position at the end of the operation when skin incision was closed. After appropriate site cleaning, the first and the second ribs were identified at the midclavicular line with the linear ultrasonic probe. 4th and 5th ribs were displayed moving US probe forward in a sagittal plan towards the caudal direction and; then, serratus, latissimus dorsi and intercostal muscles were traced at the midaxillary line moving posteriorly [7]. After the verification of the area that was provided with a 20 G 100 mm US-visible peripheral nerve block needle (Quincke SonoPlex Pajunk, Geisingen, Germany) by hydrodissection with 3 ml to the inferior plane of the serratus muscle using the in-line technique with the aid of US, 20 ml bupivacaine (Marcain® %0,5, AstraZeneca PLC, İngiltere) injection was applied at 0.25% concentration and a 22 G catheter was placed to 3-4 cm under the serratus anterior muscle (Figure 1). All blocks (TEB, SAPB) were performed by a specialist anesthesiologist who was experienced in the same regional anesthesia after surgery.

Figure 1: Serratus anterior plane block.



SAM: The serratus anterior muscle, LDM: The latissimus dorsi muscle, RIB 4: 4th rib, RIB 5: 5th rib, ICM: The intercostalis muscle, LA: local anesthetic, Arrows: Needle

Patient controlled analgesia (PCA)

Both groups through the catheter placed in the epidural space and under the serratus muscle were infused with 100 mg bupivacaine (Marcain® %0,5, AstraZeneca PLC, England), as 1 mg/mL bupivacaine solution in 100 mL normal saline. PCA settings were a 5 ml intermediate bolus dose and one hour locking time. Tenoxicam (Oksamen-L®, Mustafa Nevzat, Istanbul, Turkey) 20 mg was administered as an analgesic drug to all patients before the post-operative extubation. When Visual

Analogue Scale (VAS) > 5, for additional analgesic requirement was ordered to be given.

As primary measures, VAS scores (2nd, 6th, 12th and 24th hours after operation) and total analgesic consumption for 24 hours were analyzed. Secondary measures were side effects (nausea and vomiting, pruritus, respiratory depression, bradycardia, hypotension), additional analgesic requirement (Tramadol, Paracetamol, Pethidine HCl), intraoperative opioid requirement. The patients whose mean arterial pressures were below 60 mmHg postoperatively were considered as hypotensive and recorded. Bradycardia was accepted as heart beats below 50 beats/min and respiratory depression has been identified as the mask was considered to be O₂ (4lt/min) and SpO₂ below 95.

Statistical analysis

Analysis of the data was done using the IBM SPSS 22.0 statistical package program. The descriptive statistics were given as mean± standard deviation, with median (minimum and maximum) for quantitative variables, and as percentages for categorical variables.

In the evaluation of the study data, chi-square (χ^2) test was used for comparison of qualitative data as well as descriptive statistical methods. The normal distribution of the data was evaluated by the Shapiro-Wilk test. Mann-Whitney U test was used in the comparison between the groups. Probability values smaller than (P) $\alpha = 0.05$ were accepted as significant.

Results

In the study population, 57 were males and 13 were females. The mean age was 53.35 ± 7.19 years. The mean body mass index (BMI) was 23.28 ± 1.84 kg/m². Surgical side was the right and the left in 38 and 32 patients, respectively. The mean duration of the surgery was 134.2±26.8 min.

Postoperative 2nd, 6th, 12th, 24th hour visual analogue scale scores were measured as 3.2±0.71, 2.8±0.87, 1.80±0.86 and 1.94±0.83 in Group S, respectively. These scores were measured as 3.05±0.68, 2.65±0.63, 1.88±0.93 and 1.65±0.63 in Group E, respectively.

Between the groups; there was no statistically significant difference in terms of gender, age, BMI, surgical side and duration of the operation (p>0.05 for all) (Table 1). In VAS scores and the amounts of post-operative analgesic consumption including tramadol (p=0.572), NSAID (p=0.079) and opioid drugs (p=0.558), no statistically significant difference was found between the groups (Table 2, 3). When the total local anesthetic consumption with PCA during the postoperative 24 hours were examined, it was 23.28±5.8 mg 27±11.6 mg in Group S and Group E, respectively. There was no significant difference between the groups (p=0.714) (Figure 2). There was also no statistically significant difference between the groups in terms of

BMI: body mass index, M: male, F: female, † mean ±SD, &: median (min-max) value

Figure 2: Total amount local anesthetics during 24 hours.

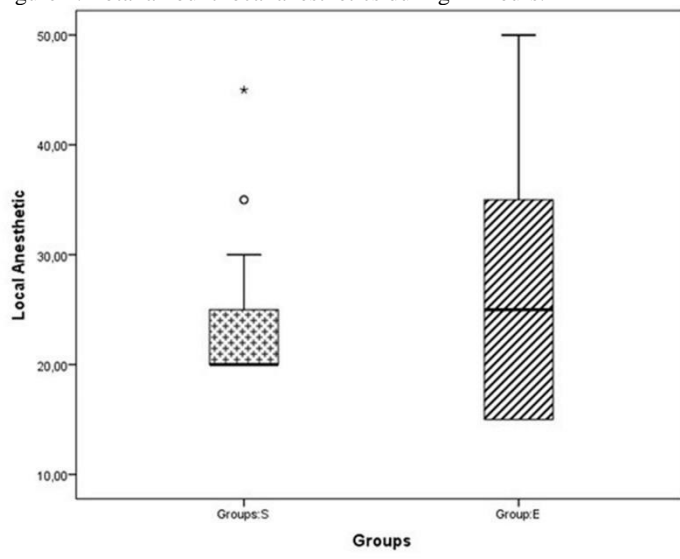


Table 2: Comparison of VAS scores at rest between groups

VAS	Group S (n=33)	Group E (n=37)	p
2 nd hour †	3.2±0.71	3.05±0.68	0.417
6 th hour †	2.8±0.87	2.65±0.63	0.271
12 th hour †	1.80±0.86	1.88±0.93	0.734
24 th hour †	1.94±0.83	1.65±0.63	0.157

VAS: Visual Analogue Scale, †: mean ±SD

Table 3: Side effects and additional analgesic requirement.

Variable		Group S (n=33)	Group E (n=37)	p
Side effects	Nausea and vomiting [†]	-	1(3.4%)	0.309
	Pruritus	-	-	N/A
	Respiratory depression	-	-	N/A
	Bradycardia	-	-	N/A
	Hypotension	-	-	N/A
Analgesic requirement	Tramadol (mg) †	75±52.1	82.8±44	0.572
	Paracetamol (gr) [†]	1 (2.9%)	3 (8.6%)	0.079
	Pethidine HCl (mg) [†]	50 (2.9%)	100 (5.7%)	0.558

[†]: frequency (%), †: mean ±SD

	Group S (n=33)	Group E (n=37)	p
Age (year) †	54±7.4	52.6±6.9	0.429
BMI (kg/m ²) †	23.2±1.8	23.3±1.84	0.986
Gender & (M/F)	28/5	29/8	0.490
Amount of opioid given during operation (µg) †	124.12 (80-200)	114 (80-180)	0.289
Surgical side (right/left)	17/16	21/16	0.663
Duration of the surgery (min) †	137.2±24.8	133.3±23	0.358

the type of the side effects (p> 0.05 for all) (Table3).

Table 1. Comparison of the demographic characteristics of the patients.

Discussion

We retrospectively reviewed the patients who underwent SAPB and TEB in order to provide analgesia after thoracotomy operation. There was no statistically significant difference between two groups considering the amount of analgesic consumption and VAS scores.

Recently, pain after many surgical procedures has been treated with multimodal analgesia approach. These methods combine intravenous drug administration with regional anesthesia procedures. These methods reduce the side effects of opioids in analgesic doses and improve patient comfort [9]. Multimodal approaches for thoracic surgery can be applied in combination with intravenous opioid, NSAIDs and regional methods such as paravertebral block and thoracic epidural block.

Although thoracic epidural block is accepted as the gold standard treatment for thoracic surgery, side effects such as neuroaxial hematoma, urinary retention and hypotension are the faced difficulties [10, 11]. The complications such as total spinal block and neural damage observed following paravertebral block application which can be used as an alternative have been mentioned in the literature as limitations of this method [12].

Current regional anesthesia methods have focused on fascial blocks with the widespread use of US. Effectiveness of SAPB, which is used more frequently for thoracic anatomy, have been tried to be determined with case studies and research articles in the literature. Breast surgery, thoracotomy and video assisted thoracoscopic surgery operations are some of the studies using SAPB [9, 13-15]. Although the level of analgesia is indicated as level of T2-T9 by Blanco et al. [7], there are also publications in which the sensory block level is stated to be formed in a narrower area of T2-T6 to T3-T8 [8,15-20]. In a randomized controlled study of SAPB for postoperative pain after radical mastectomy, when compared with the other group in which the paravertebral block was administered, although they have reached low values of VAS and morphine consumption in the SAPB group, they reported that the effect was limited [8]. In another study investigating SAPB efficacy, Ökmen et al. [21] used patients who underwent VATS. In this study using bupivacaine in 20 mL of 0.25 % concentration, they found a lower amount of tramadol consumption postoperatively and found that this block was effective after VATS [14]. In one randomized controlled study by Khalil et al. [11], SAPB and TEB applications were compared in two groups with 20 patients. They reached similar VAS scores and opioid consumption values after local anesthetic infusion via catheter after single-dose medication. They shared that SAPB block application maintains better hemodynamic stability [11]. Another study retrospectively tried to determine efficacy of SAPB administration and reported that it was an alternative method for thoracotomy analgesia [15].

The presence of few studies of post-thoracotomy pain limits the discussion of efficacy and complications. There are different uses of amounts of local anesthetics for SAPB in the literature [11, 15, 16, 20, 21]. Although 20 mL of local anesthetic in our study showed sufficient analgesia for 24-hour follow-up for thoracotomy analgesia, Khalil et al. [11] used higher doses of local anesthetics (30 ml bolus and 5 ml/h infusion) for similar analgesia level in their study. Although the dosage of local anesthetic for optimal analgesia can be determined in future studies, as in other plane blocks, the use of high amounts of local anesthetics seems to be remarkable. On the other hand, we think that the use of greater amounts of local anesthetics in the epidural block group may be important even though there is no statistically significant difference between groups in terms of the 24 hours total local anesthetic amounts. With these results, single-dose SAPB administration appears to be an adequate supportive treatment option for post-thoracotomy pain.

Retrospective design and absence of follow up after sensory block were the limitations of this study.

In conclusion, the results of this study suggest that SAPB provides analgesia at a level similar to that of TEB and is effective as a supportive treatment option. The higher local anesthetic dose with in single shot SAPB administration can be seen as a disadvantage of the block.

References

- Kavanagh BP, Katz J, Sandler AN. Pain control after thoracic surgery. A review of current techniques. *Anesthesiology*.1994;81:737-59.
- Doan LV, Augustus J, Androphy R, Schechter D, Gharibo C. Mitigating the impact of acute and chronic post-thoracotomy pain. Review articles. *J Cardiothorac Vasc Anesth*. 2014;28:1048-56.
- Slinger PD, Campos JH. Anesthesia for thoracic surgery. In: Miller RD, editor. *Miller's anesthesia*. 8th ed. Philadelphia: Elsevier Saunders; 2015. p. 1942-2006.
- Blanco R, Ansari T, Girgis E. Quadratus lumborum block for postoperative pain after caesarean section: a randomised controlled trial. *Eur J Anaesthesiol*. 2015;32:812-18.
- Blanco R. The 'Pecs block': a novel technique for providing analgesia after breast surgery. *Anaesthesia*. 2011;66:847-8.
- Hebbard P, Fujiwara Y, Shibata Y, Roysse C. Ultra-sound-guided transversus abdominis plane (TAP) block. *Anaesth Intensive Care*. 2007;35:616-7.
- Blanco R, Parras T, McDonnell JG, Prats- Galino A. Serratus plane block: a novel ultrasound-guided thoracic wall nerve block. *Anaesthesia*. 2013;68:1107-13.
- Hetta DF, Rezk KM. Pectoralis serratus interfascial plane block vs thoracic paravertebral block for unilateral radical mastectomy with axillary evacuation. *J Clin Anesth*. 2016;34:91-7
- [Demirhan A, Gül R, Ganidağlı S, Koruk S, Mızrak A, Şanlı M, et al. Combination of Dexmedetomidine and Tramadol in the Treatment of Pain After Thoracotomy]. *GKDA Derg*. 2011;17:34-41.
- Gulbahar G, Kocer B, Muratli SN, Yildirim E, Gulbahar O, Dural K, et al. comparison of epidural and paravertebral catheterisation techniques in post-thoracotomy pain management. *Eur J Cardiothorac Surg*. 2010;37:467-72.
- Khalil AE, Abdallah NM, Bashandy GM, Kaddah TAH. Ultrasound-guided serratus anterior plane block versus thoracic epidural analgesia for thoracotomy pain. *J Cardiothorac Vasc Anesth*. 2017;31: 152-58.
- Lönqvist PA, McKenzie J, Soni AK, Conacher AD. Paravertebral blockade: Failure rate and complications. *Anesthesia*. 1995;50:813-5.
- Hards M, Harada A, Neville I, Harwell S, Babar M, Ravalía A, et al. The effect of serratus plane block performed under direct vision on postoperative pain in breast surgery. *J Clin Anesth*. 2016;34:427-31.
- Ökmen K, Ökmen BM. The efficacy of serratus anterior plane block in analgesia for thoracotomy: a retrospective study. *J Anesth*.2017;31: 579-85.
- Bhoi D, Pushparajan HK, Talawar P, Kumar A, Baidya DK. Serratus anterior plane block for breast surgery in a morbidly obese patient. *J Clin Anesth*. 2016;33:500-1.
- Ohgoshi Y, Yokozuka M, Terajima K. Serratus-Intercostal Plane Block for Brest Surgery. *Masui*. 2015;64:610-4
- Daga V, Narayanan MK, Dedhia JD, Gaur P, Crick H, Gaur A. Cadaveric feasibility study on the use of ultrasound contrast to assess spread of injectate in the serratus anterior muscle plane. *Saudi J Anaesth*. 2016;10:198-201.
- Diéguez P, Fajardo M, López S, Alfaro P. BRILMA methylene blue in cadavers. Anatomical dissection. *Rev Esp Anesthesiol Reanim*. 2016;63:307-8.
- López-Matamala B, Fajardo M, Estébanez-Montiel B, Blancas R, Alfaro P, Chana M. A new thoracic interfascial plane block as anesthesia for difficult weaning due to ribcage pain in critically ill patients. *Med Intensiva*. 2014;38:463-5.
- Kunhabdulla NP, Agarwal A, Gaur A, Gautam SK, Gupta R, Agarwal A. Serratus anterior plane block for multiple rib fractures. *Pain Physician*. 2014;17:651-3.
- Ökmen K, Ökmen BM. Evaluation of the effect of serratus anterior plane block for pain treatment after video-assisted thoracoscopic surgery. *Anaesth Crit Care Pain Med*. 2018;37:349-53.