



# Successful Percutaneous Intervention for Ostial Stenosis of Left Internal Mammary Arterial Graft

Efe Edem, Saadet Demirtaş, Sabiye Yılmaz, Yusuf Can, Harun Kılıç, Ramazan Akdemir, Hüseyin Gündüz

Sakarya University Faculty of Medicine, Department of Cardiology, Sakarya, Turkey

## ABSTRACT

Left internal mammary artery (LIMA) graft is the commonly preferred graft for bypass surgery and is particularly anastomosed to the left anterior descending artery. Stenosis of this graft frequently develops in the distal anastomosis site or within the distal native vessel after surgery, whereas it rarely develops in the ostial site. The pathophysiology of stenosis in the ostial site remains unclear. Percutaneous stenting of ostial lesions has rarely been reported in literature. We believe that such percutaneous transluminal stenting is appropriate for ostial lesions of LIMA grafts.

**Key Words:** Percutaneous transluminal angioplasty; coronary artery bypass; stent

## Sol İnternal Mammarian Arter Ostial Darlığına Başarılı Perkütan Girişim

### ÖZET

Sol internal mammarian arter (LİMA) baypas cerrahisinde genelde tercih edilen grefttir ve özellikle sol ön inen artere anastomoz edilir. Bu greftin operasyon sonrası daralması genelde distal anastomoz bölgesinde veya distal nativ damarda meydana gelir. LİMA greftinde nadiren ostial bölgede daralma gelişir ve bu durumun patofizyolojisi halen net değildir. LİMA ostial lezyonunun perkütan stentleme ile tedavisi literatürde nadir olarak bildirilmiştir. Belirttiğimiz yöntemle LİMA greftinin ostial darlığının stent ile tedavisinin bu durum için en uygun tedavi yöntemi olduğunu düşünmekteyiz.

**Anahtar Kelimeler:** Perkütan transluminal anjiyoplasti; koroner arter baypas; stent

## INTRODUCTION

LIMA is the preferred graft for bypass surgery and is generally anastomosed to the left anterior descending (LAD) artery. LIMA grafts usually have long-term patency<sup>(1)</sup>. Stenosis of this graft frequently develops in the distal anastomosis site or within the distal native vessel<sup>(2,3)</sup>. Ostial stenosis of LIMA grafts is extremely rare. Percutaneous stenting of ostial lesions of the LIMA has rarely been reported<sup>(4,5)</sup>.

## CASE REPORT

An 80-year-old female was admitted to our clinic after she was diagnosed with non-ST elevation myocardial infarction. She had a history of coronary artery graft bypass surgery 13 years previously. Two saphenous vein grafts (SVGs) were anastomosed to the left circumflex artery (LCX) and right coronary artery (RCA), and LIMA graft was anastomosed to LAD artery. On admission, her blood pressure was 130/85 mmHg and pulse rate was 100/min. Electrocardiogram showed atrial fibrillation, ST depression, and T-wave inversions in precordial (V4–V6) and extremity derivations (DI-aVL, D III, and VF). There was a mild increase in cardiac enzyme levels. Transthoracic echocardiography revealed that ejection fraction was 35%, and anterior wall and mid and apical septal segments were akinetic. On the following day, coronary angiography was performed, which revealed severe stenosis in the distal left coronary artery, ostial intermediate (IM) artery, and ostial LCX and total occlusion of ostial LAD. There was also severe stenosis in the ostial RCA. Sinus branch was well developed; severe stenosis of sinus branch was also observed. LCX and RCA-SVG anastomosis was present. Critical stenosis in the ostium of LIMA graft was revealed. We performed percutaneous coronary intervention to reveal lesions in the ostial stenosis of LIMA graft and IM artery.

## Correspondence

Efe Edem

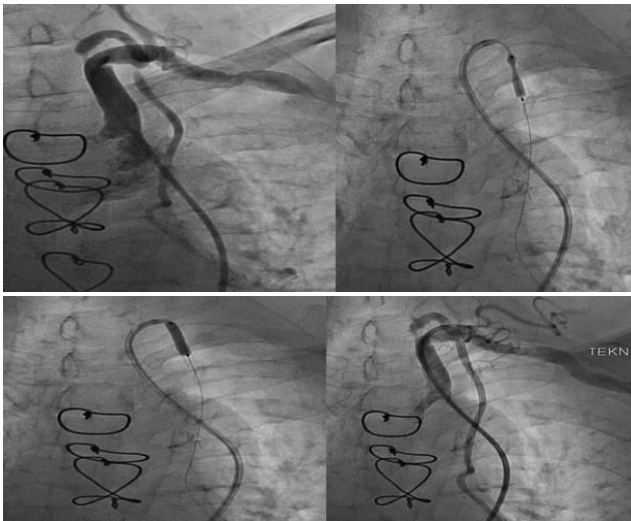
E-mail: edemefe@yahoo.com

Submitted: 19.05.2015

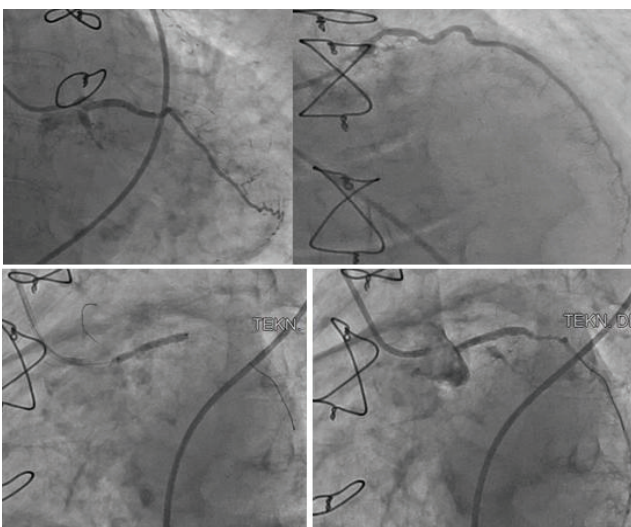
Accepted: 25.06.2015

© Copyright 2017 by Koşuyolu Heart Journal.  
Available on-line at  
www.kosuyoluheartjournal.com

Our approach was through the right femoral artery. A 6F Judkins right coronary guiding catheter was advanced to the aortic arch into the left subclavian artery. A 0.014-inch Soft J guidewire was placed in the LIMA. A distal protection device was not required because of the absence of thrombotic material at the site of lesion. We implanted a  $3.0 \times 15$  mm zotarolimus-eluting coronary stent into the ostium of the LIMA at 16 atm (Figure 1). The final injection of LIMA showed TIMI grade III blood flow. Following the successful intervention of the LIMA, a 6F Judkins left coronary guiding catheter was advanced into the left coronary artery. A 0.014-inch Soft J guidewire was placed into the IM artery. Angioplasty of the distal left coronary and ostial IM arteries were performed with a  $2.0 \times 20$  mm Hopor balloon at 14 atm, following which a sirolimus-eluting coronary stent at 16 atm was implanted, which had a size of  $2.5 \times 22$  mm to cover both the distal left coronary and ostial IM arteries (Figure 2). The final injection of left coronary system showed TIMI grade III blood flow.



**Figure 1.** Successful intervention of left internal mammary artery.



**Figure 2.** Successful interventions of distal left coronary artery and ostial intermediate artery.

## DISCUSSION

LIMA grafts have high patency rates<sup>(6)</sup>. Most stenoses of LIMA grafts are located at the distal anastomosis site or within the distal native vessel. Ostial stenosis of LIMA grafts is very rare and its pathophysiology remains unclear<sup>(3-5)</sup>. Different mechanisms have been suggested such as atherosclerosis subsequent to severe subclavian artery disease, trauma of the ostium due to prior angiography, and damage of the ostium during bypass surgery<sup>(7,8)</sup>.

Different treatment strategies can be used for the treatment of stenosis in bypass grafts, including percutaneous balloon angioplasty, percutaneous stenting, and redo-bypass surgery. Angiographic evidence of recoil following balloon angioplasty was demonstrated in LIMA grafts. A histologic study showed that the vessel wall of IM artery has an elastic component<sup>(9)</sup>. Therefore, balloon angioplasty alone may not be sufficient for the long-term patency of the vessel. Redo-bypass surgery clearly has high mortality and morbidity rates<sup>(10,11)</sup>. However, the percutaneous stenting of ostial stenosis of LIMA grafts has rarely been reported.

Femoral artery is the traditionally preferred vascular access for percutaneous coronary interventions because it provides successful cannulations of coronary arteries and LIMA<sup>(12)</sup>. Therefore, we preferred the femoral approach for LIMA intervention and for the subsequent coronary intervention. Angioplasty and stenting of the distal anastomotic lesions provide adequate results in LIMA grafts; however, data regarding angioplasty and stenting of the ostial lesions in LIMA grafts are insufficient<sup>(13-15)</sup>. In addition, published data on the use of drug-eluting stents in the ostial lesions of the LIMA are also insufficient. Only one report has been published in which a drug eluting stent has been implanted in the ostial lesion of LIMA<sup>(16)</sup>. In our case, drug eluting stent was successfully implanted in the ostial part of LIMA graft. Our patient was discharged 24 h after stent implantation and is currently under follow-up in our outpatient clinic.

We suggest that the percutaneous drug-eluting stent treatment of LIMA grafts using the femoral approach is the most appropriate treatment strategy for revascularization of severe ostial lesions of LIMA grafts.

## REFERENCES

1. Barner HB, Standeven JW, Reese J. Twelve-year experience with internal mammary artery for coronary artery bypass. *J Thorac Cardiovasc Surg* 1985;90:668-75.
2. Hearne SE, Davidson CJ, Zidar JP, Phillips HR, Stack RS, Sketch MH Jr. Internal mammary artery graft angioplasty: acute and long-term outcome. *Cathet Cardiovasc Diagn* 1998;44:153-6.
3. Tantibhedhyangkul W, Warren KL. An unusual case of left internal mammary artery ostial disease: clarifying role of intravascular ultrasound. *Cathet Cardiovasc Intervent* 2002;55:369-72.
4. Stullman WS, Hilliard GK. Unrecognized internal mammary artery stenosis treated by percutaneous angioplasty after coronary bypass surgery. *Am Heart J* 1987;113:393-5.
5. Almagor Y, Thomas J, Colombo A. Balloon expandable stent implantation of a stenosis at the origin of a left internal mammary artery graft: a case report. *Cathet Cardiovasc Diagn* 1991;24:256-8.

6. Tatoulis J, Buxton BF, Fuller JA. Patencies of 2127 arterial to coronary conduits over 15 years. *Ann Thorac Surg* 2004;77:93-101.
7. Sons HJ, Godehardt E, Kunert J, Lösse B, Bircks W. Internal thoracic artery: prevalence of atherosclerotic changes. *J Thorac Cardiovasc Surg* 1993;106:1192-5.
8. Wilde P, Brian AJ. Angioplasty of arterial conduits. Arterial conduits in myocardial revascularization. London: Arnold, 1996;163-9.
9. Van Son JAM, Smedts F, de Wilde PCM, Pijls NHJ, Wong-Alcala L, Kubat K, et al. Histological study of the internal mammary artery with emphasis on its suitability as a coronary artery bypass graft. *Ann Thorac Surg* 1993;55:106-13.
10. Weintraub WS, Jones EL, Craver JM, Grosswald R, Guyton RA. In-hospital and long-term outcome after reoperative coronary artery bypass graft surgery. *Circulation* 1995;92( Suppl 9):II50-7.
11. Lytle BW, Loop FD, Cosgrove DM, Taylor PC, Goormastic M, Peper W, et al. Fifteen hundred coronary reoperations. Results and determinants of early and late survival. *J Thorac Cardiovasc Surg* 1987;93:847-59.
12. Bell MR, Holmes DR Jr, Vlietstra RE, Bresnahan DR. Percutaneous transluminal angioplasty of left internal mammary artery grafts: two years' experience with a femoral approach. *Br Heart J* 1989; 61:417-20.
13. Bedogni F, La Vecchia L. Elective stenting of a de novo ostial lesion of the right internal mammary artery. *Cathet Cardiovasc Diagn* 1998;44:325-7.
14. Morrison DA, Thai H, Goldman S, Felix E, Hernandez J. Percutaneous coronary intervention of or through saphenous vein grafts or internal mammary arteries: the impact of stents, adjunctive pharmacology, and multicomponent distal protection. *Catheter Cardiovasc Interv* 2006;67:571-9.
15. Zampieri P, Colombo A, Almagor Y, Maiello L, Finci L. Results of coronary stenting of ostial lesions. *Am J Cardiol* 1994;73:901-3.
16. Puri R, Dundon BK, Worthley MI, Worthley SG, Brown MA. Drug-eluting stent treatment of a radiation-induced left internal mammary arterial graft stenosis. *Circ J* 2008;72:1904-6.