


History of A Patient with Positive Ear Pressure Tympanometry

Pozitif Basınç Timpanometri

Abdullah Kınar 

¹Uşak University School of Medicine, Department of Ear Nose and Throat Head and Neck Diseases, Usak, Türkiye

Correspondence / Sorumlu yazar:

Abdullah KINAR

Uşak University School of Medicine,
Department of Ear Nose and Throat Head and
Neck Diseases, Usak, Türkiye

e-mail: abduhahkinar@gmail.com

Received : 30.10.2025

Accepted : 16.01.2026

Abstract: We presented a rare case of positive middle ear pressure in tympanometry. 27 years old male patient complained about his bilateral ears fullness for 3 months. He said that it had increased after a travel by plane abroad. On physical examination he had bilateral normal ear findings. He had a septal deviation with acute rhino sinusitis . His nasopharynx was natural. His pure tone audiometry and speech audiometry resulted minimal conductive type hearing loss. Tympanometry test results were right ear peak was measured as +124 daPa and 1.82 ml Left ear peak was +110 daPa and 1.75 ml peak was measured. He received medical treatment.Chronic Positive middle ear pressure in tympanometry test result is very rare. Bulging of ears typically starts at + 125 daPa. Patient medical history usually as similar as Eustachian tube dysfunction. However, Continuous Positive Airway Pressure (CPAP) therapy, used in the treatment of Obstructive Sleep Apnea Syndrome (OSAS), should be kept in mind.

Keywords: Middle Ear; Audiometry; Tympanometry; Positive Pressure; CPAP

Özet: Bu vakada timpanometride orta kulakta basınç pozitifliği olan nadir bir olguyu sunduk. 27 yaşında erkek hasta 3 aydır iki taraflı kulaklarında dolgunluktan şikayetçiydi. Yurt dışına uçakla seyahat ettikten sonra dolgunluğun arttığını söyledi. Fizik muayenesinde iki taraflı normal kulak ve kulak zarı bulguları vardı. Akut rinosinüzit ile birlikte septum deviasyonu vardı. Nazofarenksi doğaldı. Saf ses odyometrisi ve konuşma odyometrisi minimal iletim tipi işitme kaybı gösterdi. Timpanometri test sonuçları sağ kulak tepe noktası +124 daPa ve 1,82 ml olarak ölçüldü. Sol kulak tepe noktası +110 daPa ve 1,75 ml olarak ölçüldü. Hastaya medikal tedavi verildi.Timpanometride orta kulakta basınç pozitifliği çok nadirdir. Kulak zarlarının bombeleşmesi genellikle +125 daPa'da başlar. Hastanın tıbbi geçmişi genellikle östaki disfonksiyonuna benzerdir fakat Obstruktif Uyku Apne Sendromu (OSAS) tedavisinde için kullanılan Continuous Positive Airway Pressure (CPAP) tedavisi akılda olmalıdır.

Anahtar Kelimeler: Orta Kulak; Odyometri; Timpanometri; Pozitif Basınç; CPAP

Informed Consent: Written informed consent was obtained from the patient who agreed to take part in the study.

Author Contributions: Concept – A.K.; Design – A.K.; Supervision – A.K.; Resources – A.K.; Materials – A.K. Data Collection and/or Processing – A.K.; Analysis and/or Interpretation – A.K.; Literature Search – A.K.; Writing – A.K.; Critical Review –A.K.

Copyright Transfer Form: Copyright Transfer Form was signed by all authors.

Conflict of Interest Disclosure: There is no conflict of interest among the authors.

Sources of Funding: There is no funding/sponsorship for this study.

Financial Disclosure: The authors declared that this study received no financial support

1. Introduction

The pathologies of middle ear are classically evaluated by otoscopic examination and audiometric examinations. Tympanometry is the acoustic evaluation of the condition of the middle eardrum and conduction bones by creating air pressure changes in the ear canal. Tympanometry is an objective test of middle ear function.

In tympanometry test, when the external ear canal pressure is equal to the middle ear pressure, impedance is lowest and compliance is highest.

Classically there are three types of tympanometries according to Jerger's classification (1).

Type A: It is the type of tympanogram that peaks in the pressure range of +50 to -100 daPa and has a static immittance between 0.3 and 1.6 ml.

Type B: It is the type of tympanogram in which the static immittance is below 0.25 ml and does not give a distinct peak.

Type C: It is the type of tympanogram that gives its peak at a pressure area more negative than -100 daPa and does not show a significant decrease in the static immittance value.

In tympanometry, positive pressure is referred as greater than $>+50$ mm H₂O (49.03 decapascal daPa) pressure.

Acute otitis occurs when the Eustachian tube becomes blocked, causing air and nitrogen to move away from the middle ear, creating a negative pressure. This causes organisms to be transported from the pharynx and secretions to accumulate and form an effusion. A type-C tympanogram is predicted before otitis media and then with the existence of fluid, the middle ear volume is reduced, and the height and shape of the tympanogram are changes, at last flat.

2. Case Report

A 27-year-old young patient applied to the ENT outpatient clinic with the complaint of fullness in both ears. He had complaints for about 2-3 months. He traveled abroad by plane and his complaints increased. He had not any operation before. Family history was none specific. He was using Continuous Positive Airway Pressure (CPAP) during sleep for Obstructive Sleep Apnea Syndrome (OSAS) treatment. On physical examination his nose acute sinusitis was present. Septum was deviated to the left. Nasopharynx was natural. Ears: Both tympanic membranes appeared natural. In audiometry tests patient had bilateral mild conductive hearing loss in pure tone audiometry, The tympanometry test is done by Interacoustics Basic AT235 Tympanometry at 226 Hz and the right ear peak was measured as +124 daPa (126 mmH₂O) and 1.82 ml Left ear peak was +110 daPa (112 mmH₂O) and 1.75 ml peak was measured in the tympanometry test . The patient received medical treatment.

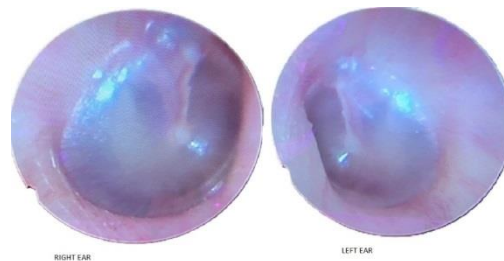

Figure 1. Otoscopic view of ears

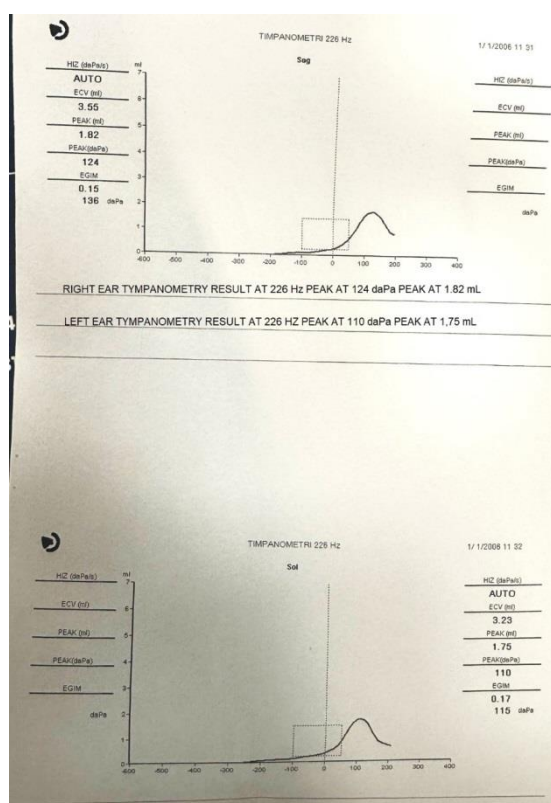


Figure 2. Tympanometry results of ears. Right ear result at 226 Hz Peak at 124 daPa peak at 1.82 ml Left ear result at 226 Hz Peak at 110 daPa peak at 1.75 ml

This patient is treated for acute sinusitis. He received amoxicillin+clavulanic acid combination 1 gr twice a day for 7 days per oral and nasal decongestant oxymetazoline for 5 days to both nostrils. Patient complaint was healed. He had been given information about myringotomy and ventilation tube insertion if complaints reoccur.

Written informed consent was obtained from the patient who agreed to take part in the study.

3. Discussion

Positive middle ear pressure was detected in 13 cases of the 1500 ears identified by Ostergard CA et al. (2) in myringotomy patients (2). 13 cases have positive middle ear pressure ($> +50$ mm H₂O), 3 patients have in bilateral ears and 10 patients have in one of ears and total 16 ears reported positive pressure. Red tympanum reported in 13 ears, other 3 were normal. Bulging of tympanum reported in 5 ears. Effusion have found in 5 of

16 ears at surgery. Patients have symptoms like otalgia tinnitus and sore throat (2).

Ostergard et al. (2) report various factors can cause positive pressure in the middle ear, and the possibility of acute otitis media should be considered. Reduced compliance in conjunction with positive pressure was highly predictive of effusion. However, it is rarely seen positive pressure and normal compliance as in our case report.

Bulging of tympanum was also seen in our case. Bulging of tympanum reported in peak pressures were +50,+65,+80,+150,+250 mm H₂O Ostergard et al. (2). Our patient has 112 mmH₂O and 126 mmH₂O positive ear pressure and there is not any red tympanum clinically.

Yazeed et al. (3) and Riedel CL et al. (4) found that Valsalva maneuver had a significant effect on middle ear positive pressure in normal tympanic membrane and retracted tympanic membrane. They found minimal pressure increase with doing

Valsalva maneuver but did not longer after 10 minutes. Our patients repeated tympanometry results were similar positive middle ear pressure.

Fountes Lima A et al. (5) conclude that severe nasal septum deviations alone can cause Eustachian tube (ET) dysfunction, and septoplasty may improve ET function in these patients (5). Rathod et al. (6) reported abnormal tympanometry results in 66% of patients with septal deviation, compared to 23% in those without septal deviation, and this difference were statistically significant indicating a strong association between nasal septal deviation and middle ear pressure dysfunction(6). Our patient was had a nasal septal deviation to left side and acute bacterial rhinosinusitis that could trigger eustachian tube dysfunction and altered middle ear pressure.

Lin et al. (7) report on obstructive sleep apnea syndrome (OSAS) patients that using Continuous Positive Airway Pressure (CPAP), stated that in normal individuals, middle ear pressure very rarely exceeds +40 daPa. When the CPAP setting was at its lowest level, 5 cm H₂O, the average middle ear pressure increased to an average of +46 daPa. They reported that as CPAP pressure values increased, middle ear pressure may increased to 8-13 times the suprphysiological normal values. Furthermore, they reported that middle ear pressure increased correlated with increasing CPAP settings. They also reported

that middle ear pressures increased to suprphysiological values even at the lowest CPAP setting. They also recommend the use of CPAP to achieve better results after otological surgeries in obstructive sleep apnea patients (7).

Grebenar Cerkez et al. (8) performed tympanometric examinations on OSAS patients before and after CPAP treatment. According to their findings, CPAP treatment increased middle ear pressure (MEP) from -146 daPa to -103 daPa, a statistically significant increase (8). Our patient was using CPAP so that may have increased middle ear pressure.

This case report has some limitations. The patient's repeated tympanometry results were similar. However, no tympanometry results are available after treatment, which is a significant limitation. The CPAP titer used by the patient is unknown.

4. Conclusion

Positive type tympanometry result is rarely observed, Its causes are similar to negative tip C tympanometry but in the cases of positive pressure tympanometry results, it should be kept in mind whether the patient is receiving CPAP therapy. Our patient was had septal deviation and sinusitis, history of travelling by plane and CPAP treatment for OSAS. Valsalva maneuver could cause positive type tympanometry result but it does not last for 10 minutes

REFERENCES

1. Jerger J. Clinical Experience With Impedance Audiometry Arch Otolaryngol. 1970; 92(4): 311–324
2. Ostergard CA, Carter DR. Positive Middle Ear Pressure Shown by Tympanometry Arch Otolaryngol. 1981;107(6):353–356.
3. Yazeed Alshawi, Abdulmalik Ismail, Nora Almegil, Zaid almubarak. The Effect of Valsalva and Toynbee Maneuvers on Tympanometry Parameters in Normal and Retracted Tympanic Membrane. Glob J Oto, 2018; 14(4): 555896.
4. Riedel CL, Wiley TL, Block MG. Tympanometric measures of eustachian tube function. J Speech Hear Res. 1987 Jun;30(2):207-14.
5. Fontes Lima, A., Carvalho Moreira, F., Esteves Costa, I., Azevedo, C., Mar, F., & Dias, L. (2022). Nasal septum deviation and Eustachian tube function: A prospective case-control study based on tympanometry, tubomanometry, and ETDQ-7. Acta Otorrinolaringologica Espanola, 73(1), 35–41.
6. Rathod, K. K., Jayeshbhai Khiloshiya, M., Patel, M. D., & Patel Associate Professor, M. D. (2025).

- Correlation between Nasal Septal Deviation and Middle Ear Dysfunction: A Prospective Study. *International Journal of Life Sciences*, 14(6).
7. Lin FY, Gurgel RK, Popelka GR, Capasso R. The effect of continuous positive airway pressure on middle ear pressure. *Laryngoscope*. 2012 Mar;122(3):688-90.
 8. Grebenar Čerkez, M., Zubčić, Ž., Jurić, S., Šarić Jurić, J., Kovačević, J., Dukić, D., Birtić, D., Čerkez, G. M., Ž, Z., & Jurić, Š. J. (2024). The Effect of Continuous Positive Airway Pressure on Middle Ear Pressure. 2024 *Southeastern European Medical Journal SEEMEDJ* Vol. 8, Issue 2 <https://ojs.srce.hr/index.php/seemedj/article/view/38696/18425>