



# The Brom Technique for Congenital Supravalvular Aortic Stenosis: A Report of Two Cases

Mustafa Karaçelik<sup>1</sup>, Burçin Abud<sup>2</sup>, Uğur Karagöz<sup>1</sup>, Yılmaz Yozgat<sup>3</sup>, Timur Meşe<sup>3</sup>, Osman Nejat Sariosmanoğlu<sup>1</sup>

<sup>1</sup> Behçet Uz Children Hospital, Clinic of Cardiovascular Surgery, İzmir, Turkey

<sup>2</sup> İzmir Tepecik Training and Research Hospital, Clinic of Cardiovascular Surgery, İzmir, Turkey

<sup>3</sup> Behçet Uz Children Hospital, Clinic of Pediatric Cardiology, İzmir, Turkey

## ABSTRACT

Various surgical techniques have been described to repair congenital supravalvular aortic stenosis, but the best technique is still controversial. The three-patch repair reconstructs a symmetric aortic root and is supposed to restore a normal physiology. We present two successfully operated patients who had congenital supravalvular aortic stenosis using symmetric three-patch repair. We will discuss the decision making of surgical techniques, and its effects of postoperative course of this pathology in this case report.

**Key Words:** Congenital supravalvular aortic stenosis; left ventricular outflow tract

## Konjenital Supravalvular Aort Darlığında Brom Tekniği kullanımı: İki Olgunun Sunumu

### ÖZET

Konjenital supravalvular aort darlığının tedavisinde değişik teknikler tanımlanmıştır, ancak en iyi teknik hangisi hala tartışmalıdır. Üç-yama ile onarım simetrik bir aort kökü ve normal fizyoloji sağlar. Bu yazıda, üç-yama tekniğini kullanarak başarıyla ameliyat ettiğimiz konjenital supravalvular aort darlığı olan iki hastayı sunmaktayız. Cerrahi teknikler arasında karar vermeyi ve bu tekniklerin postoperatif döneme etkisini tartışacağız.

**Anahtar Kelimeler:** Konjenital supravalvar aort darlığı; sol ventrikül çıkım yolu

## INTRODUCTION

Various surgical techniques have been described to repair congenital supravalvular aortic stenosis (SVAS), but the optimal approach remains controversial. The main goal of surgical treatment is resection of left ventricular outflow tract obstruction; this can be achieved using nonsymmetrical repair (one patch or inverted Y-shaped patch) or as well as symmetric three-patch repair (Brom repair)<sup>(1)</sup>. We present here two successfully operated consecutive cases of congenital supravalvular aortic stenosis using three-patch repair in 1-year period between August 2012 and November 2013, and we discuss the decision making of surgical techniques, and its effects of postoperative course of this pathology in this case report.

## CASE 1

A 5-year-old boy was admitted to our hospital with severe SVAS. He was born at 32 weeks of gestation and was diagnosed with reactive airway disease. He also had a history of systolic ejection murmur on physical examination previously. He had no other major congenital defect and mental retardation (WISC-R test). Cardiovascular examination revealed heart rate as 85 bpm, and S1 stiffness, needed all the focus of a systolic ejection murmur. Blood pressure was 140/90 mmHg at both arms. Cardiomegaly and signs of moderate congestion were present on chest X-Ray. Apical anterior viewing and parasternal short axis echocardiography imaging showed that congenital supravalvular aortic stenosis with moderate concentric left ventricular hypertrophy and bicuspid aortic valve with mild insufficiency and preoperative peak systolic pressure gradient between the left ventricle and ascending aorta was 90 mmHg. Aortography was performed before the operation, and all demonstrated a typical hourglass-type stenosis just above the aortic valve (Figure 1). There was no coronary stenosis.

## Correspondence

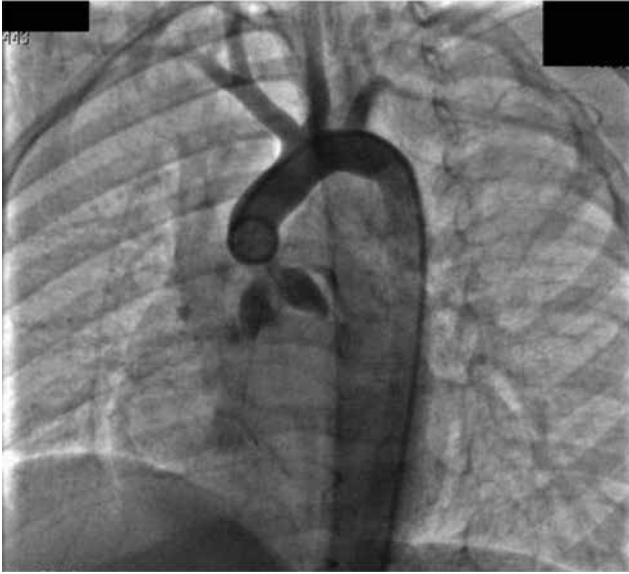Burçin Abud

E-mail: burcinabud@hotmail.com

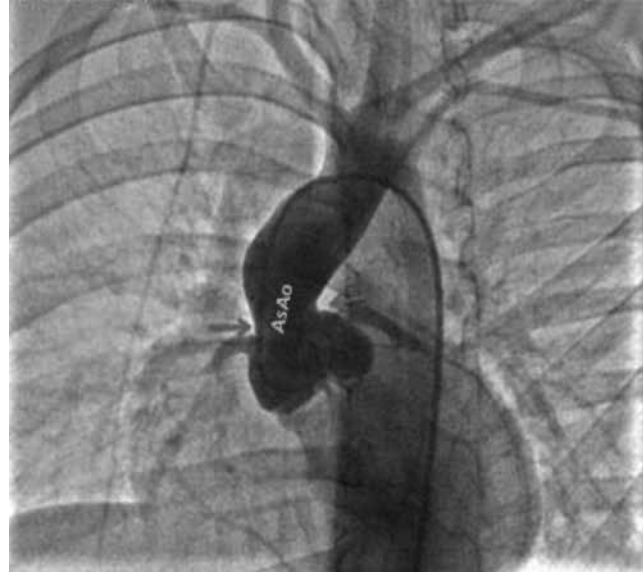Submitted: 28.04.2014

Accepted: 27.06.2014

@ Copyright 2016 by Koşuyolu Heart Journal.  
Available on-line at  
www.kosuyoluheartjournal.com



**Figure 1.** Aortography was performed before the operation, and all demonstrated a typical hour-glass type stenosis of Case 1.



**Figure 2.** Aortography was performed before the operation, and all demonstrated a typical hour-glass type stenosis of Case 2.

## CASE 2

A 15-year-old girl was admitted to our hospital with severe SVAS. She was born at 37 weeks of gestation and was diagnosed with Down syndrome. She also had a history of systolic ejection murmur on physical examination previously. She had no other congenital cardiac defect, but had mental retardation (WISC-R test) and typical Down syndrome signs and symptoms. Cardiovascular examination revealed heart rate as 80 bpm, and S1 stiffness, needed all the focus of a systolic ejection murmur. Blood pressure was measured 145/90 mmHg at both arms. Cardiomegaly and signs of mild congestion were present on chest X-Ray. Preoperative echocardiography findings were as follows: congenital supravalvular aortic stenosis with severe concentric left ventricular hypertrophy and bicuspid aortic valve with mild insufficiency and peak systolic pressure gradient between the left ventricle and ascending aorta was 85 mmHg. Aortography demonstrated a typical hourglass-type stenosis just above the aortic valve (Figure 2). There was no coronary stenosis.

### Anaesthesia

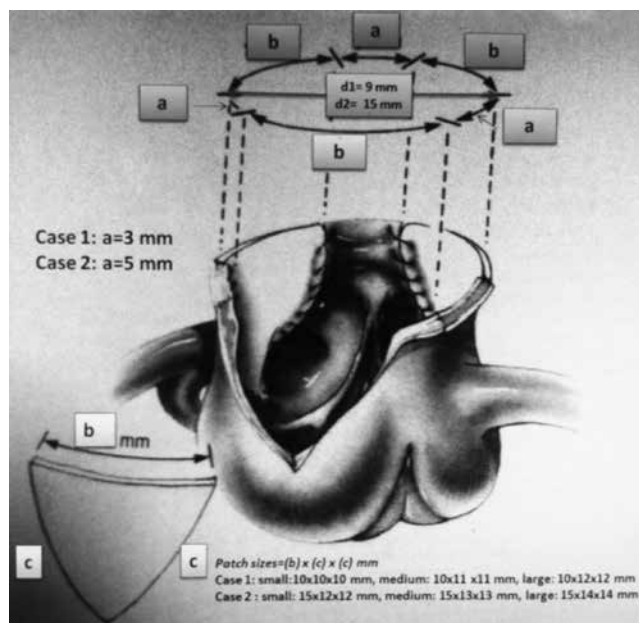
Anaesthesia was induced with 5-6% sevoflurane inhalation, intravenous fentanyl (5 µg/kg) and rocuronium bromide (0.6 mg/kg) in two patients. Anaesthesia was maintained by 3% sevoflurane with the infusion of midazolam (0.1 mg/kg/h) and fentanyl (2 µg/kg/h), and with intermittent bolus doses of rocuronium (0.2 mg/kg). The patient was kept sedated by fentanyl (1 µg/kg/h) and midazolam (0.1 mg/kg/h) infusions in the intensive care unit postoperatively.

### Surgical Management

After informed consent, the patient underwent the corrective surgery under general anaesthesia and cardiopulmonary bypass. Standard surgical techniques were used in two patients by the

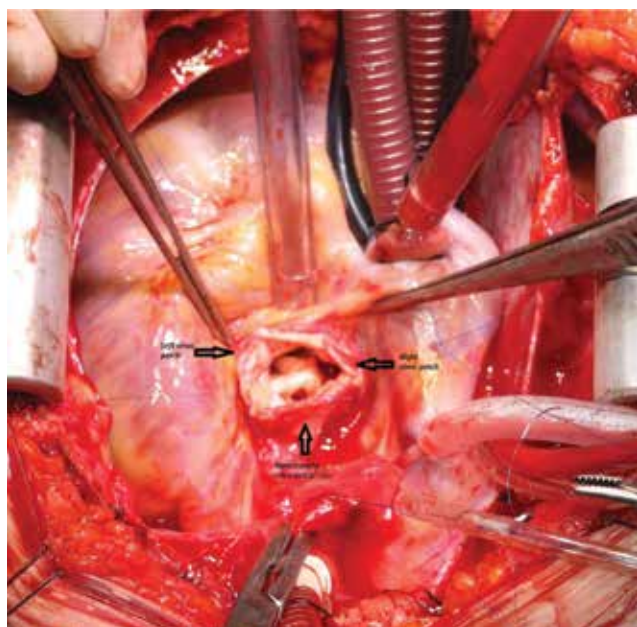
same surgeon. After median sternotomy, autogenic pericardium was prepared as glutaraldehyde-treated pericardial patch. A single aortic and bicaval cannula (Medtronic® Bio-Medicus, Medtronic, Inc. USA) approach was used for the maintenance of cardiopulmonary bypass in moderate hypothermia (Case 1= 30°C, Case 2= 32°C). Aorta was cross-clamped (Case 1= 80 min, Case 2= 85 min) with subsequent antegrade cardioplegia. The aorta was transected at the supravalvular site of stenosis. The normal aortic valve annulus is measured with a Hegar dilator of appropriate size. The circumference of the annulus is approximately three times its diameter or Hegar size<sup>(1)</sup>. In Case 1, the diameter of the opening was 3 mm after transecting the aorta. Case 2 had a 5-mm aperture. Measurements were made with a ruler since the Hegar dilators could not be used. Calculated aortic diameter of Case 1 was measured 9 mm. In Case 2, it was 15 mm (Figure 3). A straight-down incision was made into the non-coronary cusp. Incisions were then performed to the left of the right coronary artery and to the right of the left coronary artery within the respective aortic cusps.

Mitchell et al. described the same technique that we used, as follows: noncoronary sinus is incised vertically at its midpoint. The incision crosses the thick ring into more normal aorta and will improve exposure of the other sinuses. This incision is carried to the base of the sinus. Vertical incisions are then made in the left and right coronary sinuses. These incisions are placed midway between the associated coronary ostium and nearby commissure. The incision in the left sinus is placed to the right of the coronary ostium unless there is inadequate room. The incision in the right sinus is placed to the left of the coronary ostium if possible. This placement minimises the chances of distorting the proximal course of the coronary arteries, but the side of the sinus with most room should be used<sup>(2)</sup>. The small-, medium- and large-sized triangular



**Figure 3.** Sizing and calculating the patches and aortic root.

glutaraldehyde-treated pericardial patches were applied to enlarge the noncoronary, left coronary and right coronary sinuses respectively using 7-0 polypropylene suture (Prodek®, Sutures, Inc., UK) (Figure 4). The left sinus patch is inserted first. The left sinus patch is smallest. The left patch width and height are reduced to avoid excessive enlargement of this sinus. The right sinus is reconstructed followed by the noncoronary sinus. The right sinus is middle in size. Following completion of the left and right sinuses, the patch widths are added, and the required patch width for the noncoronary sinus is determined



**Figure 4.** Aorta after implantation of the three sinus patches (Case 1).

using the total desired enlargement calculated previously<sup>(2)</sup>. There was no need a triangular glutaraldehyde-treated pericardial patch augmentation of the anterior portion of the aorta. Aortic commissurotomy was applied in Case 1 but was not applied in Case 2. The distal and proximal aortic segments were re-approximated posteriorly with a running 6-0 or 7-0 polypropylene suture (Prodek®, Sutures, Inc., and UK). After de-clamping the aorta, all patients were successfully weaned from CPB (Case 1= 120 min, Case 2= 115 min) and transferred to the intensive care unit. Echocardiography on postoperative day 5 demonstrated a 10-mmHg and 15-mmHg peak aortic systolic gradient consistent, respectively, for Case 1 and Case 2 with no residual SVAS and aortic valve insufficiency.

Our cases have not any concomitant pulmonary artery stenosis or enlarged aorta was not done by the external pressure to the pulmonary artery. Patients were discharged on 6<sup>th</sup> day of hospitalisation, uneventfully. Patients were still in a healthy status at the 6<sup>th</sup> month follow-up examination.

## DISCUSSION

Congenital supra-valvar aortic stenosis is one of the rarest obstructive lesions of the left ventricular outflow tract<sup>(3)</sup>. Most of the patients may suffer from the diffuse type, which involves the entire ascending aorta<sup>(4)</sup>. The Brom repair used three different size patches for a symmetric enlargement of the aortic root with the potential advantage of reduced late restenosis rates. Compression of the left main pulmonary artery caused by the enlarged aorta and aortic regurgitation as a result of over sizing of the aortic sinuses is potential complications<sup>(5,6)</sup>. For this reason, we preferred three different size patches, from small to large, during aortic root enlargement in our cases. If all patches are in same size, over sizing of the aortic sinuses could be seen more frequently<sup>(7)</sup>.

Kaushal et al. concluded that the multi-sinus technique was superior to the standard single-patch technique. Kaushal's data demonstrated that the only risk factor predictive of a recurrent gradient requiring reoperation was a sub-aortic myectomy performed at the first procedure<sup>(8)</sup>. Deo et al. showed that the need for reoperation did not show significant difference between the single-patch and three-sinus patch groups. The mean gradient was  $33 \pm 18$  mmHg in the single-patch group and  $18 \pm 12$  mmHg in the three-sinus repair, both of which seem high compared with other series<sup>(9)</sup>. In spite of the opposite view of some authors, multi-sinus reconstructions (inverted bifurcated patchplasty and three-sinus reconstruction) resulted in superior haemodynamics and were associated with reductions in reoperation rate and mortality in most of the articles<sup>(8-10)</sup>. The majority of patients with Williams-Beuren syndrome-related SVAS also have pulmonary artery obstruction. As Ozergin et al. mentioned supra-valvular aortic stenosis can be present without Williams-Beuren syndrome<sup>(11,12)</sup>. Our patients had no Williams-Beuren syndrome signs either. This is remarkable and not concordant condition according the publishing about congenital SVAS. Imamura et al determined that the presence of pulmonary stenosis



and younger age at the time of initial surgery as risk factors for reoperation with SVAS<sup>(5)</sup>. Since our patients had no Williams-Beuren syndrome, this could be accepted as an advantage for freedom from reoperation. Metton et al. reported that bicuspid aortic valve was a risk factor associated with late residual obstruction<sup>(4)</sup>, but Kaushal et al. did not show that bicuspid aortic valve was a risk factor for reintervention<sup>(8)</sup>.

The median age at repair of 4 years was lower than most series. Although earlier repair is proven to be beneficial in ameliorating the secondary pathologic processes, this can result in the setting of supravalvular aortic stenosis remains to be seen<sup>(13,14)</sup>. In our first case, patient was 5 year-old and a good candidate for surgery, but as seen in Case 2, diagnosis and the corrective surgery can be delayed since the social and economic condition of her family was poor. Congenital SVAS is commonly associated with obstruction in other sites along the left ventricular outflow tract and aorta, and such multilevel obstruction occurs progressively during the follow-up<sup>(1,4,14,15)</sup>. Saritaş et al. treated successfully through two sinus reconstruction and ascending aorta replacement using Dacron patches to extensions to the left and non-coronary sinuses in an adult patient<sup>(16)</sup>. Although, SVAS is congenital aortic pathology, this may prove to in adulthood period of life. For this reason, life-long follow-up is advised for the patients with SVAS and our patients are under control with periodic transthoracic echocardiography follow-up.

The single, double, and Y-shaped patch techniques cannot restore the aortic root in an anatomic fashion, but no difference could be demonstrated in outcome for any surgical technique<sup>(17)</sup>. However, reconstruction of the aortic root with autologous pericardial patches in each sinus after transection of the aorta has the advantage of symmetry while restoring the normal aortic root anatomy<sup>(8,14,18)</sup>. This article encouraged our cardiac team to choose three-patch technique, while our decision making of surgical strategy. Metton et al. showed the results after three-patch repair are superior to those of one-patch reconstruction in terms of residual obstruction and development of aortic insufficiency<sup>(4)</sup>. Three-patch repair reconstructs a symmetric aortic root and should restore a normal physiology<sup>(7)</sup>.

Another matter was described by Açıkel et al. that a 4 year-old boy who presented with infective endocarditis with SVAS. Thus, prophylaxis is important and should last a lifetime. However, the interesting point of this article is they used hypothermic circulatory arrest. It was an unusual cardiopulmonary bypass technique for the treatment of this pathology firstly<sup>(19)</sup>.

## CONCLUSION

At the point of decision making for the treatment of congenital SVAS, the surgeons' choice is important, and of course, they will choose one from symmetric or nonsymmetrical techniques<sup>(8)</sup>. To our knowledge and in the light of literature, when compared to the other nonsymmetrical repair techniques, such as one patch

or inverted Y-shaped patch techniques, symmetric three-patch repair provides more anatomical aortic root and mid-term results are highly satisfactory and supravalvular aortic stenosis can be present without Williams-Beuren syndrome.

## REFERENCES

- Brom AG. Obstruction of the left ventricular outflow tract. In: Khonsari S, (ed). *Cardiac surgery: safeguards and pitfalls in operative technique*, 1<sup>st</sup> ed. Rockville, MD: Aspen Publishers, 1988;276-80.
- Mitchell MB, Goldberg SP. Supravalvular aortic stenosis in infancy. *Semin Thorac Cardiovasc Surg Pediatr Card Surg Annu* 2011;14:85-91.
- Inan BK, Ucak A, Gullu AU, Temizkan V, Ugur M, Yilmaz AT. Left main coronary artery and supravalvular aortic stenosis in adult: treatment with ostial patchplasty and modified brom procedure. *J Card Surg* 2009;24:299-300.
- Metton O, Ali WB, Calvaruso D, Bonnet D, Sidi D, Raïsky O, et al. Surgical management of supravalvular aortic stenosis: does brom three-patch technique provide superior results? *Ann Thorac Surg* 2009;88:588-93.
- Imamura M, Prodhon P, Dossey AM, Jaquiss RDB. Reoperation after supravalvular aortic stenosis repair. *Ann Thorac Surg* 2010;90:2016-22.
- Greutmann M, Tobler D, Sharma NC, Muhll IV, Mebus S, Kaennerer H, et al. Cardiac outcomes in adults with supravalvular aortic stenosis. *Eur Heart J* 2012;33:2442-50.
- Hazekamp MG, Kappetein AP, Schoof PH, Ottenkamp J, Witsenburg M, Huymans HA, et al. Brom's three-patch repair technique for repair of supravalvular aortic stenosis. *J Thorac Cardiovasc Surg* 1999;118:252-8.
- Kaushal S, Backer CL, Patel S, Gossett JG, Mavroudis C. Midterm outcomes in supravalvular aortic stenosis demonstrate the superiority of multisinus aortoplasty. *Ann Thorac Surg* 2010;89:1371-7.
- Deo SV, Burkhart HM, Schaff HV, Li Z, Stensrud PE, Olson TM, et al. Late outcomes for surgical repair of supravalvular aortic stenosis. *Ann Thorac Surg* 2012;94:854-9.
- Dağlar B, Kırallı K, Yakut N, Tuncer A, Balkanay M, İpek G, et al. The surgical repair of congenital supravalvular aortic stenosis by single sinus aortoplasty technique: mid-long term results. *Turk Gogus Kalp Dama* 1999;7:223-8.
- Bostan ÖM, Çil E. Evaluation of nine cases of supravalvular aortic stenosis. *Türk Kardiyol Dern Arş* 2000;28:752-6.
- Ozergin U, Sunam GS, Yeniterzi M, Yüksek T, Solak T, Solak H. Supravalvular aortic Stenosis without Williams syndrome. *Thorac Cardiovasc Surg* 1996;44:219-21.
- Mitchell MB, Goldberg SP. Brom repair for supravalvular aortic stenosis. *operative techniques in thoracic and cardiovascular surgery* 2011;16:70-84.
- Hickey EJ, Jung G, Williams WG, Manlhiot C, Van Arsdell GS, Caldaroni CA, et al. Congenital supravalvular aortic stenosis: defining surgical and nonsurgical outcomes. *Ann Thorac Surg* 2008;86:1919-27.
- Brown JW, Ruzmetov M, Vijay P, Turrentine MW. Surgical repair of congenital supravalvular aortic stenosis in children. *Eur J Cardiothorac Surg* 2001;21:50-6.
- Saritaş A, Ünal EU, Sevük U, Kubat E, Aksöyek A, Birinciöğlü CL. Repair of congenital supravalvular aortic stenosis in an adult patient. *Turk Gogus Kalp Dama* 2013;21:796-8.
- Kavarana MN, Riley M, Sood V, Ohye RG, Devaney EJ, Bove EL, et al. Extended single-patch repair of supravalvular aortic stenosis: a simple and effective technique. *Ann Thorac Surg* 2012;93:1274-9.
- Stamm C, Kreutzer C, Zurakowski D, Nollert G, Friehs I, Mayer JE, et al. Forty-one years of surgical experience with congenital supravalvular aortic stenosis. *J Thorac Cardiovasc Surg* 1999;118:874-85.
- Açıkel Ü, Uğurlu B, Karabay Ö, Meşe T, Saylan G, Oto Ö. Surgical therapy by using retrograde cerebral perfusion and total circulatory arrest in a case having infective endocarditis due to supravalvular aortic stenosis. *Turk Gogus Kalp Dama* 1998;6:221-4.