



Popliteal Artery Entrapment Syndrome with Atypical Claudication and Popliteal Artery Aneurysm

Mustafa Bahadır İnan, Fatih Ada, Mehmet Taşar, Evren Özçınar, Mehmet Çakıcı, Sadık Eryılmaz, Bülent Kaya, Adnan Uysalel

Ankara University Faculty of Medicine, Department of Cardiovascular Surgery, Ankara, Turkey

ABSTRACT

Popliteal artery entrapment syndrome (PAES) is a rare disease among young males characterised by the abnormal relationship between PA and the bundles of the gastrocnemius muscle and surrounding fibrous structures. In this case report, we aim to present our approach to a thrombosed PA aneurysm due to PAES in an old man.

Key Words: Popliteal Artery; aneurysm; intermittent claudication

Atipik Seyirli Klodikasyo ve Popliteal Arter Anevrizmanın Eşlik Ettiği Popliteal Arter Tuzak Sendromu

ÖZET

Popliteal arter tuzak sendromu genellikle genç erkeklerde görülen, popliteal arterin gastrocnemius kas ve çevresindeki fibröz doku ile normal komşuluğu sonucunda ortaya çıkan nadir bir hastalıktır. Bu yazımızda, ileri yaşta bir erkek hastada popliteal arter tuzak sendromuna bağlı gelişen tromboze popliteal arter anevrizma olgusuna yaklaşımımızı sunmayı amaçladık.

Anahtar Kelimeler: Popliteal arter; anevrizma; intermitan klodikasyo

INTRODUCTION

Popliteal artery entrapment syndrome (PAES) is a rare congenital disease in which the main pathology is the abnormal relationship between PA and the medial head of the gastrocnemius muscle. PA may be involved alone or with the popliteal vein. It is one of the most common non-atherosclerotic diseases of PA.

Although PAES was first described in 1879 by Anderson Stuart in a 64-year-old male, it mainly affects young males. The symptoms are often caused by acute ischemia following an exercise. Chronic presentation is very rare.

We present a 67-year-old male who was suffering from chronic claudication caused by a PA aneurysm because of PAES.

CASE REPORT

A 67-year-old male was admitted to the Vascular Surgery Department with chronic claudication of the left lower extremity. He had chronic leg pain. However, the symptoms worsened in the last months, and the claudication became apparent at a distance of > 100 m.

The pallor was present in the left leg, and the pulses distal to the femoral artery, including PA, were absent. In addition, there was a palpable rigid mass in the popliteal fossa. Doppler ultrasound showed a PA aneurysm and an absent distal flow. Angiography and computed tomography (CT) showed a left PA aneurysm with poorly perfused distal arteries (Figures 1,2).

He was scheduled for a surgical PA aneurysm repair. After epidural anaesthesia, a medial incision was made and the great saphenous vein was prepared as a graft for the repair. The incision was made to a subsartorial level to expose PA and the aneurysm.

Correspondence

Mehmet Taşar

E-mail: mehmet.tasar@hotmail.com

Submitted: 13.05.2014

Accepted: 03.06.2014

© Copyright 2016 by Koşuyolu Heart Journal.
Available on-line at
www.kosuyoluheartjournal.com

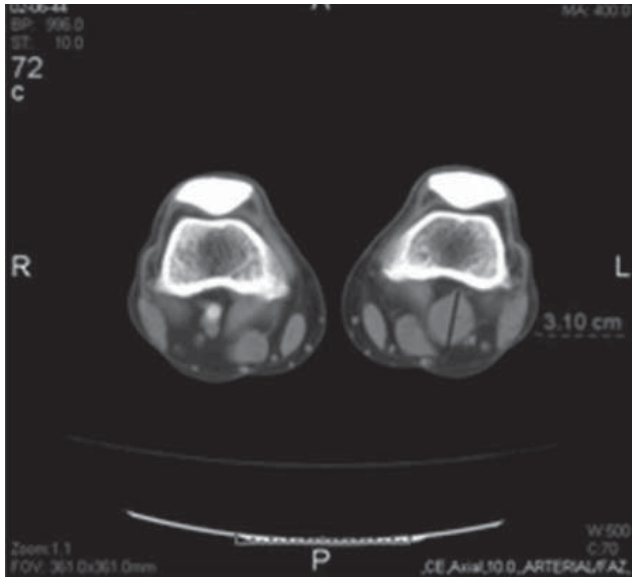


Figure 1. Poorly distal perfusion was observed after the PA aneurysm on computed tomography angiography.

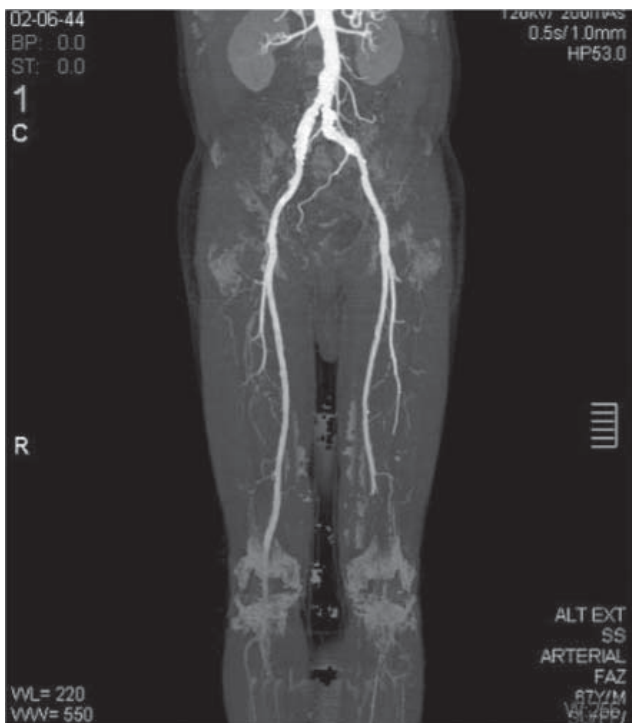


Figure 2. Thrombosed PA aneurysm was observed on computed tomography angiography.

PA was dissected and controlled proximally and distally. During the dissection of PA, it was realised that the artery was compressed between the medial head and accessory head of the gastrocnemius muscle. It was diagnosed as type III PAES. To relieve the arterial outflow, myotomy was performed on the accessory head of the gastrocnemius muscle. Following myotomy, the thrombosed aneurysm was resected and a great

saphenous vein interposition was performed. Following the anastomosis, intra-operative Doppler ultrasonography showed that distal flow and pulses were present. The post-operative period was uneventful, and the patient was discharged on the post-operative day 4.

DISCUSSION

PAES was first described by T.P. Anderson Stuart in 1879. PAES is a developmental abnormality that results from an abnormal relationship between PA and the gastrocnemius muscle or rarely an anomalous fibrous band or popliteus muscle⁽¹⁾. The classification for PAES was introduced by Delaney and Gonzales in 1971 and types V and VI were added⁽²⁾ (Table 1). PAES is a low prevalence pathology that causes intermittent claudication in healthy young adults^(3,4). In our case, we observed a type III popliteal entrapment, which is more common in the third decade and very rare after 50 years of age. Claudication, following an exercise period, is the main presentation in patients with PA. However, our patient was a 67 year old male with chronic symptoms, contrary to our classic knowledge. Some patients may be asymptomatic until the acute vascular occlusion or post-stenotic dilatation caused by thromboembolic complications^(5,6). In our case, the symptoms occurred after the thrombosis of the aneurysm. Radiological imaging studies are very useful when combined with physical examination. Duplex Doppler imaging is the first common choice. Therefore, in our case, a left lower extremity Doppler ultrasound was performed. CT, with or without a three-dimensional reconstruction, is also useful for the diagnosis of PAES⁽²⁾. It is sometimes difficult to preoperatively recognise PAES. In conclusion, PAES must be considered in patients who suffer from chronic claudication symptoms with a PA aneurysm, which is not a typical presentation of this disease.

Table 1. Popliteal artery entrapment syndrome classification

Type I: Medial head of the gastrocnemius muscle is normal; the popliteal artery is medially deviated and has an aberrant course.

Type II: Medial head of the gastrocnemius muscle is located laterally and no deviation in the popliteal artery.

Type III: Abnormal muscle bundle from the medial head of the gastrocnemius muscle surrounding the popliteal artery.

Type IV: The popliteal artery is deeply located and entrapped by the popliteus muscle or fibrous band.

Type V: The popliteal vein is also entrapped with any type of the popliteal artery.

Type VI: The popliteal artery is normal and entrapped by a normal positioned, hypertrophied gastrocnemius muscle and the so-called functional entrapment.

REFERENCES

1. Roche-Nagle G, Wong KT, Oreopoulos G. Vascular claudication in a young patient: popliteal entrapment syndrome. *Hong Kong Med J* 2009;15:388-90.
2. Karaman B, Battal B, Akgun V, Hamcan S, Bozkurt Y, Bozlar U. Popliteal artery entrapment syndrome with thrombosed popliteal aneurysm: multidetector computed tomography angiography findings of a case. *Clinical Imaging* 2012;36:850-3.
3. Levien LJ. Popliteal artery entrapment syndrome. *Semin Vasc Surg* 2003;16:223-31.
4. Kaya E, Doğanç S, Kadan M, Erol G, Günay C, Demirkılıç U. Dev tromboze popliteal arter anevrizması. *Ulusal Vasküler Cerrahi Dergisi* 2012;21:171-4.
5. Yavaş D, Uzun Z, Özcan F. Popliteal arter entrapment sendromu. *Göğüs Kalp Damar Cer Derg* 1992;1:207-10.
6. Bustabad MR, Ysa A, Perez E, Merino J, Bardón F, Vela P, et al. Popliteal artery entrapment: eight years experience. *EJVES Extra* 2006;12:43-51.