

Sudden Cardiac Death Due to Left Atrial Ball Thrombus



Sol Atriyal Top Trombüs Nedenli Ani Kardiyak Ölüm

Turhan Turan¹, Ahmet Çağrı Aykan¹, Ali Rıza Akyüz²

¹ Ahi Evren Chest Cardiovascular Surgery Education and Research Hospital, Clinic of Cardiology, Trabzon, Turkey

² Akçaabat State Hospital, Clinic of Cardiology, Trabzon, Turkey

A 72-year-old female patient was admitted to our clinic with progressively increasing dyspnea, palpitation and fatigue. She was being followed up with the diagnoses of congestive heart failure and atrial fibrillation without anticoagulants for the past five years. On physical examination, a diastolic murmur was heard over the mitral area, which had a beat-to-beat variability in intensity. Routine laboratory tests were normal. The electrocardiogram showed atrial fibrillation with rapid ventricular response (140 beats/min). Transthoracic echocardiography revealed a 26 x 33 mm free-floating ball mass in the left atrium (Figure 1, 2). There was no concomitant mitral valve pathology. Although urgent cardiac surgery was planned, sudden death occurred shortly after the diagnosis probably due to partial mitral stenosis.

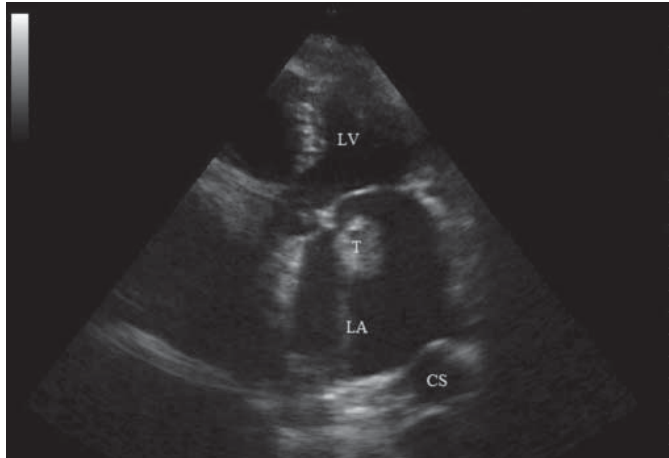


Figure 1. 26 x 33 mm free floating ball thrombus in the left atrium (LV: Left ventricle, LA: Left atrium, T: Thrombus, CS: Coronary sinus).

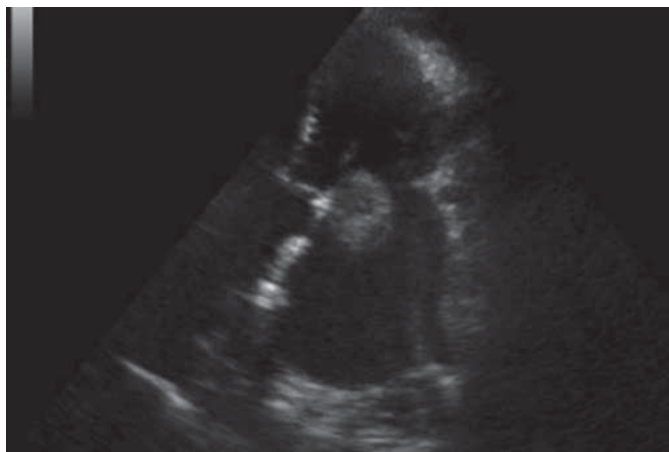


Figure 2. Partial mitral stenosis caused by ball thrombus.

Correspondence

Turhan Turan

E-mail: drtt61@gmail.com

Submitted: 19.05.2014

Accepted: 09.06.2014

@ Copyright 2015 by Koşuyolu Heart Journal.
Available on-line at
www.kosuyoluheartjournal.com