

Management of Pleomorphic Adenoma in the Nasopharynx: A Case Report

Zahide Mine Yazıcı¹, Yakup Yeğın¹, Ömer Erdur², Mustafa Çelik¹, Fatma Tülin Kayhan¹

¹Department of Otorhinolaryngology, Bakirkoy Dr.Sadi Konuk Training and Research Hospital, İstanbul, Turkey

²Department of Otorhinolaryngology, Selcuk University Faculty of Medicine, Konya, Turkey

Background: Pleomorphic adenomas (PAs) are the most common type of benign salivary gland tumours and usually originate from the major salivary glands. PA originating from the nasopharynx has rarely been reported in the literature.

Case Report: A 62 year-old male presented with right aural fullness and subjective hearing loss. Otoscope examination revealed an opaque and bulging tympanic membrane. Nasal endoscopic examination revealed a smooth mass arising from the right wall of the nasopharynx, obstructing the opening of the right Eusta-

chian tube. The MRI showed a 1.3x2x1.3 cm sharply outlined and lobar mass in the right lateral wall of the nasopharynx. The tumour was meticulously detached from its attachment site and excised via the transnasal route under endoscopic visualisation.

Conclusion: We reported pleomorphic adenoma in the nasopharynx in a patient who presented with serous otitis media that successfully resected with transnasal endoscopic surgery and discussed the treatment methods.

Keywords: Endoscopy, nasopharynx, pleomorphic adenoma

Less than 5% of all head and neck tumours are formed by salivary gland tumours. Pleomorphic adenomas (PAs) (benign mixed tumour) constitute approximately 70% of all salivary gland tumours (1, 2). PAs usually originate from the parotid glands and submandibular glands (3). Less commonly, PAs occur from the minor glands, especially in the lips and hard-palate. PAs can also be originated in other sites such as the oral cavity, pharynx, sinuses, laryngeal area, and tracheal mucosa, where minor glands are present. PAs have rarely been found in the nasopharynx (1).

Generally, the presenting symptoms and treatment of PAs are based on the physical properties like the size and originating area of the tumour. Patients most frequently present with obstructive symptoms, including difficulty breathing, chronic sinusitis, nasal and postnasal discharge (1). Other symptoms include epistaxis, otalgia, headache, and serous otitis media (1). The primary treatment of this tumour is complete surgical

resection. The nasopharynx is not easy to access with suitable surgical methods because of the inadequate exposure. Trans-mandibular, transmaxillary, transpalatal and transpterygoid approaches have been used for larger tumours. The transnasal approach using an endoscope is indicated for selected small tumours (2). In this article, we describe a PA in the nasopharynx of a patient who presented with serous otitis media and whose tumour was completely excised via endoscopic visualisation.

CASE PRESENTATION

The patient was male and 62 years-old. He had a sense of fullness, hearing loss and mild otalgia in his right ear for three months. There was no otologic disease or surgery in his previous history. A normal right auditory canal but an opaque and bulging tympanic membrane was detected by otoscopy.

Address for Correspondence: Dr. Ömer Erdur, Department of Otorhinolaryngology, Selcuk University Faculty of Medicine, Konya, Turkey

Phone: +90 505 371 79 08 e-mail: dromerdur@yahoo.com

Received: 11.06.2014 Accepted: 08.10.2014 • DOI: 10.5152/balkanmedj.2015.15503

Available at www.balkanmedicaljournal.org

Cite this article as:

Yazıcı ZM, Yeğın Y, Çelik M, Kayhan FT, Erdur Ö. Management of pleomorphic adenoma in the nasopharynx: a case report. *Balkan Med J* 2015;32:118-20.



The tympanometric evaluation of the patient revealed a type B tympanogram. Given this finding, serous otitis media was considered. Nasal endoscopic examination revealed a cystic and smooth mass originating from the right side of the nasopharynx. Also, it was enlarged to the Rosenmuller fossa and caused obstruction of the right Eustachian tube (Figure 1). The MRI showed a 1.3x2x1.3 cm sharply outlined lobar mass in the right side of the nasopharynx, spreading to the anterior of the fossa of Rosenmuller (Figure 2a, b).

By histological analysis of the biopsy, the lesion was diagnosed as PA. The area that the PA originated from was seen in the right anterolateral side of the nasopharynx with the aid of 0-degree and 30-degree endoscopes (Karl Storz, Germany). The lesion was totally excised from its originated area with the help of the electro-

cautery and forceps by the nasal endoscopic way. The Eustachian tube orifice was carefully inspected to determine the possibility of oedema and cautery inflammation. A shepard ventilation tube was inserted to the right tympanic membrane. No complication was developed. The postoperative diagnosis of the completely excised tumour histologically confirmed PA. Endoscopic and otoscopic examination of the patient revealed no abnormalities (Figure 3). One year after the surgery, control MRI showed no residual mass in the nasopharynx.

DISCUSSION

Pleomorphic adenoma constitutes the majority of benign tumours of all of the salivary glands (3). PAs are generally

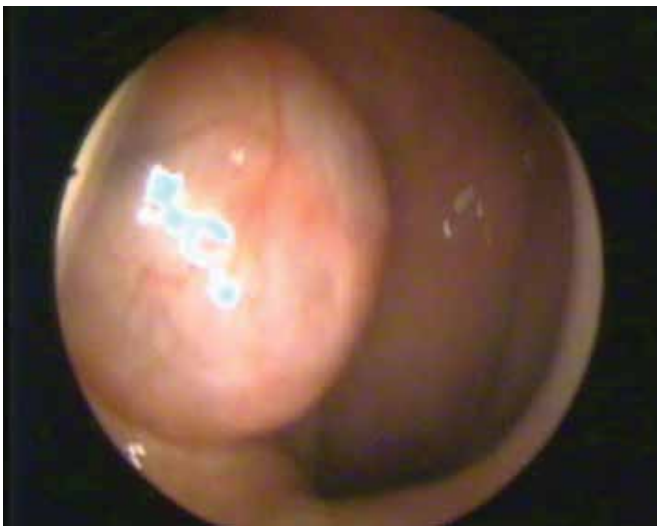


FIG. 1. Nasopharyngeal endoscopic examination of tumor

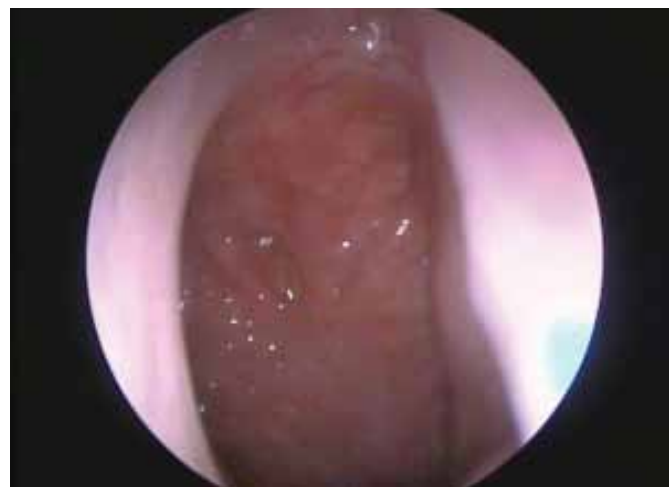

FIG. 3. Postoperative endoscopic examination of tumor at 1 year follow-up period

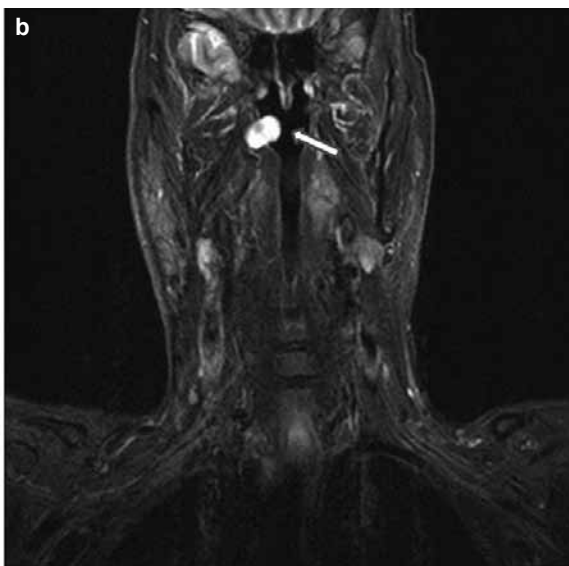
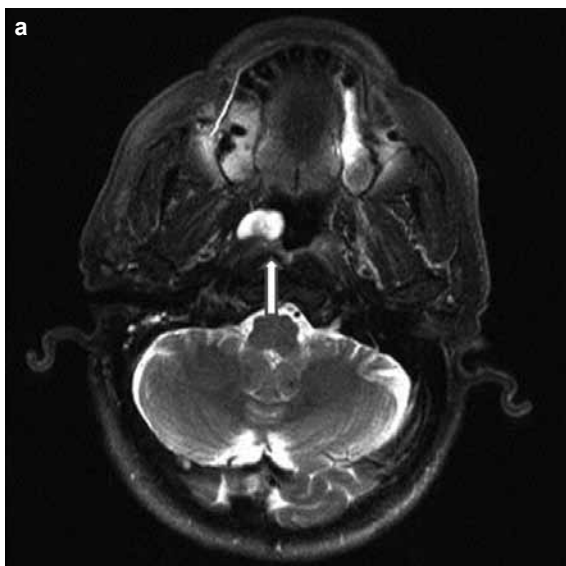


FIG. 2. a, b. Axial and coronal MRI images showing a mass in the right side of the nasopharynx (arrow)

found in major salivary glands and rarely in the nasopharynx (3). To our knowledge, only a few cases of nasopharyngeal pleomorphic adenoma have been described in the English literature (4). When a PA arises from the nasopharynx, the major symptom is nasal congestion due to obstruction of the nasal airway. Other symptoms, such as epistaxis, otalgia, dysphagia, hearing loss, mucopurulent rhinorrhea, and serous otitis media, may also be reported. In our case, the major symptoms were hearing loss and ear fullness. Due to the unusual localisation of the tumour, lymphoma, angiofibroma, haemangioma, hamartoma, non-epithelial tumours, and various cysts should be considered in the differential diagnosis of PA (1).

The lesion usually appears with a smooth surface, an elastic and rubbery structure upon physical examination and no destruction of the mucosa of the surrounding adjacent structure. In addition, a PA does not bleed easily. Radiological evaluation and endoscopic examination are very useful in determining the most appropriate surgical treatment. An imaging assessment alone cannot differentiate a PA from other low-grade malignant tumours of the nasopharynx. An incisional biopsy or fine needle aspiration biopsy is needed for the initial diagnosis before the main treatment of the tumour. However, fine needle aspiration is not possible for a mass in the nasopharynx (5). Total surgery excision is not simple because of the location of the tumour in the nasopharynx, which is adjacent to important structures, such as the Eustachian tube and the cranial nerves. Thus, selecting the correct surgery is important to avoid complications. In the present case, we first performed a biopsy. Following the biopsy results, we totally removed the entire lesion via a transnasal endoscopic approach. Microscopically, epithelial, myoepithelial and stromal elements usually form the histologic structure of the PAs (2). Myxoid, cellular and mixed type are the main histological subgroups of PA.

The diagnosis of PA in the nasopharynx is not difficult. Complete excision is necessary for tumours with histologically clear margins (5). Although the surgical approach is not easy, en bloc resection of a PA in the nasopharynx is feasible. Complications like bleeding and Eustachian tube dysfunction after operation can occur and are usually due to blind resection. For nasopharyngeal PAs, the rate of malignant degeneration is not known exactly, but degeneration to carcinoma ex pleomorphic adenoma were reported in some case reports (3).

External approach to the nasopharynx may lead to significant postoperative morbidity. Therefore, we prefer to use an endoscopic approach to excise the tumour. The use of endoscopic techniques provides a large surgical field and excellent visualisation, thereby avoiding surgical morbidity. Endoscopy also prevents blind resection and the destruction of adjacent structures. In the present case, the endoscopic approach was preferred to remove the tumour from the nasopharynx, and endoscopy also helped to identify the attachment site of the lesion.

Careful follow-up of PA is necessary to ensure that an insufficient excision is diagnosed at an early stage. Endoscopic examination must be combined with imaging. In our patient, the control imaging and examination were clear. Combining the endoscopic approach with robotic surgery is another interesting possibility (6). Because of the potential malignant degeneration of recurrences, the surgery for recurrent PAs must be radical and wide.

Ethics Committee Approval: N/A.

Informed Consent: Written informed consent was obtained from the patient who participated in this study.

Peer-review: Externally peer-reviewed.

Author contributions: Concept - Z.M.Y., F.T.K., Y.Y., O.E.; Design - Z.M.Y., Y.Y., M.C., O.E., Y.Y.; Supervision - Z.M.Y., F.T.K.; Resource - Z.M.Y., Y.Y., M.C.; Materials - Z.M.Y., Y.Y., M.C.; Data Collection&/or Processing - Z.M.Y., Y.Y., M.C.; Analysis&/or Interpretation - Z.M.Y., F.T.K., O.E.; Literature Search - Z.M.Y., Y.Y., M.C., O.E.; Writing - Z.M.Y., Y.Y., O.E.; Critical Reviews - Z.M.Y., F.T.K., Y.Y., O.E.

Conflict of Interest: No conflict of interest was declared by the authors.

Financial Disclosure: The authors declared that this study has received no financial support.

REFERENCES

1. Roh JL, Jung BJ, Rha KS, Park CI. Endoscopic resection of pleomorphic adenoma arising in the nasopharynx. *Acta Otolaryngol* 2005;125:910-2. [\[CrossRef\]](#)
2. Berrettini S, Fortunato S, De Vito A, Bruschini L. A rare case of nasopharyngeal pleomorphic adenoma. *Case Rep Otolaryngol* 2013;2013:712873.
3. Martinez-Capoccioni G, Martin-Martin C, Espinosa-Restrepo F. Transnasal endoscopic resection of a nasopharyngeal pleomorphic adenoma: a rare case report. *Eur Arch Otorhinolaryngol* 2012;269:2009-13. [\[CrossRef\]](#)
4. Maruyama A, Tsunoda A, Takahashi M, Kishimoto S, Suzuki M. Nasopharyngeal pleomorphic adenoma presenting as otitis media with effusion: Case report and literature review. *Am J Otolaryngol* 2014;35:73-6. [\[CrossRef\]](#)
5. Kuo YL, Tu TY, Chang CF, Li WY, Chang SY, Shiao AS et al. Extra-major salivary gland pleomorphic adenoma of the head and neck: a 10-year experience and review of the literature. *Eur Arch Otorhinolaryngol* 2011;268:1035-40. [\[CrossRef\]](#)
6. Ozer E, Waltonen J. Transoral robotic nasopharyngectomy: a novel approach for nasopharyngeal lesions. *Laryngoscope* 2008;118:1613-6. [\[CrossRef\]](#)