

A Rare Etiology of Heart Failure: Traumatic Arteriovenous Fistula Due to Stab Injury 17 Years Ago

Serhat Hüseyin¹, Volkan Yüksel¹, Orkut Güçlü¹, Mustafa Yılmaztepe², Suat Canbaz¹

¹Department of Cardiovascular Surgery, Trakya University Faculty of Medicine, Edirne, Turkey

²Department of Cardiology, Trakya University Faculty of Medicine, Edirne, Turkey

Background: Although traumatic fistula is frequently encountered, high-output heart failure due to fistula is a very rare condition. Despite an indefinite history of trauma, arteriovenous (AV) fistula may develop insidiously, and therefore identification of a shunt is highly important for treatment.

Case Report: Here we report a 46-year-old male patient with heart failure due to traumatic femoral arterio-

venous fistula developed following a penetrating stab injury 17 years ago.

Conclusion: Traumatic AV fistula is a curable cause of heart failure. Also, careful examination of the patient is as significant as radiological imaging methods.

Keywords: Arteriovenous fistula, heart failure, penetrating injury

Arteriovenous (AV) fistula is defined as the development of a connection between the arterial and venous systems. AV fistula may be congenital, acquired or iatrogenic in nature. The most frequent cause of acquired AV fistula is iatrogenic injury. The diagnosis of post-traumatic AV fistula cases is usually delayed, yet this clinical condition can be subject to a dramatic cure. Patients frequently present with a clinical picture of developed AV fistula, and detection of the arteriovenous fistula is incidental. These patients may present to the clinic with non-specific complaints like hematuria as well as heart failure secondary to increased fistula flow rate (1,2). We aimed to present a case of post-traumatic AV fistula detected during advanced examinations for the etiology of heart failure in this patient with a history of a penetrating stab injury in the femoral region 17 years ago in the context of the literature.

CASE PRESENTATION

A male patient at 46 years of age was admitted to hospital with complaints of dyspnea and leg swelling for 6 months.

Echocardiography of the patient revealed cardiomegaly (Left ventricular end diastolic diameter (LVEDD): 65 mm, left ventricular end systolic diameter (LVESD): 40 mm), moderate mitral insufficiency, reduced left ventricular ejection fraction (EF: 30%) and pulmonary hypertension (55 mmHg). Coronary angiography was normal. There was a history of a penetrating stab injury on the left femoral lateral site 17 years ago and no history of surgical intervention. Other causes of heart failure were eliminated.

Physical examination of the patient revealed a strong thrill spreading from the left inguinal region to the left inferior abdominal quadrant. In addition, hyperpigmentation and dilatation of superficial veins due to stasis were present on the left lower extremity below the knee. The Nicoladoni-Branham sign was positive. Magnetic resonance (MR) angiography (Signa HDI, General Electric, Milwaukee, WI, USA) of the lower extremity detected a fistula tract between the common femoral artery (CFA) and common femoral vein (CFV) (Figure 1).

Under general anesthesia, arteries and vein were explored following an incision on the left femoral region. The fistula tract between the CFA and CFV was ligated by silk suture



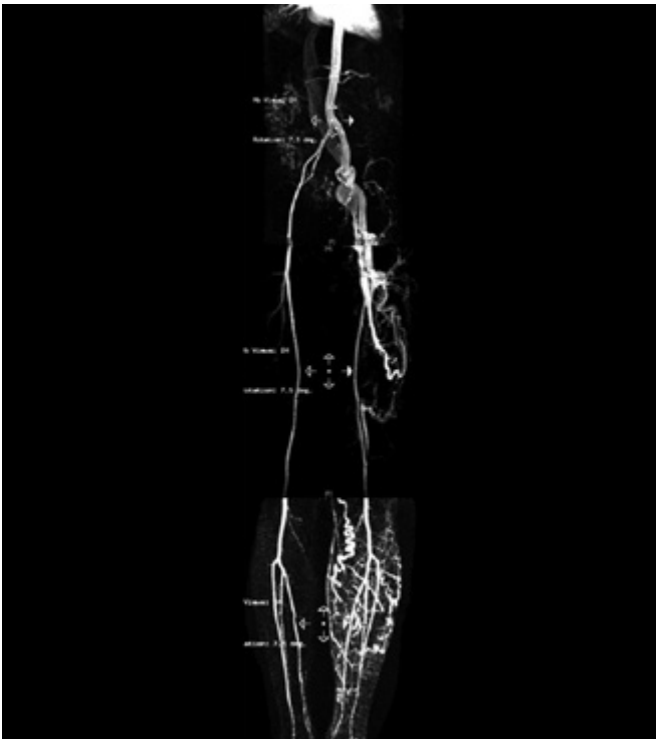


FIG. 1. Magnetic resonance angiography shows the femoral arteriovenous fistula

(Figure 2). Postoperatively, the thrill in the left inguinal region of patient disappeared and distal pulses were palpable. The patient was anticoagulated with intravenous 20000 units/day heparin during the postoperative period.

Echocardiography was repeated on postoperative day 7 (LVEDD: 61 mm, LVESD: 49 mm) and mild to moderate mitral insufficiency was detected; left ventricular EF was 40% and pulmonary arterial pressure (PAB) was 50 mmHg. Anticoagulant treatment was initiated because a spontaneous echo contrast was detected on echocardiography and a thrombosis in the popliteal vein. Following anticoagulant treatment, the patient was discharged. Echocardiography was repeated 6 months later (LVEDD: 47 mm, LVESD: 41 mm); mild mitral insufficiency and left ventricle EF 44%, PAB 50 mmHg were detected. In addition, no finding in favor of spontaneous echo contrast and thrombosis of the popliteal vein was detected.

Institutional ethics approval for the study was obtained from the local ethics committee. Also, a patient consent form was taken from the patient.

DISCUSSION

Trauma, especially low energy trauma such as stab injuries and small caliber gunshot injuries, is the most important

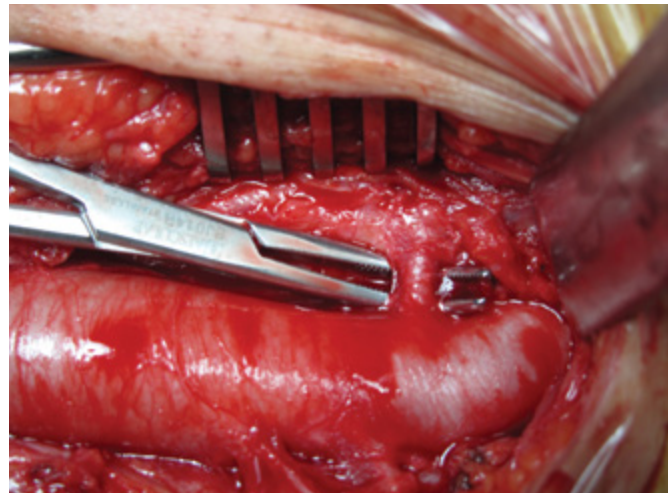


FIG. 2. Intraoperative view of femoral arteriovenous fistula tract

cause of acquired AV fistula. Approximately 2% of traumatic AV fistulas close spontaneously and symptoms are relieved (3).

A prolonged increase in blood flow leads to vasodilatation by changing the elastic fiber structure of the vessel wall, leading to a further increase in fistula flow (4). As a result of the increased shunting from left to right, chronic volume overload occurs and ventricular dilatation due to cardiac remodeling and heart failure are observed. Complaints of heart failure were prominent in our patient.

In addition to murmur and a strong thrill on the inguinal region, physical examination may reveal ulceration alone or with additional pigmentation, edema and varicosities as findings of chronic venous stasis. In our patient, hyperpigmentation and superficial vein dilatation were also present on the left lower extremity below the knee.

Although conventional angiography is the gold standard in the diagnosis of AV fistula, rapid and appropriate diagnosis can be made by less invasive imaging methods like Doppler ultrasonography (USG), MR angiography and computerized tomography angiography. We made our diagnosis in our patient by 1.5 Tesla MR (Signa HDI, General Electric, Milwaukee, WI, USA) angiography.

Post-traumatic fistula should be surgically closed as early as possible (5). Untreated fistulas may lead to complications such as high-output heart failure (50%) and rennin dependent hypertension (40%). Treatment with a stent may be preferred in hemodynamically unstable patients (6). We treated our patient surgically by ligating the AV fistula developed between the femoral artery and vein.

Nara et al. (7) reported progression of heart failure following closure of an AV fistula, while Bajraktari et al. (8) reported dramatic improvement in symptoms of failure following surgical repair. Surgical intervention leads to rapid improvement

in heart failure (8). In our patient, clinical complaints of heart failure rapidly improved, while echocardiographic improvement was observed over time. However, an abrupt increase in systemic vascular resistance may be the cause of an increase in heart failure. Patients need inotropic and vasodilator support during the post-operative period. Therefore, we monitored our patient in the intensive care unit during the post-operative night in order to be ready for possible aggravation of heart failure. In addition, during the post-operative period, deep venous thrombosis developed in our patient despite heparinization.

Consequently, traumatic AV fistula is a treatable cause of heart failure. A careful examination of history and complete physical examination are as significant as radiological imaging methods.

Ethics Committee Approval: Ethics committee approval was received for this study from the local ethics committee.

Informed Consent: Written informed consent was obtained from the patient who participated in this study.

Peer-review: Externally peer-reviewed.

Author contributions: Concept - S.H., O.G.; Design - S.H., V.Y.; Supervision - S.C.; Resource - S.H., O.G., V.Y.; Materials - S.H., M.Y.; Data Collection &/or Processing - S.H., O.G.; Analysis &/or Interpretation - S.H., M.Y.; Literature Search - S.H., V.Y.; Writing - S.H., O.G.; Critical Reviews - S.C.

Conflict of Interest: No conflict of interest was declared by the authors.

Financial Disclosure: The authors declared that this study has received no financial support.

REFERENCES

1. Siddique MK. Post-traumatic arteriovenous fistula reporting with haematuria after 25 years. *J Coll Physicians Surg Pak* 2012;22:591-3.
2. Yared K, Baggish AL, Wood MJ. High-output heart failure resulting from a remote traumatic arteriovenous fistula. *Can J Cardiol* 2009;25:143-4. [\[CrossRef\]](#)
3. Perry MO. Complications of missed arterial injuries. *J Vasc Surg* 1993;17:399-407. [\[CrossRef\]](#)
4. Hartung O, Garcia S, Alimi YS, Juhan C. Extensive arterial aneurysm developing after surgical closure of long-standing post-traumatic popliteal arteriovenous fistula. *J Vasc Surg* 2004;39:889-92. [\[CrossRef\]](#)
5. Ilijevski N, Radak D, Radevic B, Sagic D, Kronja G, Misovic S, et al. Popliteal traumatic arteriovenous fistulas. *J Trauma* 2002;52:739-44. [\[CrossRef\]](#)
6. O'Brien J, Buckley O, Torreggiani W. Hemolytic anemia caused by iatrogenic arteriovenous iliac fistula and successfully treated by endovascular stent-graft placement. *AJR Am J Roentgenol* 2007;188:306. [\[CrossRef\]](#)
7. Nara T, Yoshikawa D, Saito S, Kadoi Y, Morita T, Goto F. Peri-operative management of biventricular failure after closure of a long-standing massive arteriovenous fistula. *Can J Anaesth* 2001;48:588-91. [\[CrossRef\]](#)
8. Bajraktari G, Rexhepaj N, Bakalli A, Shaqiri G, Osmani E, Vokrri L, et al. Remission of high-output heart failure after surgical repair of 30-month arteriovenous femoral fistula: case report. *Heart Surg Forum* 2005;8:118-20. [\[CrossRef\]](#)