

# Non- Surgical Approach in a Case of Placenta Accreta Complicated by a Pulmonary Embolus

<sup>1</sup>Adnan Incebiyik, <sup>2</sup>Funda Yalcin, <sup>1</sup>Nese Gul Hilali, <sup>1</sup>Aysun Camuzcuoglu, <sup>1</sup>Hakan Camuzcuoglu, <sup>1</sup>Mehmet Vural

## ABSTRACT

*Placenta accreta, which is a serious complication of pregnancy that can be treated with a spectrum of treatment methods ranging from medical treatment to hysterectomy, is characterized by the abnormal adherence of the placental tissue to the uterine wall. The presence of a simultaneous pulmonary embolus necessitates more conservative treatment approaches due to anticoagulant treatment and limited lung capacity of the patient. In this case report, a case with these risk factors that was treated with alternative treatment methods rather than surgery is presented and these treatment options are discussed.*

**Key words:** Placenta accreta, pulmonary embolism, methotrexate, uterine balloon tamponade

## Pulmoner Emboli ile Komplike Olmuş Plasenta Akreata Vakasında Cerrahi Dışı Yaklaşım

### ÖZET

*Plasenta akreata, plasental dokunun uterin duvara anormal yapışması ile karakterize ve medikal tedaviden, histerektomiye kadar uzanan bir yelpazede tedavi edilebilen ciddi bir gebelik komplikasyonudur. Bu hastalıkla birlikte pulmoner embolinin olması ise hem antikoagülan tedavi hem de hastanın sınırlı akciğer kapasitesi nedeni ile daha konservatif tedavi seçeneklerine başvurmayı gerektirmektedir. Olgu sunumumuzda bu risk faktörlerine sahip bir hastada plasentasını yerinde bırakılarak uygulanan cerrahi alternatif yöntemler tartışılmıştır.*

**Anahtar kelimeler:** Placenta accreta, pulmoner emboli, methotrexate, uterine balon tamponat

## INTRODUCTION

Placenta accreta (PA) is a placental adhesion abnormality characterized by abnormal invasion of chorionic villi to the myometrium; its incidence has been gradually increasing due to the increasing rate of cesarean sections performed. PA is a life-threatening clinical condition associated with massive blood loss during childbirth. Prenatal diagnosis with imaging studies and planning the childbirth accordingly may help to decrease morbidity and mortality. A generally accepted method of treatment of this placenta adhesion abnormality is cesarean hysterectomy, while recently, uterus preservation surgery and conservative approaches have gained popularity in patients in whom fertility is desired to be

preserved (1, 2).

Many disorders may complicate the process of pregnancy. Among these, thromboembolic events are not rare in pregnancy. Besides, pregnancy itself increases the risk of development of these disorders. The risk of venous thromboembolism is 60 times greater in a post-partum woman compared to other women in the same age group. When pulmonary embolus (PE) is diagnosed in a patient, anticoagulation should be started immediately with heparin if the patient is pregnant and with warfarin if the patient is in the post-partum period, and should be continued for at least six weeks (3).

A case of a placental adhesion abnormality diagnosed

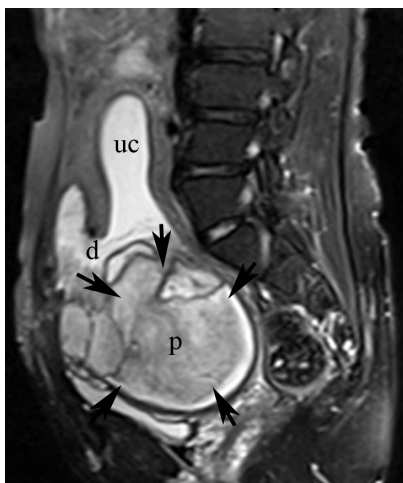
<sup>1</sup>Harran University Medical Faculty Gynecology and Obstetrics Clinic <sup>2</sup>Department of Chest Diseases, Harran University School of Medicine, Sanlıurfa, Turkey

**Correspondence:** Adnan Incebiyik, Harran University School of Medicine, Gynecology and Obstetrics Clinic, Yenisehir Campus, 63000, Sanlıurfa/Turkey, phone number: (0414) 3183027, facsimile: (0414) 3183192, E-mail: dr.aincebiyik@mynet.com

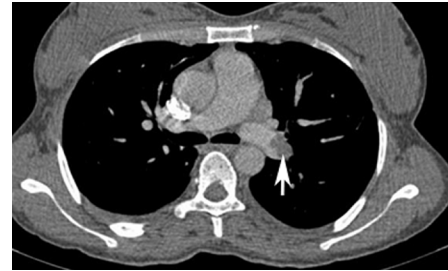
in a patient with the placenta left in place during a cesarean section is presented here and the difficulties in the treatment of placenta accreta due to anticoagulant treatment, which was given for the treatment of PE, are discussed.

### CASE

A 29-year-old pregnant patient with one previous cesarean section history (G3P2) delivered a baby by cesarean section in the 37th week of pregnancy due to fetal distress in emergency conditions. She was transferred to our hospital with the initial diagnosis of PE due to symptoms of dyspnea, tachycardia, and chest pain on the second postoperative day. The medical records revealed that during the operation, abnormal vascularization had been appreciated at the lower segment of uterus and hence the incision had been made from a more proximal place and baby had been delivered. Placental adhesion abnormality had been suspected and the fetal cord had been tied with the placenta left in place. Upon clinical examination, the patient was afebrile, blood pressure was 100/60 mm/Hg and pulse rate was 88 beats/minute. In the speculum examination, the cervix of the patient was compatible with postpartum period; however, the uterus was palpated to be larger than expected. An abdominal ultrasonography revealed an enlarged uterus and an intrauterine placental tissue with dimensions of



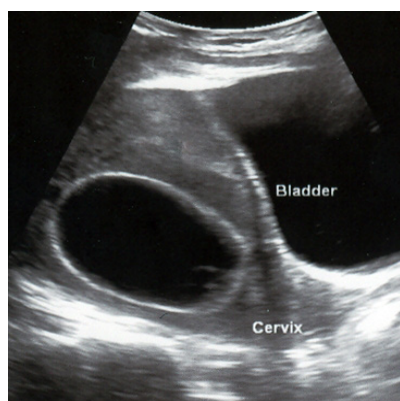
**Figure 1.** Magnetic resonance imaging of placenta accreta (uc: uterine cavity, d: dehiscence; p: placenta, the arrows identify the borders of the placenta)



**Figure 2.** The view of filling defect (white arrow) compatible with thrombus in left main pulmonary artery at the computed tomography angiography section

9 x 7 cm. Laboratory tests were in the normal ranges other than a hemoglobin level of 7.3 gr/dl. Two units of erythrocyte suspension were transfused for anemia and an amoxicillin-clavulanic acid and metronidazole combination was started prophylactically. The magnetic resonance imaging obtained to clarify the intrauterine mass seen in the ultrasonography revealed a placenta with an adherence anomaly (Figure 1).

The patient with dyspnea and chest pain was examined for a respiratory tract disorder, and hypocapnia and hypoxia were detected in the results of arterial blood gas tests. A view compatible with thrombi in the left main pulmonary artery and in its segmental branches (Figure 2) was detected in the computed tomography (CT) angiography, which was obtained with the suspicion of PE. PE was considered as non massive and hemodynamic variables were stable and no fibrinolytic treatment was planned. The patient was started on anticoagulant therapy with the diagnosis of PE (low molecular weight heparin (LMWH) twice daily 0.6 ml, warfarin 5 mg/daily). LMWH was stopped according to the coagulation test results (INR: 3.1) on the second day of anticoagulation treatment. Surgical intervention for PA was not considered since the patient had no active vaginal bleeding. Furthermore, the high morbidity and mortality risks of the patient due to the anticoagulant treatment she was on for PE, the limited lung capacity of the patient, and risk of hemorrhage were taken into account. On the sixth day of the anticoagulant therapy, intramuscular methotrexate (MTX) in a dose of 50 mg/m<sup>2</sup> weekly was started for the treatment of placenta retention. Five days after the second course of MTX treatment, due to vaginal bleeding, the placental tissue was manually excised under sedation anesthesia to stop the bleeding. After the procedure, the bleeding



**Figure 3.** The application of uterine balloon tamponade

continued. Therefore, a 22-gauge Foley catheter was placed in the uterus under ultrasonographic guidance and its balloon was gently inflated with 70 ml of saline (Figure 3). The active bleeding was observed to stop afterwards. A reservoir with a volume of 2000 ml capacity was placed at the distal end of the Foley to check the rate of bleeding. Two units of erythrocyte suspension were transfused since the hemoglobin of the patient decreased from 10.2 g/dl to 6.8 g/dl. To prevent recurrent bleeding, warfarin was excluded from the anticoagulant treatment that the patient was on. LMWH was restarted 12 hours after the operation. Pathological examination of the curettage material demonstrated necrotic placental pieces in a volume of approximately 700 ml. Following the uterine balloon tamponade (UBT) application, the daily amount of bleeding was no more than 100 ml. On the third day of UBT placement, the patient had active vaginal bleeding. LMWH treatment was stopped and a second Foley catheter was placed in the uterine cavity and the balloon of the catheter was inflated with 30 ml of saline. Inferior vena cava filter was not considered due to decreased caval diameter (11 mm) with ultrasonography and suspicion of bacteremia. After this maneuver the bleeding was observed to stop. Anticoagulant treatment with LMWH was started again 24 hours after the second UBT application since the patient had PE and vaginal bleeding ceased. Since no active bleeding was observed up to eight days after the intrauterine and intracervical catheter placements, the volume of the balloon of the Foley catheter was gradually decreased and was removed on the tenth day. Following this, warfarin treatment was started again and LMWH was stopped on the second day of warfarin

treatment. Anticoagulant therapy with warfarin was completed in six months without any complications.

## DISCUSSION

In this case report, the efficacy of UBT application in addition to MTX use in the treatment of placenta accreta in a patient who could not be operated on due to the anticoagulant therapy she was taking in a therapeutic dose was discussed. The diagnosis of PA is made by clinical suspicion and it is generally histopathologically confirmed. However, a lack of histopathological identification of PA signs does not always rule out the diagnosis of PA (4). Although there are not universally accepted methods, conservative methods of treatment can be used, such as preoperative internal iliac artery balloon catheterization and embolization, cesarean hysterectomy, and conservative surgery (excision of abnormal uterine wall and uterine reconstruction in focal placental adhesion anomalies). In addition to expectant management after keeping the placenta in place after childbirth as a uterine preserving method, uterine artery embolization, MTX treatment, placement of hemostatic sutures in uterus, uterine artery ligation and balloon tamponade use can also be considered (5, 6). MTX use is controversial in the treatment of invasive placentation. In addition to some authors that advocate that MTX use effectively prevents trophoblastic proliferation, there are some authors who defend that placental tissue mitosis stops after the fetus is born and thus MTX treatment is unnecessary. The latter authors suggest that in such patients with an especially high risk of infection, MTX use might be a risk factor for sepsis due to its immunosuppressive effects (7). In our case, MTX was used in the weekly dose regimen and no systemic infection sign was seen.

Placenta retention was present in this case due to placental adhesion abnormality. Major surgery was not considered in this patient since there was no active vaginal bleeding and she was on anticoagulant therapy for PE. On the sixth day of hospitalization, she was started on MTX treatment in a weekly dose for retained placenta since her general status was stable and there were no risks in terms of her PE status. In accordance with this case, Ramoni et al. also reported no major bleeding risks in two patients in whom they started weekly MTX treatment on the seventh day after a cesarean section in their series of four patients with placenta percreta.

On the other hand, they performed abdominal hysterectomy due to severe vaginal bleeding in the other two patients in whom they started MTX treatment in a dose of two or three times weekly starting on the second and third days after cesarean section (7).

UBT application in the treatment of postpartum hemorrhage has gained popularity recently. Its rapid and easy application is the major advantage. UBT application in the cessation of postpartum hemorrhage has been reported to be as effective as other conservative methods such as arterial embolization, iliac artery ligation, uterine devascularization, and uterine decompression suture; in addition, it is reported to be a safe method without negative effects on future fertility and pregnancy results (8). Although the exact mechanism of UBT in stopping the hemorrhage is unknown, providing an intrauterine pressure greater than systemic arterial pressure, the tamponade effect of the balloon on the area of bleeding and stimulation of uterine contractions by the balloon is among the suggested theories. Gronval et al., in three out of five patients with PA succeeded in stopping the bleeding using UBT after uterine curettages (4). In this case, as well, UBT was applied after the continuation of bleeding after the curettage was performed for retained placenta. Bleeding was seen to be effectively stopped after the placement of UBT. In our case, following recurrent bleeding on the third day of UBT application, a second Foley catheter was successfully placed in the cervical channel to stop the bleeding.

In UBT application, the catheter can be removed after it is certain that hemostasis is established and when bleeding ceases. Georgio reported in a literature review that UBT was used in periods ranging from 2 to 82 hours (9). In this case, since the patient was on anticoagulant therapy due to PE, intrauterine and cervical catheters were left in place for 11 and 8 days, respectively.

The aim of the long period of catheterization was to prevent the possible life-threatening risks owing to the limited lung capacity of the patient when required major surgical treatment. No complications due to long-term catheterization were present, such as infection, prevention of uterine involution, or complications due to compression. In conclusion, UBT, with its easy application, can be a lifesaving intervention in the treatment of possible uterine bleeding in patients with PA in whom surgical treatment is not selected as an option due to anticoagulant therapy that they are taking for PE.

#### REFERENCES

1. Oyelese Y, Smulian JC. Placenta previa, placenta accreta, and vasa previa. *Obstet Gynecol* 2006;107:927-41
2. Garmi G, Salim R. Epidemiology, etiology, diagnosis, and management of placenta accreta. *Obstet Gynecol Int* 2012; 2012: 873929
3. Middeldorp S. How I treat pregnancy-related venous thromboembolism. *Blood* 2011; 17; 118: 5394-400
4. Gronvall M, Tikkanen M, Tallberg E, Paavonen J, Stefanovic V. Use of Bakri balloon tamponade in the treatment of postpartum hemorrhage: A series of 50 cases from a tertiary teaching hospital. *Acta Obstet Gynecol Scand* 2013; 92: 433-8
5. Resnik R. Management of placenta accreta, increta, and percreta. *AJOG practice Bulletin* Mar 22, 2013
6. Ferrazzani S, Guariglia L, Triunfo S, Caforio L, Caruso A. Conservative management of placenta previa-accreta by prophylactic uterine arteries ligation and uterine tamponade. *Fetal Diagn Ther* 2009; 25: 400-3
7. Ramoni A, Strobl EM, Tiechl J, Ritter M, Marth C. Conservative management of abnormally invasive placenta: four case reports. *Acta Obstet Gynecol Scand* 2013; 92: 468-71
8. Cengiz H, Yasar L, Ekin M, Kaya C, Karakas S. Management of intractable postpartum haemorrhage in a tertiary center: A 5-year experience. *Niger Med J* 2012; 53: 85-8
9. Georgiou C. Balloon tamponade in the management of postpartum haemorrhage: a review. *BJOG* 2009; 116: 748-57