

Well-Differentiated Mucinous Cystadenocarcinoma of the Renal Pelvis

Fatma Cavide Sonmez¹, Hacı Hasan Esen², Lema Tavlı², Mehmet Kılınc³

ABSTRACT

Adenocarcinoma arising from renal pelvis is uncommon. A mucinous cystadenoma of the renal pelvis with malignant transformation is a rare entity. We report a case of well-differentiated mucinous cystadenocarcinoma of the renal pelvis with malignant transformation of cystadenoma with mucus-filled kidney (muconephrosis) due to mucin produced by the tumor.

Key words: Mucinous adenocarcinoma, malignant transformation, cystadenoma, renal pelvis

Renal Pelvisin İyi Diferansiye Müsinöz Kistadenokarsinomu

ÖZET

Renal pelvisten kaynaklanan adenokarsinom sık değildir. Malign transformasyon gösteren müsinöz kistadenom nadir bir antitedir. Tümörün müsin üretimine bağlı mukusla dolu böbreği (mukonefroz) olan, kistadenomdan malign transformasyon gösteren renal pelvisin iyi diferansiye kistadenokarsinomu olgusunu sunduk.

Anahtar kelimeler: Müsinöz adenokarsinom, malign dönüşüm, kistadenom, renal pelvis

INTRODUCTION

A cystadenoma or cystadenocarcinoma of renal pelvis is a rare neoplasm. A mucinous cystadenoma of the renal pelvis with malignant transformation is a relatively rare entity. Adenocarcinoma accounts for less than 1% of malignancies arising from renal pelvic epithelium. Spire et al. subclassified these tumors into three histologic types: tubulovillous, mucinous and papillary nonintestinal. Most reported cases are malignant (1-5). We report a case of well-differentiated mucinous cystadenocarcinoma of the renal pelvis with malignant transformation of cystadenoma. Mucus-filled kidney (muconephrosis) due to mucin produced by the tumor was detected.

CASE

A 67-year-old man presented with intermittent left flank pain during ten months and had swollen abdo-

men. There had been no other diagnosed malignancy especially about gastrointestinal system in his history before. The clinical diagnosis was hydronephrosis due to a cystic lesion as hydatid cyst. Left simple nephrectomy was performed with maintaining the integrity of cyst. The gross examination of the specimen revealed that this mucoid fluid was connected with cyst wall. There was only a huge unilocular cystic lesion measured 20x17,5x8 cm. Renal medulla, cortex and pelvicaliceal system were not obviously observed (Figure 1). The thickness of cyst wall was 0.1-1.5 cm. 2.7 cm diameter mucinous mass with villous structures was detected in an area of cyst lumina. No calculi were found. On histology, the cyst wall showed single or generally pseudostratified-layered, tall columnar mucinous epithelium with some goblet cells as intestinal epithelium. In the fibrocollagenous stroma, there were hemorrhage, necrosis, inflammatory infiltrate and acellular mucin

¹BezmiAlem Vakıf University, Faculty of Medicine, Department of Pathology, Istanbul, Turkey, ²Selçuk University, Meram School of Medicine, Department of Pathology, Konya, Turkey, ³Selçuk University, Meram School of Medicine, Department of Urology, Konya, Turkey

Correspondence: Fatma Cavide Sönmez, BezmiAlem Vakıf University, Faculty of Medicine, Department of Pathology, Istanbul/Turkey
Tel: +9 05053858327 Fax: +9 2124531700
e-mail: fcerden@yahoo.com

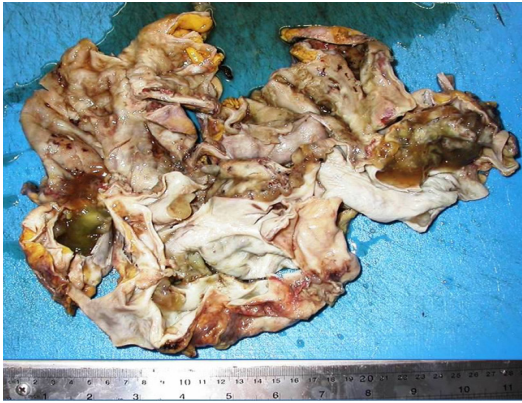

Figure 1. The huge, unilocular, mucinous cyst. Renal medulla, cortex and pelvicaliceal system are not obviously observed.

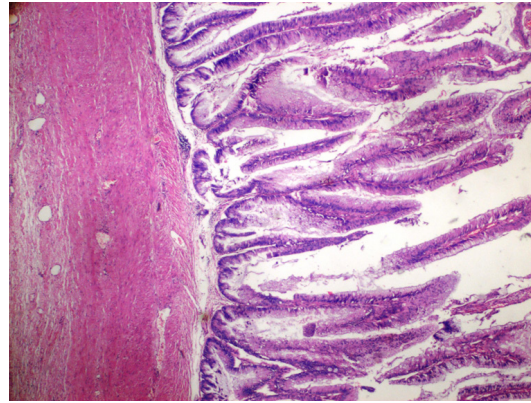


Figure 2. H&E X400-The cyst wall has pseudostratified-layered, tall columnar mucinous epithelium with nuclear atypia which formed villous structures.

pools. On the histopathological examination of the villous mucinous lesion, there were nuclear atypia and multilayering in mucinous epithelium which formed villous (Figure 2) and some cribriform structures on the surface. However, there was focally stromal invasion. A transition between transitional epithelium and intestinal epithelium was detected so we thought this tumor, which transformed from mucinous cystadenoma to well-differentiated mucinous cystadenocarcinoma, had arisen from renal pelvis. The ureter was not involved. The epithelium of this lesion showed both immunohistochemical Cytokeratin 7 (Figure 3) and 20 expression (Figure 4). He had no recurrence or metastasis during the 6-month follow up.

DISCUSSION

Adenocarcinoma arising from renal pelvis was first reported by Grohe in 1901 (6) and in 1973 Aufderheide and Streitz reported the first major review (2). Spire et al. reviewed 59 cases in 1993 which is the most recent review (4). Chronic infection, renal calculi and hydronephrosis were involved as possible aetiological factors in mucinous adenocarcinoma of the renal pelvis (4,7-8). The normal transitional epithelium can transform squamous, columnar, or cuboidal form with metaplasia.(9). Transitional or squamous carcinomas are more frequently seen. Conversion of transitional epithelium to colonic type epithelium is relatively rare. Gangane et al. be-

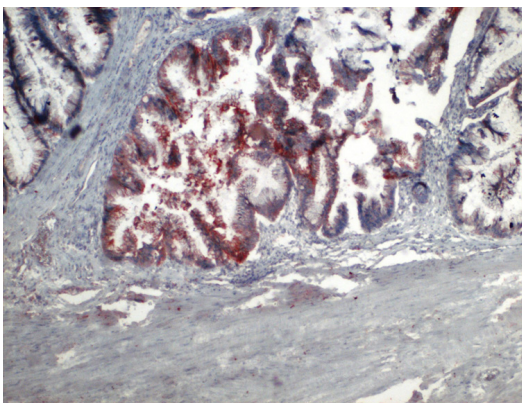


Figure 3. The epithelium shows immunohistochemical Cytokeratin 7 expression.

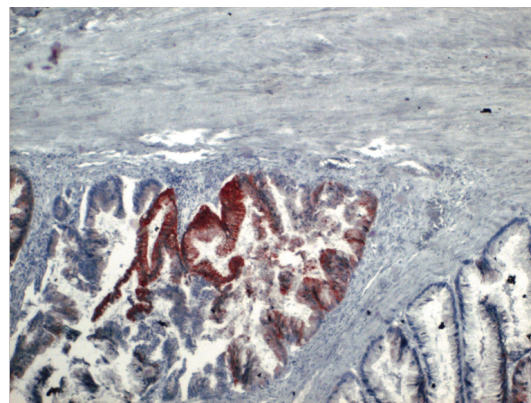


Figure 4. Immunohistochemical staining shows a positivity for Cytokeratin 20.

lieve that mucinous cystadenoma, like its malignant counterpart, arises from foci of intestinal metaplasia, and say that they were able to demonstrate histological transition from transitional epithelium to metaplastic mucinous areas in the same lesion (10). However, Park et al. reported a case of renal pelvic villous adenoma and diffuse intestinal metaplasia of the urothelium without gastrointestinal pathological findings (11). Kobayashi et al. have related the histogenesis adenocarcinoma to metaplasia of transitional cell carcinoma (7). There have been cases as mucinous cystadenoma of the renal pelvis with malignant transformation (2) as in our case, a mucin-producing cystadenoma, borderline malignancy of the renal pelvis and ureter (1), mucinous cystadenoma in a horseshoe kidney (12,13), intestinal type of villous adenoma (14) and mucinous adenocarcinoma of renal pelvis and villous adenoma of bladder after caecal augmentation of bladder (15).

Our case is a mucin-producing cystadenoma with malignant transformation without a history of long-standing chronic infection and renal stone, also there was no enteral communication and gastrointestinal pathology. There was hydronephrosis due to mucin secretion of tumor (muconephrosis). We have used the same criteria used for mucinous ovarian tumors for the diagnosis of malignancy. Ross and D'Amato (13) suggested that it might also be appropriate for mucinous tumors of the kidney

REFERENCES

1. Arakawa M, Jimi A, Ootomi M, Ooyabu Y, Samejima H. A mucin-producing cystadenoma, borderline malignancy, of the renal pelvis and ureter: a case report. *Gan No Rinsho* 1989; 35(4):499-504.
2. Mardi K, Sharma J, Mahajan P. Mucinous cystadenoma of the renal pelvis with malignant transformation: a case report. *Indian J Pathol Microbiol* 2006; 49(4):595-6
3. Ward AM. Glandular neoplasia within the urinary tract. The aetiology of adenocarcinoma of the urothelium with the review of the literature. *Virchows Arch A Pathol Anat* 1971; 352:296-311.
4. Spires SE, Banks ER, Cibull ML, et al. Adenocarcinoma of the pelvis. *Arch Pathol Lab Med* 1993; 117:1156-60
5. Aufderheide AC, Streitz JM. Mucinous adenocarcinoma of the renal pelvis. Report of two cases. *Cancer* 1974; 33:167-73
6. Grohe B. Unsere Nierentumoren in Therapeutischer, Klinischer and Pathologisch: Anatomischer Beleuchtung. *Dtsch Z Chir* 1901; 60:1-63
7. Kobayashi S, Ohmori M, Akaeda T, Ohmori H, Miyaji Y. Primary adenocarcinoma of the renal pelvis: Report of two cases and brief review of literature. *Acta Pathol Jpn* 1983;33:589-97.
8. Tepeler A, Erdem MR, Kurt O, et al. A rare renal epithelial tumor: mucinous cystadenocarcinoma case report and review of the literature. *Case Rep Med* 2011;2011:686283. doi: 10.1155/2011/686283.
9. Mostofi FK. Potentialities of bladder epithelium. *J Urol* 1954;71:705-14.
10. Gangane N, Anshu, Shende N, Sharma SM. Mucinous cystadenoma arising from renal pelvis: a report of 2 cases. *Urol J* 2008; 5(3):197-9.
11. Park S, Meng MV, Greenberg MS, Deng DY, Stoller ML. Muconephrosis. *Urology* 2002; 60(2):344.
12. Akan H, Dalva I, Yildiz O, Kutluay L, Gündoğdu S, Güngen Y. Mucinous cystadenoma mimicking simple renal parenchymal cyst in a horseshoe kidney. *Int J Urol* 2005; 12(5):493-6
13. Ross DG, D'Amato NA. Papillary mucinous cystadenoma of probable renal pelvic origin in a horseshoe kidney. *Arch Pathol Lab Med* 1985; 109:954-5.
14. Bos I, Lichtenauer HP, Frontzeck M. Intestinal type of villous adenoma of the kidney pelvis. *Pathologe* 1988; 9(2):109-14.
15. Yip SK, Wong MP, Cheung MC, Li JH. Mucinous adenocarcinoma of renal pelvis and villous adenoma of bladder after a caecal augmentation of bladder. *Aust N Z J Surg* 1999; 69(3):247-8.