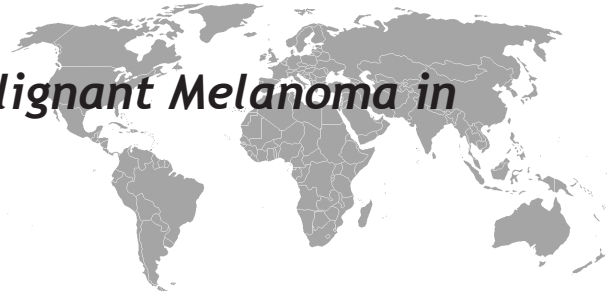

Extra-cutaneous Palatal Malignant Melanoma in Middle-aged Females



Modupeola Omotara Samaila

ABSTRACT

Malignant melanoma of the oral cavity is an uncommon aggressive tumour that preferentially affects elderly males. A twenty-one year (1991-2011) analysis of oral malignant melanoma cases were evaluated. The age range was 27-80 years with a mean of 49.8 years. Symptom duration ranged from 2 months to a year. Examination revealed ulcerated and bleeding grey to black tumours of varying sizes located predominantly in the hard palate in nine cases with lymph nodes (submandibular and cervical) enlargement. Palatal melanoma has a rapid growth rate and most patients present with advanced disease which has poorer prognosis. Its classification and treatment is still based on the cutaneous disease. Early disease is often asymptomatic thus awareness and knowledge of its biological behaviour by attending clinicians will aid prompt diagnosis and also reduce morbidity and mortality of this aggressive tumour.

Key words: Melanoma, extracutaneous, female, palate

Orta Yaş Kadınlarda Deri Haricindeki Damakta Gelişen Melanomalar

ÖZET

Ağız boşluğunun malign melanoması özellikle yaşlı erkekleri etkileyen nadir görülen bir agresiv tümördür. 21 yıllık ağız boşluğu malign melanoması değerlendirildi. Yaş aralığı 27-80 yıl ve ortalaması ise 49.8 idi. Semptom süresi 2 ay ile bir yıl arasında değişmekte idi. Muayenede lenf nodu genişlemesi olan 7 olguda sert damakta lokalize değişik ölçülerde ülserasyon ve kanama gösterdi. Damak melanomaları hızlı ilerleme ve çoğu hastalar daha kötü prognoz gösterirler. Sınıflandırma ve tedavisi halen deri melanomasına göre yapılmaktadır. Erken dönem hastalık sıklıkla asemptomatiktir. Bundan dolayı klinisyenlerin agresiv tümörün mortalite ve morbiditesini azaltması için bu hastalık hakkında bilgi düzeylerini artırması gerekmektedir.

Anahtar kelimeler: Melanom, ekstrakutenöz, kadın, damak

INTRODUCTION

Oral malignant melanoma (OMM) is a relatively rare aggressive tumour accounting for 1.6% of all head and neck malignancies. It also accounts for 0.2% to 0.8% and 0.5% of malignant melanoma (MM) and all oral malignancies respectively, while cutaneous MM accounts for 1% of all cancers globally with variable worldwide incidence rates (1,2). Oral melanoma (OM) is seen in elderly males and preferentially affects the hard palate, maxillary alveolar mucosa and gingiva (2-4). The precursor lesions of OM are unknown while MM originates from melanocytes and about 30% occur in pre-existing pigmented lesions (3,5-8). The pathological classification of oral melanoma is

still unclear while early disease is asymptomatic thus its diagnosis is often delayed and fraught with poor prognosis.

MATERIALS AND METHODS

This is a twenty-one year (1991-2011) analysis of all histologically confirmed oral cavity malignant melanoma cases diagnosed in the Department of Pathology, Ahmadu Bello University Teaching Hospital Shika, Zaria. All the tissue biopsies and maxillectomy specimens were fixed in 10% formalin and processed in paraffin wax. Histology sections were stained with haematoxylin and

Ahmadu Bello University Teaching Hospital, Department of Pathology, Zaria

Received: 05.09.2012, Accepted: 30.12.2012

Correspondence: Modupeola Omotara Samaila

Department of Pathology, Ahmadu Bello University Teaching Hospital Zaria

eosin. Where applicable, histology sections with heavy melanin pigments were bleached with hydrogen peroxide (H_2O_2), potassium permanganate ($KMnO_4$) and 1% oxalic acid to visualize tumour cell morphology. Presence of melanin pigment was confirmed using Masson Fontana stain.

RESULTS

A total of 107 malignant melanoma cases were diagnosed within the study period. Of these, seven females and three males had oral cavity tumours. The ages ranged from 27 years to 80 years with a mean of 49.8 years. They presented collectively with varying symptoms of painful bleeding gum, gum discolouration, palatal swelling, maxillary swelling, lower jaw swelling, black sessile oral mass, epistaxis, facial swelling and proptosis. The symptom duration was from 2 months to a year while one patient re-presented with disseminated disease a year later following initial incomplete tumour excision. Two patients gave a history of tooth extraction while the 80 year old elderly female was edentulous. None of the patients gave a positive history of previous oral lesions. All had poor oral hygiene and examination revealed left sided nodular masses in five cases, involving the anterior two-thirds of the hard palate (Figure 1), associated unprovoked bleeding gum and loosened teeth. One female had a 5 cm base sessile nodular mass extending to the inner aspect of the upper lip and one male had a

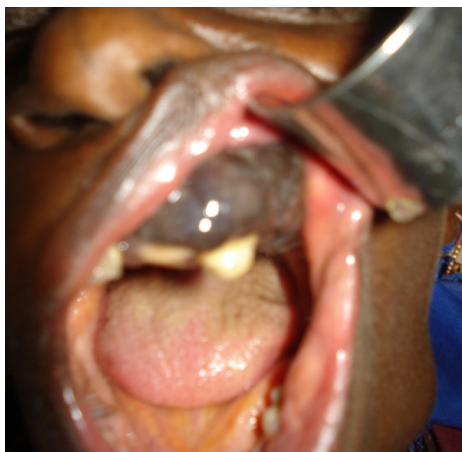

Figure 1. Left sided nodular masses, involving the anterior two-thirds of the hard palate

left mandibular ulcerated firm nodular mass. Two others had right sided maxillary masses pushing the globe up and outwards, with the mass extending to the posterior gingiva. While, the 53 year old man with disseminated disease had widespread palpable cervical, axillary and abdominal lymphadenopathy. In addition, submandibular nodal enlargement was demonstrable in five other cases. Palatal radiographs showed osteolytic lesions with destruction of the maxillary bone. Incisional tissue biopsies and nodal excisional biopsies taken were sent for histopathological diagnosis. One patient had hemi-maxillectomy and died before commencement of chemotherapy. Cut surfaces of the biopsies were grey to solid black and the resection margins of the hemi-maxillectomy showed tumour involvement. Histology sections from all submitted tissues and lymph nodes were similar and showed infiltrating sheets of malignant spindle cells having ovoid nuclei, each containing a prominent eosinophilic nucleolus and having moderate cytoplasm containing melanin pigment (Figure 2), with extensive melanin incontinence within the fibrous stroma.

DISCUSSION

Oral melanoma has a rapid growth rate and patients usually present in advanced stage of the disease with palpable mass or swelling, loosened teeth, bleeding and ulceration as seen in our cases (4). Early disease is often asymptomatic and precursor lesions of palatal melano-

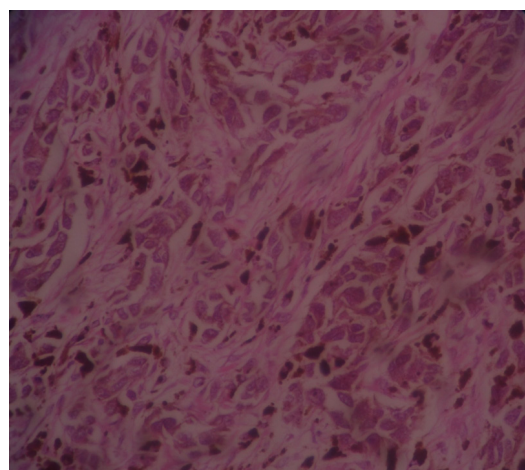


Figure 2. Infiltrating sheets of malignant spindle cells having ovoid nuclei, each containing a prominent eosinophilic nucleolus and having moderate cytoplasm containing melanin pigment

noma are largely unknown thus pigmented oral patches and pre-existing dysplastic lesions in the oral cavity should be monitored closely (9,10). Palatal melanoma, though uncommon, preferentially affects males aged 65 years and above (4). However, young and middle aged females were more affected in this study with only one female aged 80 years. All three males were younger than 65 years. This finding is supported by report of younger age of affectation in cutaneous melanoma in our setting (5). The pathological classification of OM is currently based on the cutaneous disease classification (3) as determined by a combination of the Breslow depth of the tumour, Clark level and clinical staging. The clinical staging criteria adopted by the American Joint Committee on Cancer are based on the localization of the tumour, size and lymph node metastasis (11).

All the cases were Clark level III and IV disease, extension into the subcutaneous tissue was difficult to determine due to the location of the tumours. The presence of even a solitary lymph node irrespective of the Breslow depth of tumour and Clark level confers a clinical stage III disease. Thus five of our cases had a Clark level IV and stage III disease while the patient with disseminated disease was a stage IV melanoma due to the widespread nodal and abdominal involvement. However, advanced regional or distant metastasis cannot be overlooked in the patients without palpable lymph node enlargement because melanoma has propensity for distant metastasis even in the absence of a discernible primary lesion. It is noteworthy that tumour thickness (Breslow depth) and level of invasion are also used to predict metastatic potential. Some authors have reported radiographic features with magnetic resonance imaging (MRI) and computerised tomography (CT) which may aid in the diagnosis of palatal melanoma (12). However, the gold standard of diagnosis remains tissue histology. The treatment of choice is surgery with wide and adequate resection margins as well as lymph node dissection with adjuvant chemotherapy with or without other therapies such as radiotherapy, immunotherapy and immune-modulatory agents (1,3,13,14).

The overall prognosis of MM depends on the tumour thickness, level of invasion and clinical stage of disease. However, tumour thickness is more accurate in determining prognosis and tumours greater than 1.5 mm in thickness have poorer survival rates. Other contributory prognostic factors are age, gender, genetic predisposition, degree of tumour ulceration and anatomical loca-

tion. Tumours located in the head and neck have poorer prognosis. The most important prognostic indicators for stage III disease are the number of metastatic nodes, anatomical location of tumour and presence of ulceration (11). Oral melanoma should be differentiated from other pigmented lesions of the oral cavity to forestall missed and delayed diagnosis thus, an awareness and knowledge of its biological behaviour by attending clinicians will aid early diagnosis as well reduce morbidity and mortality from this aggressive tumour.

REFERENCES

1. Bujas T, Pavic I, Prus A, Marusic Z, Balicevic D. Primary oral melanoma. A case report. *Acta Clin Croat* 2010; 49: 55-9.
2. Strauss JE, Strauss SI. Oral Malignant Melanoma: A case report and review of literature. *J Oral Maxillofacial Surg* 1994; 52: 972-6.
3. Hashemi Pour MS. Malignant melanoma of the oral cavity: a review of literature. *Indian J Dent Res* 2008; 19: 47-51.
4. Femiano F, Lanza A, Buonaiuto C, Gombos F, Di Spirito F, Cirillo N. Oral malignant melanoma: a review of the literature. *J Oral Pathol Med* 2008; 37:383-8.
5. Samaila MOA, Rafindadi AH. Pattern of Cutaneous Malignant Melanoma in Zaria, Nigeria. *Ann Afr Med* 2006; 5:16-9.
6. Umeda M, Komatsubara H, Shibuya Y, Yokoo S, Komori T. Premalignant melanocytic dysplasia and malignant melanoma of the oral mucosa. *Oral Oncol* 2002; 38: 714-22.
7. Clark WH Jr, Elder DE, Guerry DP, Epstein M.N, Greene M.H, Van Horn M. A study of tumor progression. The precursor lesions of superficial spreading and nodular melanoma. *Hum Pathol* 1984; 15:1147-65.
8. McGovern VS. The classification of melanoma and its relationship with prognosis. *Pathology* 1970; 2: 85-98.
9. Muller S. Melanin-associated pigmented lesions of the oral mucosa: presentation, differential diagnosis and treatment. *Dermatol Ther* 2010; 23: 220-9.
10. Powell JP, Cummings CW. Melanoma and the differential diagnosis of oral pigmented lesions. *Laryngoscope* 1978; 88: 1252-65.
11. Silberman AW. Malignant Melanoma. *Cedars- Sinai Comprehensive Cancer Center. Cancer News on the Net.*R
12. Uchiyama Y, Murakami S, Kawai T, Ishida T, Fuchihata H. Primary malignant melanoma in the oral mucosal membrane with metastasis in the cervical lymph node : MR Appearance. *Am J Neuroradiol* 1998; 19: 954-55.
13. Bartkowski SB, Panas M, Wilczanska H, Dubiel-Bigaj M. Primary Malignant Melanoma of the Oral Cavity. A review of 20 cases. *Am J Surg* 1984; 148:362-6.
14. McCaffrey TV, Neil HB, Gaffey TA. Malignant melanoma of the oral cavity: review of 10 cases. *Laryngoscope* 1980; 1329-35.