

Common Late-Onset Subcortical Cerebral Hemorrhage Following Excessive Alcohol Consumption

Ali Kemal Sivriođlu¹, Murat Veliođlu², Mehmet İncedayı², Serkan Arıbal², Güner Sönmez², Çınar Başhekim²

ABSTRACT

50 year old male patient who was suffering from cooperation disorder and bilaterally blindness was admitted to our emergency service. He was addicted to alcohol and had excessive alcohol consumption the day before. Cranial nonenhanced CT was normal. T2 weighed MR imaging performed at 1,5 T unit showed high signal intensity in bilateral putaminal foci. In this localization diffusion-weighted images (DWI) were hyperintense due to restricted diffusion and low ADC values. After two weeks, drowsiness and confusion were appeared suddenly. Cranial nonenhanced CT was showed extensive subcortical white matter and basal ganglia abnormalities consistent with edema and hemorrhagic changes. The patient was transferred to intensive care unit and died after one day. In methanol intoxication, cerebral and intraventricular hemorrhage, cerebellar necrosis, diffuse cerebral edema, bilateral subcortical white matter necrosis and edema were defined. It should also be known that 2 or 3 weeks after ingestion of methyl alcohol, the deterioration of the patient's general situation is responsible for cerebral subcortical hemorrhage. We have also thought that patients' mortality and morbidity can be reduced with radiological imaging due to early diagnosis.

Key words: Cerebral subcortical hemorrhage, CT, methanol intoxication, MRI

Aşırı Alkol Alımı Sonrasında Geç Dönemde Gelişen Yaygın Serebral Subkortikal Hemorajiler

ÖZET

Bilateral körlük ve kooperasyon bozukluğu olan 50 yaşındaki erkek hasta acil servisimize başvurdu. Olgu, alkol bağımlısıydı ve bir gün öncesinde aşırı alkol tüketimi mevcuttu. Yapılan kontrastsız kranial BT incelemesi normaldi. 1,5T MR cihazında yapılan T2 ağırlıklı görüntüleme, bilateral putamen lokalizasyonunda yüksek sinyal intensitesi izlendi. Difüzyon ağırlıklı görüntülerde bu lokalizasyonlarda, difüzyon kısıtlılığı nedeniyle hiperintensiteler ve düşük ADC değerleri mevcuttu. İki hafta sonrasında hastada, aniden baş dönmesi ve konfüzyon ortaya çıktı. Yapılan kontrastsız kranial BT'de, bazal ganglionlarda ve yaygın subkortikal beyaz cevherde ödem ve hemoraji izlendi. Hasta yoğun bakım ünitesine alındı ve bir gün sonra öldü. Metanol intoksikasyonunda, serebral ve intraventriküler hemoraji, serebral ödem, bilateral subkortikal beyaz madde nekrozu görülebilir. Metil alkol alımın takiben 2-3 hafta sonrasında ani genel durum bozukluğundan serebral subkortikal hemoraji sorumludur. Erken teşhis nedeniyle radyolojik görüntülemenin, hastanın mortalite ve morbiditesini azaltabileceğini düşünmekteyiz.

Anahtar kelimeler: Serebral subkortikal kanama, BT, metanol zehirlenmesi, MR

INTRODUCTION

While methyl alcohol poisoning appears after usage of liquor and cologne which are produced illegally, chronic poisoning is the result of inhaling smoke in workplaces. Clinical symptoms usually appear within 12-24 hours. Radiologic findings of methanol poisoning were described in the literature, these are hemorrhage, edema, necrosis

and atrophy. In methanol intoxication bilateral putamen necrosis, with or without hemorrhage, is the most common imaging finding. In methanol intoxication, cerebral and intraventricular hemorrhage, cerebellar necrosis, diffuse cerebral edema, bilateral subcortical white matter necrosis and edema were defined (1). We report a case with common late-onset subcortical cerebral hemorrhage following excessive alcohol consumption.

¹Aksaz Military Hospital, ²GATA Haydarpaşa Teaching Hospital

Received: 29.02.2012, Accepted: 10.03.2012

Correspondence: Aksaz Military Hospital

CASE

50 year old male patient who was suffering from cooperation disorder and bilaterally blindness was admitted to our emergency service. He was addicted to alcohol and had excessive alcohol consumption the day before. Blood gases and metabolic values were checked and significant metabolic acidosis (blood pH:6.8) was found, through emergency doctor's suspicion of alcohol intoxication. Cranial nonenhanced CT was normal. T2 weighted MR imaging performed at 1,5 T unit showed high signal intensity in bilateral putaminal foci. In this localization diffusion-weighted images (DWI) were hyperintense due to restricted diffusion and low ADC values. Asymmetric high signal was also found in the left optic nerve in DWI. The patient's blood ethyl alcohol level was higher than the normal values. It was thought that methyl alcohol and ethyl alcohol was consumed at the same time. Then, the patient was dialysed. After dialyses treatment, his general situation was improved. On the second weeks, drowsiness and confusion were appeared suddenly. His blood pressure was 200/140 mmHg and his PTZ and aPTT levels were normal. Cranial nonenhanced CT was showed extensive subcortical white matter and basal ganglia abnormalities consistent with edema and hemorrhagic changes. In addition to obliteration in interpeduncular and ambiens cisternas there were minimal midline shift to the left due to increased intracranial pressure. The patient was transferred to intensive care unit and died after one day.

DISCUSSION

While methyl alcohol poisoning appears after usage of liquor and cologne which are produced illegally, chronic poisoning is the result of inhaling smoke in workplaces. After getting into the liver by blood flow; Methyl alcohol is slowly converted to formaldehyde with the dehydrogenase enzyme and after it is converted to formic acid by the aldehyde dehydrogenase enzyme. This conversion is 5-10 times more slower compared to ethyl alcohol. Slow ravage leads to accumulation of methyl alcohol in the organism. Methyl alcohol, is harmless and has an intoxicating effect, when it is converted in vivo (1). Clinical symptoms usually appear within 12-24 hours. Signs and symptoms of poisoning may contain nausea, vomiting, headache, dizziness, blurred vision and blindness. Respiratory failure due to metabolic acidosis and finally coma status can be seen. After ingestion, ethanol reaches

the peak level in the blood after 30-60 minutes. Ethanol has an depressant effect in the CNS directly. It makes impact like a substance which contains very high anesthetic doses and may cause autonomic dysfunction (hypothermia and hypotension), coma, respiratory and cardiac depression. Our case had complaints of sudden onset of blindness and had smell of alcohol when presented to emergency service. This situation warned the emergency doctor about methyl alcohol poisoning. Due to lack of sufficient co-operation, it is very hard to take a true history from these ones efficiently. Patient's story can be learned from his relatives but this information may not be lead to diagnosis. In this situation, like our case, even levels of methyl alcohol may not be searched, radiologic findings can be diagnosed and quick treatment planning can be done. Radiologic findings of methanol poisoning were described in the literature. these are hemorrhage (2), edema, necrosis and atrophy. In methanol intoxication bilateral putamen necrosis, with or without hemorrhage, is the most common imaging finding. It isn't clear that why these regions are affected. Bilateral putaminal necrosis is not specific to methanol toxicity and can also be seen in Wilson's disease, Leigh's disease, Kearns-Sayre syndrome and striatal degeneration associated with Leber's optic atrophy (3). Radiological findings are also similar to carbon monoxide intoxication and hypoxic/anoxic injuries. However, in carbon monoxide poisoning, the specific focus of toxicity is the globus pallidus and hypoxic/anoxic injuries involve the caudate nucleus and other basal ganglia. In methanol intoxication, cerebral and intraventricu-

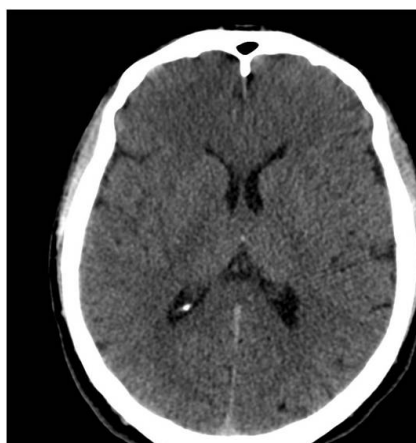


Figure 1. Patient's first nonenhanced CT was normal when he was presented to the emergency service.

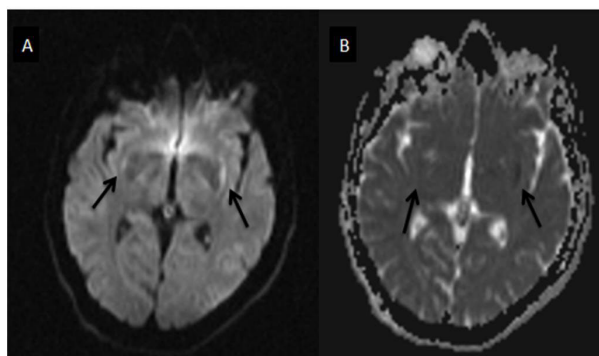


Figure 2. Diffusion weighted images (DWI) shows (a) hyperintensity on DWI images and (b) hypointense appearance on ADC images in both lateral putaminal areas due to restricted diffusion (arrows).

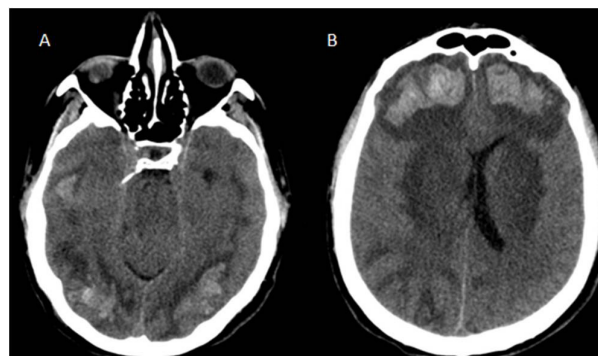


Figure 3. The latest nonenhanced CT shows subcortical hemorrhages (A) in the parietooccipital and (B) frontal regions.

lar hemorrhage, cerebellar necrosis, diffuse cerebral edema, bilateral subcortical white matter necrosis and edema were defined (4). Probably, injuries occur due to cerebral microvascular anatomy and direct toxic effects of methanol metabolites. It has been reported that peripheral white matter which has association fiber is protected although changes in white matter affect the subcortical areas (5). Peripheral enhancement was also displayed in the subcortical area and bilateral putamen due to breakdown of the blood-brain-barrier. Deniz reported that bilateral putaminal hyperintensity was seen on DWI with decreased ADC values (6). Likewise, while there aren't apparent findings on cranial CT in the early period, there are bilateral putaminal hyperintensities on diffusion-weighted images with the value of ADC decreased. In addition, 3 weeks after ingestion of methanol was showed prominent diffusion limitation in occipital lobes by Server et al in literature. A possible factor contributing to the diffusion abnormalities is that the accumulation of formic acid has been shown to be responsible for the production of metabolic acidosis and inhibition of cytochrome oxidase. It's also expected that the formic acid produces a failure of the Na/K ATPase pump. As a result, the cytotoxic edema and a reduction in ADC values occur. Our case's general condition worsened on the second week. Nonenhanced CT scans showed that there were more prominent subcortical hemorrhage in the frontal and occipital lobes on time. This situation which was reported to 14% case of methanol poisoning indicates a poor prognosis. Diffuse subcortical hemorrhage focus occur earlier than 3 weeks when reported in the literature. It was reported that there may be hemorrhagic transforma-

tion in the area of hemorrhage and necrosis depending on the heparinization during hemolysis (7). In our case, 2 weeks after ingestion of methanol, when the patient was presented to the emergency department, parenchymal hemorrhage depending on the heparinization wasn't diagnosed because the value of PTZ and APTT was normal. Because the methanol and metabolites must be removed from the blood the patient is treated with emergency hemodialysis procedure. Also ethyl alcohol and fomepizole, which are the competitive inhibitors of the dehydrogenase enzyme, can be used to reduce the formation of toxic formic acid. As a result; We have thought that cranial CT and diffusion weighted magnetic resonance image which has recently been more popular, have an important place in the acute methyl alcohol intoxication which causes severe ocular and central nervous system damage. We have also thought that patients' mortality and morbidity can be reduced with radiological imaging due to early diagnosis and treatment. It should also be known that 2 or 3 weeks after ingestion of methyl alcohol, the deterioration of the patient's general situation is responsible for cerebral subcortical hemorrhage.

REFERENCES

1. Wyngaardcn JB, Smith LU, Bcnnt SC. Cecil textbook of medicine. Philadelphia, Saunders 1992:113.
2. Phang PT, Passcrini L, Mielke B et al. Brain hemorrhage associated with methanol poisoning. Crit Care Med 1988; 16:137-40.
3. Koopmans RA, Li DKB, Paty DW. Basal ganglia lesions in methanol poisoning: MR appearance. J Comput Assist Tomogr 1988;12:168-9.

4. Kuteifan K, Oesterle H, Tajahmady T, et al. Necrosis and haemorrhage of the putamen in methanol poisoning shown on MRI. *Neuroradiology* 1998;40:158-60.
5. Server A, Hovada K.E, Nakstad P. Hj, Conventional and Diffusion - Weighted MRI in the Evaluation of Methanol Poisoning, A Case Report. *Acta Radiologica* 2003;44:691-5.
6. Deniz S, Oppenheim C, Lehericy S, et al. Diffusion-weighted magnetic resonance imaging in a case of methanol intoxication. *Neurotoxicology* 2000; 21: 405-8.
7. Glazer M, Dross P. Necrosis of the putamen caused by methanol intoxication:MR findings. *AJR* 1993;160:1105-6.