

Gastro-Bronchial Fistula in the Long-Term Follow-up of Operated Case with Esophageal Carcinoma

Erdal Yekeler¹, Hakki Ulutas², Bayram Altuntas³

ABSTRACT

The development of a fistula between the gastric tube and the bronchial system represents a very rare but potentially catastrophic complication after intrathoracic esophagogastronomy for esophageal carcinoma. A 67-years-old male patient, who underwent Ivor-Lewis surgery due to esophageal carcinoma six years ago, had persistence of complaints especially to increased cough immediately after food intake.

Keywords: Esophageal Carcinoma, gastro-bronchial fistula, complication.

Özofagus Cerrahisi Sonrası Uzun Dönem Takibinde, Özofago-Bronşial Fistülün Gelişmesi

ÖZET

Özofagus kanseri için yapılan intratorasik özofago-gastrik anastomoz sonrasında, tüpeştirilmiş mide ile bronşial sistem arasındaki fistül gelişimi, çok nadir fakat hayatı tehdit edici bir komplikasyondur. Özofagus kanseri nedeniyle altı yıl önce Ivor-Lewis operasyonu geçiren 67 yaşında erkek hasta, özellikle gıdaları aldıktan hemen sonra görülen dirençli öksürük şikâyeti ile müracaat etti.

Anahtar Kelimeler: Özofagus Kanseri, gastro-bronşial fistül, komplikasyon.

A 67-years-old male patient, who underwent Ivor-Lewis surgery due to esophageal carcinoma 6 years ago, had cough, sputum, fever, weight loss and malaise for the last 2 months. Due to the persistence of complaints, especially to increased cough immediately after food intake, the subject who has been treated for pneumonia in another center with these findings was admitted to our hospital. Most remarkable findings in chest X-ray were pneumonic infiltrations in right lower and middle lobes (Figure-1A). In thoracic CT, right middle and lower lobes and the image of dilated stomach transposed to thorax showed severely pneumonic consolidated fields (Figure-1B). His bronchoscopy didn't reveal any evidence other than purulent secretion originating from right lower lobe. Due to gradually increased cough after food intake, patient was administered gastroesophagoscopy; esophagus and anas-

tomotic lines were normal and without tumor. Gastric examination showed a fistular opening with uniform margins and without macroscopic tumoral evidence in the right posterolateral wall (Figure-2A). Biopsy of this area was tumor-negative. In the subject who was diagnosed with gastroparenchymal fistula based on these findings, the stomach was decompressed using a nasogastric catheter, oral intake was discontinued, antibiotic therapy was initiated and surgery was scheduled for 2 weeks later, when infectious parameters would be regressed. Right rethoracotomy was performed, and after the release of severely attached lung, the stomach was visualized from posterior mediastinum. We found that the stomach was shrunk on posterolateral wall, in the point where it was strongly attached to thoracic wall and gastric wall was too thinned that it was fistulized to pulmonary parenchyma. During

¹Ataturk Chest Diseases and Thoracic Surgery Training and Research Hospital, Department of Thoracic Surgery, Ankara, ²University of Inonu, School of Medicine, Department of Thoracic Surgery, Malatya, ³Erzurum Region Teaching and Research Hospital, Department of Thoracic Surgery, Erzurum, Turkey.

Correspondence: Dr.Erdal Yekeler
Osmangazi mah. 230 sok. Taner Apt. B-Blok No: 4 Yıldızkent Palandoken 25070
Erzurum-Turkey.
Tel:+905326761759, Fax: +90 312 3552135
E-mail address: drerdalyekeler@hotmail.com

Received: 24.01.2012, Accepted: 24.04.2012

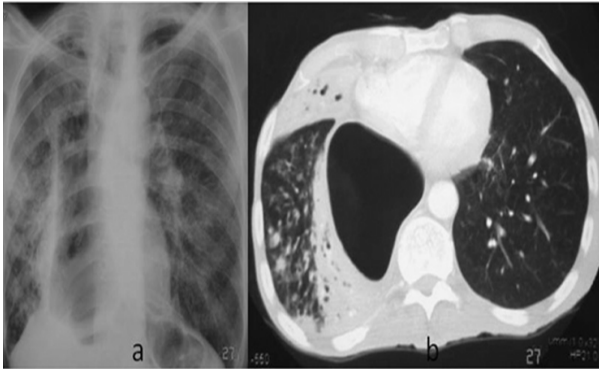


Figure 1. A) In the chest X-ray of the case, pneumonic infiltrations are seen in right middle and lower zones. B) In thoracic CT, right hemithorax shows serious pneumonic consolidated fields in the dilated stomach and surrounding pulmonary parenchyma.

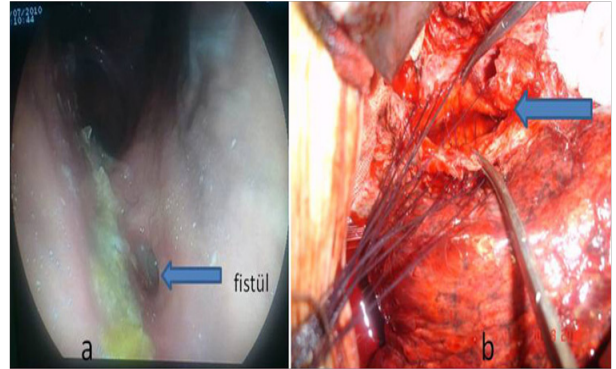


Figure 2. A) In the endoscopic examination, a fistular opening in the right postero-lateral wall of the stomach, without the macroscopic presence of the tumor (arrow) B) Intraoperative appearance

the dissection of this point, we detected non-absorbable sutures placed to fixate the stomach to thoracic wall. This part of the stomach was dissected and closed via primary repair by resection (Figure-2B). In our previous practices of Ivor-Lewis surgery, we have fixed the stomach to thoracic wall via non-absorbable sutures to prevent the early post-operative dilation of the stomach and its distension at anastomosis due to excessive food. Based on this procedure that we left later, we presented here rare, long-term complication due to esophageal carcinoma surgery and its therapeutic management (1,2).

REFERENCES

1. Martin-Smith JD, Larkin JO, O'Connell F, Ravi N, Reynolds JV. Management of gastro-bronchial fistula complicating a subtotal esophagectomy: a case report. *BMC Surg* 2009;24(9):20. doi: 10.1186/1471-2482-9-20.
2. Bona D, Sarli D, Saino G, Quarenghi M, Bonavina L. Successful conservative management of benign gastro-bronchial fistula after intrathoracic esophagogastrotomy. *Ann Thorac Surg* 2007;84(3):1036-8.