

Surgical Modalities in Maxillo-Facial Fractures: Retrospective Analysis of 110 Patients

Cemal Fırat¹, Ömer Elmas², Ahmet Hamdi Aytekin², Yılmaz Geyik², Serkan Erbatır²

ABSTRACT

The objective of this study is to carry out a retrospective analysis of patients in our clinic who underwent surgery for maxillofacial trauma. The retrospective analysis was carried out on data of 110 inpatients with maxillofacial trauma that were treated. The distribution of maxillofacial traumas according to facial bones (maxilla, zygoma, orbita, mandibular, and nasal) was examined. Multi-fragmented fractures of the maxilla anterior wall, orbital base fractures and isolated zygomatic arch fractures were treated with a balloon treatment method by Foley catheter. A total of 161 fracture were treated that 82 (74.54 %) were male and 28 (25.45 %) were female. Of these patients, 11 (10%) were in the pediatric age group (0-16). The etiology of maxillofacial traumas was examined, as 45 cases were traffic accidents, 32 cases were blows, 30 cases were falling, and 3 were firearm injuries respectively. The anatomic localizations of the maxillofacial fracture were 68 (42.23%) mandibula, 36 (22.36%) maxilla fractures, 21 (13.04%) zygoma fractures, and 26 (16.14%) orbita fractures (naso-orbital or naso-orbito-etmoidal fractures were included). Maxilla fractures were most frequently observed with other facial fractures. Zygoma fractures were also generally observed together with multi-fragmented fractures. The balloon treatment was found very effective to stabilize of multi-fragmented fractures of the maxilla anterior wall, orbita base fractures and zygomatic arch fractures. Since maxillofacial fractures may be seen in many patients who apply to hospitals due to traumas, sufficient experience of doctors working in this field is an important factor in decreasing mortality and morbidity. The most frequent patients are males aged 30 to 40 with maxillofacial trauma caused by a traffic accident, a sports accident, or a blow. Retrospective or epidemiological studies similar to our study are very beneficial for the determination of risk groups, specific precautions, and practical and effective treatment methods.

Key words: Maxilla-facial fractures, trauma, surgery, balloon treatment

Maksillo-Fasiyal Kırıklarda Cerrahi Yaklaşımlarımız: 110 Hastanın Geriye Dönük Değerlendirilmesi

ÖZET

Bu çalışmada amacımız kliniğimizde maksillo-fasiyal travma nedeniyle opere edilen hastaların geriye dönük olarak değerlendirilmesidir. Maksillo-fasiyal travmaların yüz kemiklerine (maksilla, zigoma, orbita, mandibula, nazal) göre dağılımını incelendi. Maksilla ön duvarındaki çok parçalı kırıklarda, orbita taban kırıklarında ve zigomatik ark kırıklarında foley sonda ile balon tedavisi uygulandı. 110 maksillo-fasiyal travmalı hastada toplam 161 kırık onarımı yapılan hastalardan 82'si (%74.54) erkek, 28'u (% 25.45) kadın idi. Bu hastalardan 11'i (%10) pediatrik yaş (0-16) grubundaydı. Maksillo-fasiyal travmalı 45 hastanın trafik kazası, 32 hastanın darp, 30 hastanın düşme, 3 hastanın da ateşli silah yaralanması olduğu saptandı. 161 maksillo-fasiyal kırık arasında en sık görülen anatomik lokalizasyonlar, mandibula 68 (%42,23), maksilla kırıkları 36 (%22.36), zigoma kırıkları 21 (%13.04), orbita kırıkları (nazo-orbital veya nazo-orbito-etmoidal kırıklar dahil) 26 (%16.14) idi. Maksilla kırıkları çoğunlukla diğer yüz kırıkları ile birliktelik göstermekteydi. Zigoma kırıkları da genellikle çoklu kırıklarla birlikteydi. Balon tedavisi çok parçalı maksilla ön duvar kırıklarında, orbita taban kırıklarında ve zigomatik ark kırıklarında oldukça etkili bir stabilizasyon sağladığı görüldü. Travma nedeniyle başvuran hastaların büyük çoğunluğunda maksillo-fasiyal travmalar da eşlik edebildiğinden bu alanda uğraşan hekimlerin yeterli donanıma ve tecrübeye sahip olmaları mortalite ve morbiditeyi azaltan en önemli unsurdur. En sık karşılaşılabilecek hasta profili ise 30-40 yaşlarında ya trafik kazası ya da spor veya darp nedeniyle maksillo-fasiyal travmaya uğramış bir erkek hasta olacaktır. Yaptığımız bu çalışmaya benzeyen retrospektif veya epidemiyolojik çalışmalar risk gruplarının belirlenmesi, spesifik önlemlerin alınması, tedavide pratik ve etkin metotlarının belirlenmesi amacıyla oldukça faydalıdır.

Anahtar kelimeler: Maksillo-fasiyal kırıklar, travma, cerrahi, balon tedavisi

¹Inonu University School of Medicine, Department of Plastic and Reconstructive Surgery, Assistant Professor, Malatya, Turkey, ²Inonu University School of Medicine, Department of Plastic and Reconstructive Surgery, Resident, Malatya, Turkey

Received: 20.04.2012, Accepted: 24.04.2012

Correspondence: Cemal Fırat, MD
Inonu University School of Medicine, Turgut Ozal Medical Center Department of Plastic, Reconstructive and Aesthetic Surgery, 44280 Malatya, Turkey
Tel: +904223410660/5505, Fax: +904223410728
E-Mail: cemal.firat@inonu.edu.tr, cemalfiratmd@gmail.com

INTRODUCTION

Maxillofacial traumas are an important field of study in plastic and reconstructive surgery, which comprises a large portion of general body traumas. Maxillofacial traumas are complex injuries involving facial bone injuries, soft tissue injuries, and dento-alveolar injuries (1). Etiological factors are frequently traffic accidents, falling from heights, blows, occupational and sports injuries, which vary according to gender, regional, and cultural differences. The treatment of maxillofacial traumas continues to evolve because of developments in imaging methods, bone fixation technology, microsurgery, reconstruction methods, and distraction osteogenesis. Although the basic principles of surgical treatment for maxillofacial fractures and fixation have changed only slightly, the application of these principles has become easier because of developments in surgical tools and osteosynthesis technology. Studies have shown that edema, ecchymosis, haemorrhage, pain or loss of sense in patients due to maxillofacial traumas and visual impairment may arise in traumas that include orbita (1-5). Maxillofacial traumas can cause soft tissue lacerations, nerve damage, vascular lacerations as well as damage to the lachrymal duct, salivary gland, or salivary gland ducts. These traumas can cause other serious problems, such as airway obstruction or massive bleeding, which can result in death (2,3). Thus, surgical expertise is required to treat complicated cases of maxillofacial traumas. Currently, facial trauma is still treated by various specialists, such as plastic surgeons, otolaryngologists, and maxillofacial surgeons. An archive of long-term follow-ups of patients with maxillofacial trauma is important for the development of treatment methods and preventive measures (3-5). The objective of this study is to carry out a retrospective analysis of patients in our clinic who underwent surgery for maxillofacial trauma from January 2009 to December 2012.

MATERIAL AND METHODS

The retrospective analysis was carried out on data of 110 inpatients with maxillofacial trauma that were treated at the Inonu University Turgut Özal Medical Center Plastic Reconstructive and Aesthetic Surgery Clinic from 2009 to 2012. The patients were evaluated in terms of distribution and applied treatment methods according to age, gender, etiology, and the structures affected by the trauma. The most frequent reasons for maxillofacial trauma were considered during the exami-

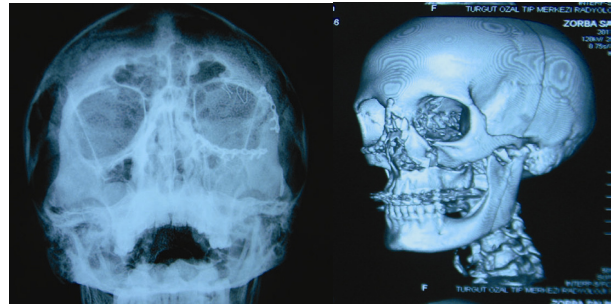

Figure 1. (a): Postoperative plain graph of tripod fracture of zygoma, (b): View of naso-orbito-maxillary fracture in 3-D computerized tomography

nation of etiological causes, and a distribution of traffic accidents, blows, falling, and other etiology (e.g., sports, occupational injuries, firearm injuries, etc.) was made. The distribution of maxillofacial traumas according to facial bones (maxilla, zygoma, orbita, mandibular, and nasal) was examined. When the number and type of bone fractures were evaluated, each affected bone in patients with fractures in more than one facial bone was evaluated as separate cases. Thus, a detailed distribution of bones affected by traumas was compiled (Table 1). Since the treatment of isolated soft tissue lacerations and isolated nasal fractures was carried out under local anaesthesia in emergency conditions, they were not included in the study. First, physical inspec-

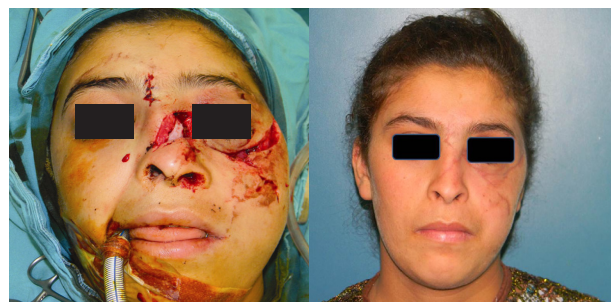

Figure 2. (a): Naso-orbito-etmoidal fracture + maxillo-zigomatic fracture with deep crush lacerations after a traffic accident, (b): postoperative view the patient whose fractures were repaired with balloon treatment.

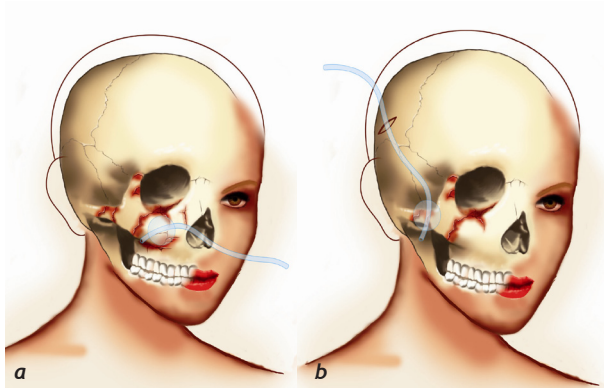


Figure 3. a: Correction of complex maxillo-zigomatic fracture balloon technique, schematically. b: Treatment of zygomatic arch fracture with balloon technique, schematically.

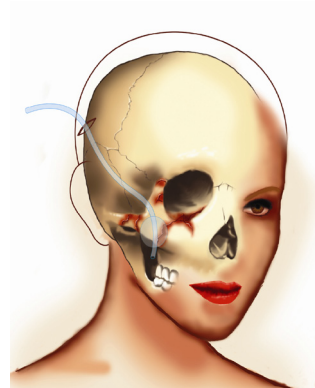

Figure 5. Correction of zygomatic body displacement with balloon technique, schematically.

tion was carried out for the diagnosis of maxillofacial trauma. Crepitation, sensitivity, and occlusion disorders were carefully evaluated during the physical inspection. Following the physical inspection, direct graphs and computerized tomography (CT) were taken where required (Figure 1a, 1b). If the general condition of the patient was suitable, bone reduction and fixation with plates (open reduction internal fixation) was carried out as soon as possible (Figure 2a, 2b). In addition, mandibular fractures were evaluated according to the localization of the fracture line (Table 2). If the general condition of the patient was not suitable, and if there was severe edema on the patient's face, surgery

was postponed until the edema passed. Osteosynthesis with internal fixation via a titanium mini-plate system under general anaesthesia was provided in suitable general conditions to patients who had upper or lower mandibular fractures. Maxilla-mandibular fixation was applied with an arch bar if the patient had a proper dental structure. All patients were given povidone iodine mouthwash, antibiotics, and analgesic. For patients on whom maxilla-mandibular fixation with an arch bar was applied, the arch bar was kept in place from two to six weeks according to the status and localization of the fracture. Mouth exercises were started at the end of the treatment. A Foley catheter was placed inside the maxillary sinus for multi-fragmented fractures of the maxilla anterior wall and orbita base fractures (Figure 3a). In zygomatic arch fractures, it was placed under

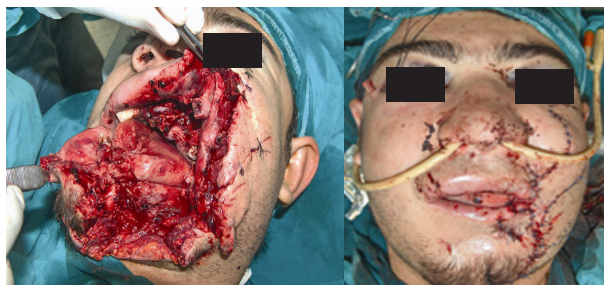

Figure 4. (a): Panfacial fracture after gun-shot injury, (b): Balloon treatment after panfacial fracture because of gun-shot injury.

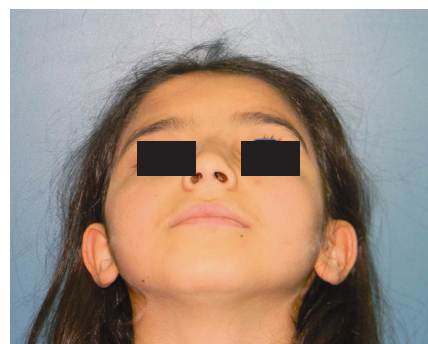

Figure 6. Insufficient correction of zygomatic displacement causes enophthalmus.

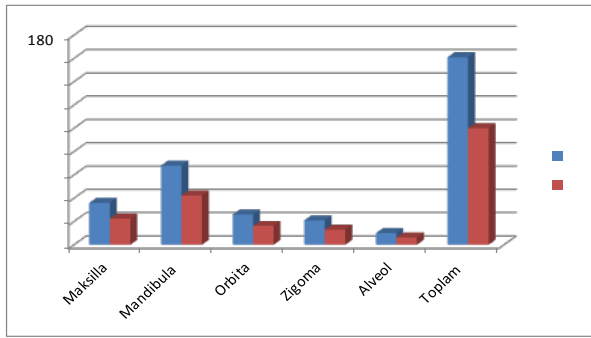


Figure 7. Distribution of maxillo-facial fractures

the arch following reduction, after which it was blown up with normal saline and kept in place for an average of 9 days (Figure 3b). This support method was also applied routinely on this group of patients. Infraorbital rim and naso-orbital region fractures were evaluated as orbital region fractures. Subciliary incision was used for orbital rim fractures. Autologous cartilage graft was applied to 3 of 6 patients with defects on the orbita base. Titanium mesh was applied to two of these patients, and reconstruction with Medpor® was done in a third patient. By entering from the maxillar sinus ostium or from the labium superior vestibulum using the Caldwell-Luc method, a Foley catheter was placed inside the maxillar sinus in 6 patients with orbita base fracture and in 5 patients with multi-fragmented fractures of the maxilla anterior wall (Figure 4a,b). Support with a Foley

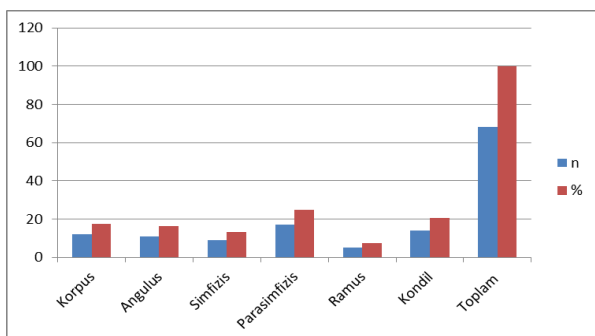


Figure 8. Distribution of fracture localization of mandible.

Table 1. Distribution of maxillo-facial fractures

Fracture region	n	%
Maxilla	36	22.36
Mandible	68	42.23
Orbita	26	16.14
Zygoma	21	13.04
Alveol	10	6.23
Total	161	100

catheter was provided to 4 patients with zygomatic arch fracture using the Gilles method after closed reduction was provided. The average follow-up period of the patients was 3 months (from 2 to 11 months).

RESULTS

A total of 161 fracture treatments were carried out from January 2009 to December 2012 in 110 patients with maxillofacial trauma. Of these patients, 82 (74.54%) were male and 28 (25.45 %) were female (Table 3). The ratio of female/male was determined to be about 1/3. Of these patients, 11 (10%) were in the paediatric age group (0-16). Maxillofacial traumas were observed most frequently in the third decade for both genders. When the etiology of maxillofacial traumas was examined, it was determined that 45 cases were traffic accidents, 32 cases were blows, 30 cases were falling, and 3 were firearm injuries. All etiological factors were more frequent in males than in females. Only 1 female patient had fractures due to firearm injuries.

The anatomic localizations that were most frequently observed in the 161 maxillofacial fracture cases in our study were 68 (42.23%) mandibula, 36 (22.36%) maxilla fractures, 21 (13.04%) zygoma fractures, and 26

Table 2. Localization of mandibular fractures

Fracture localization	n	%
Corpus	12	17.64
Angle	11	16.17
Symphysis	9	13.23
Parasymphysis	17	25.0
Ramus	5	7.38
Condyl	14	20.58
Total	68	100

Table 3. Age and gender distribution of maxilla-facial fractures

Age	Male	Female	Total (M/F)
0-10	4	2	6 (2)
11-20	5	2	7 (2.5)
21-30	27	6	33 (4.16)
31-40	15	5	20 (3)
41-50	9	6	15 (1.4)
51-60	8	2	10 (4)
60 and upper	14	5	19 (2.9)
Total	82	28	110 (2.92)

(16.14%) orbita fractures (naso-orbital or naso-orbito-ethmoidal fractures were included) (Figure 7). Whereas parasymphysis fractures were most frequently observed in 17 (25%) of the 68 mandibular fractures, it was determined that at 5 (7.38%), ramus fractures had the lowest encounter ratio (Table 2). Maxilla fractures were most frequently observed with other facial fractures. Of the maxilla fractures, 21 had maxilla anterior wall fracture, 6 had Le Forte 1, 5 had partial or unilateral Le Forte 1, 2 had Le Forte 2 and 2 had multi-fragmented fractures.

Zygoma fractures were also generally observed together with multi-fragmented fractures. Of the 33 zygoma fractures, 14 were zygoma tripod, 17 were arch, and 2 were fragmented zygoma fractures. Zygomatic body displacement can also be supported by balloon treatment technique (Figure 5). Of the 15 fractures for which support with a Foley catheter was applied, 9 had quite successful results. Good stabilization was obtained with the Foley catheter, particularly for orbita base fractures and multifragmented maxilla anterior wall. In 6 cases, the catheter balloon blew up within the first 3 days. These cases were 3 maxilla anterior wall fracture, 2 orbita base fracture, and 1 zygomatic arch fracture. However, no serious problems were observed except in 2 hasta patients. In one patient with orbita fracture, light enophthalmus was observed after the operation, whereas the other patient, with multi-fragmented fractures on the maxilla anterior wall, developed asymmetry due to zygomatic displacement (Figure 6).

DISCUSSION

The incidence of maxilla-facial fractures differs due to socioeconomical status and cultural structures. Moreover, these fractures are seen more frequently in

males than in females (4-7). Similarly, in our cases the ratio of male/female was about 3/1, which result is in accordance with other relevant studies. Previous studies have reported that 12-25% of patients with maxilla-facial fractures were in the pediatric age group (4,8). In our study, this ratio was 7.77%.

Traffic accidents are ranked first in the etiology of maxilla-facial traumas and blows are second (7,8). In our study, traffic accidents were ranked first, whereas falling and sports accidents were ranked second, and fractures due to blows were ranked third. When nasal fractures were excluded from the fractures in our study due to maxilla-facial traumas, it was observed that mandibular fractures ranked first at 42.23%, whereas maxilla fractures ranked second at 22.36%. Many studies have reported that mandibular fracture is the most frequent facial fracture (4,8-11). However, in our study, the most frequent localization of mandibular fractures was in the parasymphysis region, the second most frequent was in the condyl region, and the third most frequent was in the angulus and corpus regions (Figure 8). Although the literature reports that the most frequently fractured region is the subcondylar region, some studies have found that the most frequently fractured region is corpus followed by the angulus region (4,12). Mandibular fractures generally do not require an emergency surgical intervention following the first physical examination with airway, respiratory, and circulatory stabilization. First, the dental and occlusion status of the patient should be carefully evaluated, and the diagnosis and treatment should be planned accordingly. The selection of the surgical treatment depends on the location of the fracture, the age of the patient, the general condition, and adaptation. We routinely give antibiotics, analgesic, and mouthwash with povidon iodine to patients. Some studies have reported that the delay of surgery does not increase the risk of infection (12-16). However, surgical intervention should be carried out as soon as possible for patients with severe injuries. In this study, stabilization was maintained with a Barton bandage for patients with mandibular fractures during the waiting period. The Barton bandage was applied on child, elderly, and edentulous patients for a period of 4 to 6 weeks and a soft liquid diet was recommended, which was very effective in decreasing the occlusal load (17). Maxilla-mandibular fixation was provided using an arch bar for fractures that had no displacement on the fracture line or that contained the alveolar region (18,19). Maxilla-

mandibular fixation with arch bar is a practical and effective method. However, it has several disadvantages since it cannot be applied on patients with oral hygiene disorder, temporomandibular joint problems, or edentulous patients. However, the arch bar was used in combination with rigid fixation by mini plates for fractures with displacement. Open reduction and internal rigid fixation with mini plates were used in the surgery of all maxilla-facial fractures if there was a displacement in the fracture line. If no laceration occurred during the trauma, classical intraoral, subciliary, lateral eyebrow (Dingman), and temporal (Gilles) incisions were prepared for the surgery of all maxillofacial fractures. An extraoral approach was not used, and fixation did not include Risdon incision on our patients. A Foley catheter was placed inside the fractured side maxillary sinus for maxilla anterior wall multifragmented fractures and orbita base fractures in order to provide fracture reduction and to ensure balloon treatment during stabilization following reduction. The catheter can be placed via the Caldwell-Luc method through the incision on the intraoral upper lip vestibulum or through the maxillary sinus ostium inside the nose. This method is quite effective for multi-fragmented maxilla fractures and orbita base fractures. In addition, this method is also effective in providing stabilization of the fracture line following reduction in arch fractures. This treatment method is a closed and practical process that has disadvantages, such as insufficient resistance of the balloon side and difficulty in accessing localizations, e.g., frontal sinus fracture. The real surgical indications during the treatment of orbita fractures are the contraction of muscles and the increase in orbital volume (19,20). Muscle contraction determined using the forced duction test and soft tissue contraction displayed via BT requires early exploration. We used subciliary incision on all our patients if there was no trauma-based laceration. In the literature, ectropion ratios following subciliary incision are stated at 10% (20). Ectropion developed in one of our patients, and the patient was reoperated.

The most frequently observed maxillo-facial fracture is the fracture of nasal bones. Nasal fractures should ideally be reduced during the first 3 hours following trauma or during the first 7 days following the healing of the edema (8,11,19). Nasal fractures were excluded from our study since reduction is made for most of these in the emergency ward.

In conclusion, since maxillofacial fractures may be seen in many patients who apply to hospitals due to traumas, sufficient experience of doctors working in this field is an important factor in decreasing mortality and morbidity. The most frequent patients are males aged 30 to 40 with maxillofacial trauma caused by a traffic accident, a sports accident, or a blow. Determination of the localization and type of the fracture in addition to the fixation of the other structures affected by the fracture are very important in the determination of the surgical approach and the treatment method. Retrospective or epidemiological studies similar to our study are very beneficial for the determination of risk groups, specific precautions, and practical and effective treatment methods.

Conflict of interest: The authors declare there is no conflict of interests. Funding: No funding provided for this study.

REFERENCES

1. Hausamen JE. *The scientific development of maxillofacial surgery in the 20th century and an outlook into the future.* *J CranioMaxillofac Surg* 2001;29:2-21
2. Kamulagegeya A, Lakor F, Kahenge K. *Oral Maxillofacial fractures seen at a Ugandan tertiary hospital: A six-month prospective study.* *Clinics* 2009;64:843-8
3. Hogg NJ, Stewart TC, Armstrong JE, Girotti MJ. *Epidemiology of maxillofacial injuries at trauma hospitals in Ontario, Canada between 1992 and 1997.* *J Trauma* 2000;49:425-32
4. Bataineh AB. *Etiology and incidence of maxillofacial fractures in the North of Jordan.* *Oral Surg Oral Med Oral Pathol Oral Radiol Endod* 1998;86:31-5
5. Ugboke VI, Odusanya SA, Fagade OO. *Maxillofacial fractures in a semi-urban Nigerian teaching hospital. A review of 442 cases.* *Int J. Oral Maxillofac Surg* 1998;27:286-9
6. Brasileiro BF, Passeri LA. *Epidemiological analysis of maxillofacial fractures in Brazil: A 5-year prospective study.* *Oral Surg Oral Med Oral Pathol Oral Radiol Endod* 2006;102:28-34
7. Kırış M, Yuca K, Çelebi S, Kiroğlu F, Çankaya H. *Approachment of treatment in maxillofacial trauma.* *Turk J Med Sci* 2009;29:696-701
8. Tuncalı D, Barutçu AY, Terzioğlu A, Aslan G. *Epidemiological evaluation of Hospitalized Mid-facial and Lower-facial fracture patients.* *Turk J Med Sci* 2005;25:51-7
9. Malara P, Malara B, Drugacz J. *Characteristics of maxillofacial injuries resulting from road traffic accidents- a 5 year review of the case records from Department of Maxillofacial Surgery in Katowice, Poland.* *Head Face*

Medicine 2006;2:27

10. Mallikarjuna SK, Krishnappa P. Prevalance of maxillofacial injuries by motorized two wheeler road traffic accidents in Bangalore city. *Dental traumatology* 2009;25:599-604
11. Şenen D, Erol S, Orhan E, Sevin A, Erdoğan B. Clinic approachment in mandibular fracture. *Türk Plast Rekonst Est Cer Derg* 2006;14:103-5
12. Bochlogyros PN. A retrospective study of 1521 mandibular fractures. *J Oral Maxillofac Surg* 1985;43:597-9
13. Abubaker AO. Use of prophylactic antibiotics in preventing infection of traumatic injuries. *Oral Maxillofac Surg Clin North Am* 2009;21:259-64
14. Miles BA, Potter JK, Ellis E III. The efficacy of postoperative antibiotic regimens in the open treatment of mandibular fractures: A prospective randomized trial. *J Oral Maxillofac Surg* 2006;64:576-82
15. Czerwinski M, Parker WL, Correa JA, Williams HB. Effect of treatment delay on mandibular fracture infection rate. *Plast Reconstr Surg* 2008;122:881-5
16. Stone IE, Dodson TB, Bays RA. Risk factors for infection following operative treatment of mandibular fractures: A multivariate analysis. *Plast Reconstr Surg* 1993;91:64-8
17. Sojot AJ, Meisami T, Sandor GKB, Cloike CM. The epidemiology of mandibular fractures treated at the Toronto general hospital: A review of 246 cases. *J Can Dent Assoc* 2001;67:640-4
18. Taş E, Vural Ş, Ayan N, Gürsel AO. Results of Mandibular Fractures. *KBB ve BBC Dergisi* 2006;14:21-4
19. Gleeson M. Fractures of the facial skeleton. In: Kerr AG, ed. *Scott- Browns Otolaryngology*. Oxford/London: 6th Edition, Butterworth- Heinemann Pub Ltd, 1997:1-31
20. Ellis E III, KittidumkerngW. Analysis of treatment for isolated zygomaticomaxillary complex fractures. *J Oral Maxillofac Surg* 1996;54:386-400