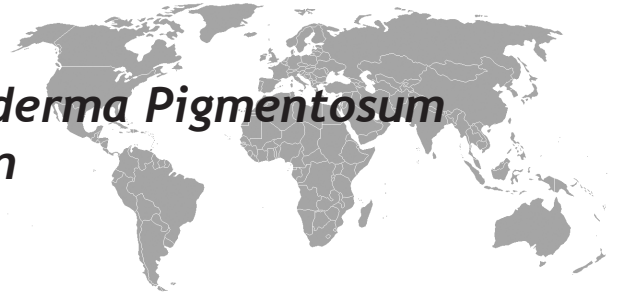


Dental Treatment of A Xeroderma Pigmentosum Patient Under Deep Sedation

Zeynep Başak Öktem¹, Efsun Songür², Firdevs Tulga Öz¹



ABSTRACT

Xeroderma pigmentosum (XP) is an autosomal recessive disorder which is characterized by hypersensitivity to ultraviolet radiation, premature skin aging, abnormal pigmentation and metabolic defects. This article presents dental treatment of a XP patient to highlight the precautions the dental practitioner must take when treating these cases. Because adequate cooperation could not be obtained for this patient, dental treatment was performed under deep sedation and the patient was placed on a preventive protocol. A number of issues must be considered when providing dental treatment to patients with XP, including adequate office preparation prior to the patient's arrival, testing every light source that the patient could be exposed to during the visit. It should also be noted that patients with XP often do not maintain routine dental appointments; therefore, meticulous oral hygiene that includes proper brushing, flossing and fluoride rinsing is advisable.

Key words: Xeroderma pigmentosum, dental treatment, deep sedation

Kseroderma pigmentosumlu Bir Hastanın Derin Sedasyon altında Diş Tedavisi

ÖZET

Kseroderma pigmentozum (XP), otozomal resesif geçişli bir hastalık olup ultraviyole ışığa karşı aşırı hassasiyet, erken cilt yaşlanması, anormal pigmentasyon ve metabolik bozukluk ile karakterizedir. Bu makalede; diş hekimliğinde XP tanısı konan hastaları tedavi ederken alınması gereken önlemler vurgulanarak bir XP hastasının dental tedavisi anlatılmıştır. Kooperasyon kurulamadığı için dental tedavisi derin sedasyon uygulamasıyla yapılan hastanın koruyucu tedavi protokolü altında takibi devam etmektedir. XP hastalarının dental tedavisi öncesi tedavi yapılacak odanın hazırlanmasından kullanılacak tüm ışık kaynaklarının UV ışın bakımından ölçülmesine kadar dikkat edilmesi gereken birçok unsur bulunmaktadır. Ayrıca bu hastaların düzenli olarak diş hekimi kontrolüne gelebilecekleri göz önüne alındığında düzenli fırçalama, diş ipi kullanımı ve floridli gargaralar ile oral hijyenin sağlanması önemlidir.

Anahtar kelimeler: Kseroderma pigmentosum, diş tedavisi, derin sedasyon

INTRODUCTION

Xeroderma pigmentosum (XP) is a genetic disorder caused by defects in nucleotide excision repair in fibroblast cells. This rare, autosomal recessive disorder is characterized by hypersensitivity to ultraviolet (UV) radiation, premature skin aging, abnormal pigmentation and metabolic defects that include gross aminoaciduria and a raised levels of serum glutamic acid transaminase (1-3). Approximately 20% of patients with XP develop neurologic abnormalities such as mental retardation, with variable age of onset

and rate of progression (4,5). The frequency of occurrence of XP among the general population is estimated to be 1/250000, and the disease affects both sexes equally (6).

XP is definitively diagnosed by measuring the DNA repair defect from skin or blood obtained from the patient (7). Clinical symptoms can initially be observed in the sun-exposed areas of the skin and eyes. Atrophy, telangiectasia, skin tumors and oral carcinomas (basal and squamous cell carcinomas) changes are other common manifestations.

¹DDS, PhD, Ankara University, Faculty of Dentistry, Department of Pediatric Dentistry, Ankara, Turkey, ²DDS, Ankara University, Faculty of Dentistry, Department of Pediatric Dentistry, Ankara, Turkey

Correspondence: Zeynep Başak Öktem
Ankara Üniversitesi Diş Hekimliği Fakültesi Pedodonti Anabilim Dalı 06500
Beşevler/ Ankara/Turkey
Tel: +903122965672, Fax: +903122123954
E mail: zbasakyilmaz@yahoo.com

Received: 04.11.2010, Accepted: 02.12.2010

The lesions most pertinent to the dental practitioner are those found in the head and neck region. Oral manifestations usually involve the lips and anterior portion of the tongue and include cheilitis, glossal telangiectasia and leukoplakia (8,9).

This article presents a case of XP to highlight the precautions the dental practitioner must take when treating XP patients.

CASE

A 2.5-year-old girl diagnosed with XP was brought to the clinic by her parents with the complaints of dentalgia, feeding difficulties and lip fissures. XP symptoms had first been observed in the patient at the age of 6-months and included an abnormal reaction to sun exposure that manifested as sunburn-like bullae. Diagnosis of the disease occurred over a period of 1.5 years. Since diagnosis of XP, the patient has worn special clothes, sunglasses and gloves to protect her from sunlight. She has also been reported to have mild mental retardation and speech abnormalities related to the syndrome. Extra-oral examination revealed thin and dry lips and facial skin, freckles and cheilitis angularis on both lip commissures. Intra-oral examination showed no carcinomatous changes, keratoses or abnormal pigmentation within the oral cavity; however, deep dentin caries were seen in the maxillary anterior and primary first molar teeth. Radiographic examination was not possible due to limited patient cooperation. Because adequate cooperation could not be obtained, it was suggested that dental treatment be performed under deep sedation. The sedation procedures and planned dental treatment, including possible risks, discomforts and benefits, were fully explained to the patient's parents, and their written informed consent was obtained for both treatment and publication of this case. Although pre-treatment drug prophylaxis was not required for XP patients, certain protective measures were implemented to protect the patient from sunlight. Windows were sealed with a dark coverin, the door to the operating room was kept closed during the procedure, and light-emitting diode curing lights were not used. Furthermore, all precautionary measures were taken to ensure her safety with UVA and UVB light meters (Lutron UV Light meter, Lutron, Taipei, Taiwan). Prior to sedation, the patient fasted for 4 h. At the beginning of the procedure, the patient was sedated with Dormicum (midazolam, 0.1 mg.kg-1) and Propofol (propofol, 1 mg.kg-1) delivered

intravenously by an anesthesiologist. Once unconscious, the child was provided with supplemental oxygen (4 L.min-1) via a nasal cannula and allowed to breathe spontaneously. Pulse oxymetry and ECG monitoring were applied, and the child was administered Fentanyl Citrate (fentanyl, 1 µg.kg-1) intravenously. During the procedure, supplemental propofol (0.5 mg.kg-1) or fentanyl (0.5-1 µg.kg-1) was administered, as required, when signs of insufficient sedation (movement, coughing) were observed. An anesthesiologist was present to monitor the patient throughout the entire procedure. All primary first molars and maxillary anterior teeth were conservatively restored with glass ionomer cement (Ketac™ Molar Easymix, 3M ESPE, St.Paul, Germany). Then a fluoride varnish surface coating was applied to all teeth for caries prevention. Sedation was stopped upon completion of treatment, and the patient was allowed to be discharged from the hospital as soon as she was fully awake, able to cough or breathe deeply, move all limbs voluntarily and maintain an oxygen saturation level greater than 93% in air. The patient was given a lubricating ointment (Bepanthen Cream, Bayer, İstanbul, Turkey) to treat her cheilitis and was placed on a preventive protocol that included meticulous oral hygiene, parental education, dietary recommendations and routine recalls.

DISCUSSION

This article presents a case of XP. Due to the patient's age and early diagnosed, she had no oral manifestations, with the exception of cheilitis angularis. Although there are many reports of XP in the medical literature, the dental literature contains very little information about this rare disease. This is likely due to the infrequency of oral manifestations, which have been observed in only 4 percent of all XP patients (9).

A number of issues must be considered when providing dental treatment to patients with XP, the most important of which involves adequate office preparation prior to the patient's arrival. The dentist must use a UV light meter to test every light source that the patient could be exposed to during the visit, including overhead lights, dental lamps, viewboxes, fiberoptic lights, computer screens and dental curing units. Any reading above 0nm/cm² for UV light should contraindicate the use of that unit. In the case presented here, the overhead lights and dental lamp were found not to emit any wavelength that might pose a danger to the patient and were therefore deemed safe to

use during the dental procedure. However, windows were sealed with a dark coverin to prevent any sunlight from entering into the office.

Any procedure that requires traditional curing lights presents a dilemma for the treatment of an XP patient. Although light-emitting diode curing lights are manufactured to emit a wavelength of only 450nm (7), the extent of biological damage from exposure is not adequately understood. Curing light filters may be ineffective or become worn out over time, allowing transmittance of wavelengths in the UVB range (290-320nm), which are known to have significant carcinogenic effects on normal epithelium (10,11). For these reasons, restorative materials such as glass ionomers offer a good alternative to resin sealants and composite restorations for treating XP patients (7). In the case presented here, glass ionomer cement was used for dental restorations.

In conclusion, there is currently no known cure for XP. Without preventative and early treatment that address problems as they arise, malignancy is inevitable (7). Patients should undergo regular medical visits to ensure that any new lesions are detected and treated. Periodic oral examination is also important and should include complete inspection and palpation of soft tissues (lips, tongue and oral mucosa). Furthermore, radiation therapy used to treat head and neck tumors can cause radiation caries and permanent damage to salivary glands. It should also be noted that patients with XP often do not maintain routine dental appointments; therefore, meticulous oral hygiene that includes proper brushing, flossing and fluoride rinsing is advisable (7,12).

REFERENCES

1. Alymlahi E, Dafir R. Bilateral facial squamous cell carcinoma in an 18-month year oldgirl with xeroderma pigmentosum. *J Post Grad Med* 2005; 51: 128-9.
2. Kraemer KH, Lee MM, Andrews AD, Lambert WC. The role of sunlight and DNA repair in melanoma and nonmelanoma skin cancer. *Arch Dermatol* 1994; 13: 1018-21.
3. Kraemer KH, Lee MM, Scotto J. Xeroderma pigmentosum. *Arch Dermatol* 1987; 123: 241-50.
4. Robbins JH. Xeroderma Pigmentosum: defective DNA repair causes skin cancer and neurodegeneration. *JAMA* 1988; 260: 384-8.
5. Kraemer KH, Slor H. Xeroderma pigmentosum. *Clin Dermatol* 1985; 3: 33-69.
6. Robbins JH, Kraemer KH, Lutzner MA, Festoff BW, Coon HG. Xeroderma pigmentosum: An inherited disease with sun sensitivity, multiple malignant neoplasms and abnormal DNA repair. *Ann Int Med* 1974; 80: 221-48.
7. Park S, Dock M. Xeroderma pigmentosum: a case report. *Pediatr Dent.* 2003; 25: 397-400.
8. Khatri ML, Shafi M, Mashina A. Xeroderma pigmentosum. *J Am Acad Dermatol.* 1992; 26: 75-8
9. Kraemer KH, Lee MM, Scotto J. Xeroderma pigmentosum. *Arch Dermatol* 1987; 123: 241-50.
10. Epstein JH. Ultraviolet carcinogenesis. *Photophysiology.* 1970; 5: 235-73.
11. Setlow RB. The wavelengths in sunlight effective in producing skin cancer: a theoretical analysis. *Proc Natl Acad Sci USA.* 1974; 9: 3363-6.
12. Patton LL, Valdez HI, Bethesda M. Xeroderma pigmentosum: review and report of a case. *Oral surg oral med oral pathol* 1991; 71: 297-300.