



# Giant Aneurysmal Bone Cyst of the Rib

Serhat Avcu, Nurşen Toprak, Mehmet Deniz Bulut, Özkan Ünal

Yüzüncü Yıl University Faculty of Medicine,  
Department of Radiology, Van, Turkey

Eur J Gen Med 2012;9 (Suppl 1):47-49

Received: 10.12.2010

Accepted: 28.12.2010

## Abstract

Aneurysmal bone cyst (ABC), especially in the ribs, is a rare disease, considering to be a benign lesion which occurs mostly in children and young adults. This case, however, concerns a 46-year-old female patient, with complaints of pain and palpable mass in the right thoracic wall, who was diagnosed to have ABC originating from the rib demonstrated by radiological examinations, aspiration biopsy, and histopathological verification. Surgical resection was performed to the lesion.

**Key Words:** Aneurysmal bone cyst, rib, radiology

## Kostanın Dev Anevrizmal Kemik Kisti

Anevrizmal kemik kisti (AKK), özellikle kaburgalarda, çoğunlukla çocuklarda ve genç yetişkinlerde görülen ve benign olduğu kabul edilen nadir bir hastalıktır. Bu olgu sağ göğüs duvarında ağrı ve ele gelen kitle şikayeti ile gelen ve radyolojik incelemeler, aspirasyon biyopsisi ve histopatolojik doğrulama ile kaburga kaynaklı AKK tanısı alan 46 yaşında bayan hastayı anlatmaktadır. Lezyon cerrahi olarak çıkarılmıştır.

**Anahtar kelimeler:** Anevrizmal kemik kisti, kosta, radyoloji

**Correspondence:** Serhat Avcu, M.D.  
Yüzüncü Yıl University Faculty of Medicine  
Department of Radiology  
65100, Van, Turkey  
Tel: 904322150474  
E-mail: serhatavcu@hotmail.com

## INTRODUCTION

An aneurysmal bone cyst (ABC) was first described by Jaffe and Lichtenstein in 1942 (1). ABCs are benign, expansile, locally aggressive lesions of the bone, containing thin-walled blood-filled cavities that are lined by connective tissue with giant cells and trabecular bone (2). The real place of the lesion in the classification of bone diseases, and whether it is reactive (non-neoplastic) or neoplastic is still in debate (3). Histologically, ABC is composed of cavernomatous spaces full of non-clotting blood, and accompanying solid regions which are characterized by fibroblastic, fibrohistiocytic and osteoblastic proliferations (4). ABC, which mostly occurs in the spine and long bones and rarely in the ribs (5-6), and generally in patients under 20 years of age (2), constitutes 1% of primary bone tumors (3). To our knowledge, a total of 44 costal ABCs, 17 of which being in Japan have been described in the literature (1, 7). Here we report a rare case of costal ABC which was diagnosed as a result of (demonstrated by) radiological examinations, aspiration biopsy, and histopathological verification.

## CASE

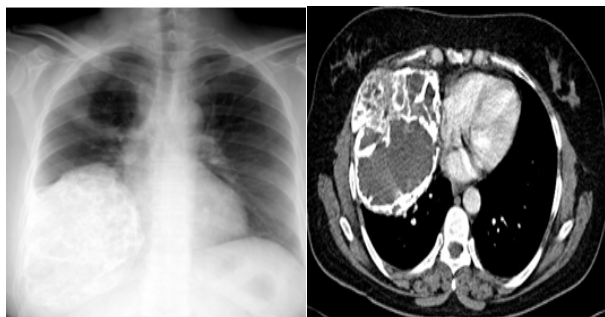
A 46-year-old woman visited to our hospital with complaints of a palpable firm mass on the thorax wall inferior to right breast, chest pain with a duration of 2-years that exacerbated in the last 2 months, and shortness of breath. On physical examination, a firm mass lesion with no warmth or redness was palpated on the right lateral chest wall. Laboratory examinations revealed no specific abnormality. On direct chest roentgenogram, a heterogeneous lesion with a diameter of 14x11cm consisting of radiolucent and radioopaque regions was detected in the mid-inferior zone of the right hemithorax. The lesion was just neighbouring the right hemi-diaphragm inferiorly, with a lobulated contour (Figure 1a). On computed tomography (CT) scan, the lesion was observed to have calcifications and cystic components, making cortical irregularity at the lateral border of the 6th costa, and reaching to intercostal space, right hemidiaphragm, and paracardiac space (Figure 1b). Magnetic resonance imaging (MRI) displayed a lesion which was hyperintense on T1- and isointense to muscle on T2-weighted images, composing of solid components and cysts with multiple septae (Figure 2 a,b). The mass was expanding into the muscular layers of the thorax wall anteriorly. No remarkable enhancement was detected in the lesion after

intravenous gadolinium injection. With a presumptive diagnosis of ABC, needle-aspiration was performed to the lesion under sonographic guidance, and non-clotting hemorrhagic fluid was obtained as aspiration material which was confirmed to be ABC histopathologically. The lesion was treated surgically.

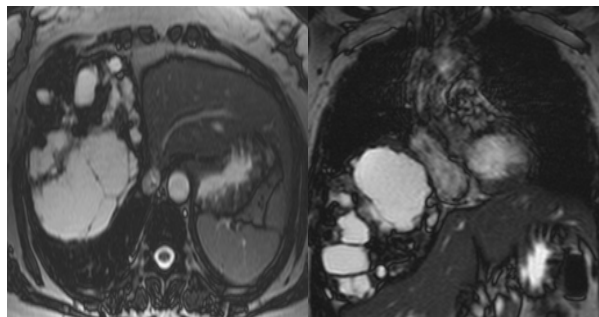
## DISCUSSION

ABCs can involve any bone, the most common site being ends of long tubular bones of limb followed by the vertebral column. They have not been very commonly reported from the ribs (8). Worldwide, the cases of ABC originating from the rib are rare (1). Almost all of the ABC cases are seen below the age of 30 years (giris bolu-munde 20 yas olara demissinz), and they are extremely rare above the age of 50 years, because they occur in the growing bones. Our patient was 46 years-old. The most common symptoms in a patient with aneurysmal bone cyst of the rib are chest pain, swelling of chest wall, dyspnea, and pathologic fracture (5). Our patient had complaints of a palpable firm mass on the thorax wall inferior to right breast, chest pain, and shortness of breath. Although the ABC has characteristic radiological, clinical, and pathological findings, its etiology and pathogenesis is still in debate. Bieseckel et al reported that the primary lesion had originated from the bone or periosteal region as an arteriovenous malformation, and reactive ABC had developed as a result of the hemodynamic effects of the blood flow (9). ABC is morphologically classified as cystic, cystic-solid (mixed), and solid. The most notifying characteristic of the cystic type of the ABC is the cavernous spaces that have a wall composed of the mixture of fibrous tissue, giant cells, and osseous tissue. Mixed type ABC lesions are a mixture of fibrous septae, cavernous spaces full of blood, giant cells, fibrous, osteoblastic, and solid components. On the other hand, solid type, which is on the other side of the spectrum, has fibrous proliferation, scattered benign giant cells, and osteoid trabecules (4, 10-11). The clinical and pathological similarities among these three types of ABC lesions lead to an idea that these are associated with intraosseous hemorrhage. The lesion in our case was evaluated as mixed-type ABC.

Three types of radiological appearance could be seen during the development of ABC: early lytic phase, mature phase which has a peripheral calcified border, and calcified phase, respectively. The ABC in our case was in



**Figure 1.** 1a: On direct chest roentgenogram, a heterogeneous lesion (arrows) consisting of radiolucent and radioopaque regions in the mid-inferior zone of the right hemithorax, just neighbouring the right hemidiaphragm inferiorly, is seen. 1b: On CT-scan, a lesion with calcifications and cystic components, making cortical irregularity at the lateral border of the 6th costa, reaching to intercostal space, right hemidiaphragm, and paracardiac space is seen.



**Figure 2.** Axial (a) and coronal (b) T2-weighted MRI displaying a lesion which is hyperintense on T1- and isointense on T2-weighted images, composing of solid components and cysts with multiple septae.

mature phase. Bertoni et al (10) reported 15 of 200 ABC cases to have solid variant.

In the radiological diagnosis of the ABC, CT is very helpful to demonstrate multiple fluid-levels in the lesion. MRI examination is also very helpful in the diagnosis of ABC. The periosteal membrane is seen as a hypointense border surrounding the cystic mass in both T1- and T2-weighted images. A multicystic mass with lobulated contour and multiple fluid levels of mixed signal intensity due to the hemorrhagic material is seen on T1-weighted images. T2 W signal intensity changes according to the stage of the hemorrhage. On post-contrast T1-weighted images, peripheral and septal enhancement may be observed (10,11). In our case, no enhancement was detected on post-contrast series. Bertoni et al (10) reported that cortical destruction was rare in solid variant ABCs although cortical erosion and expansion was detected in most of them. It can be difficult to differentiate solid variant ABCs from well-differentiated osteosarcomas radiologically. In spite of the well differentiated osteosarcomas, the solid variant ABCs have a short duration of clinical complaints (4), which can help in the differential diagnosis.

In conclusion, since the ABC may have an expansile and lytic character, and may have solid variant, it can cause radiological diagnostic dilemma, so it should be kept in mind in the differential diagnosis of bone lesions.

#### REFERENCES

1. Yoshida K. Aneurysmal bone cyst of the rib. *Surg Today* 2005;35:1073-5.
2. Lee SY, Lee SJ, Lee CS, Lee KR. Aneurysmal bone cyst originating from the first rib. *Am J Surg* 2008;195:104-5.
3. Dogan H. Aneurysmal bone cyst. *J Turk Spinal Surg* 2006;17:11-6.
4. Kervancioğlu S, Kervancioğlu R, Şirikçi A, Özkur A. Case report: solid variant of aneurysmal bone cyst of the clavicle in a child. *Turk J Diagn Interv Radiol* 2002;8:299-301.
5. Kalkat MS, Collins FJ. Aneurysmal bone cyst presenting as an intrathoracic mass in an infant. *Interact Cardiovasc Thorac Surg* 2003;2:668-70.
6. Soyer T, Karnak I, Talim B, Tanyel FC. Aneurysmal bone cyst of the rib in a child. *Surg Today* 2005;35:886-9.
7. Sadighi A, Tuccimei U, Annessi P. Aneurysmal bone cyst of the rib. *Chir Ital* 2006;58:403-6.
8. Dusaj IS, Pant K, Kumar V. Aneurysmal bone cyst presenting as a posterior mediastinal mass. *Indian J Chest Dis Allied Sci* 1988;30:269-71.
9. Biesecker JL, Marcove RC, Huvous AG, Mike V. Aneurysmal bone cyst. *Cancer* 1970;26:615.
10. Bertoni F, Bacchini P, Capanna R, et al. Solid variant of aneurysmal bone cyst. *Cancer* 1993;71:729-34.
11. Maeda R, Sumitomo S, Matsuoka K. Solid variant of aneurysmal bone cyst. *Kyobu Geka* 2006;59:1131-3.