



Management of Operable Breast Cancers When Patient Refuses Surgery

Biswa M Biswal¹, Zainal Mahmood², Salmah J³, Nor H Othman⁴, Mohamed Ali Abdul Khader⁵

University Sains Malaysia, School of Medical Sciences, Departments of Nuclear Medicine, Radiotherapy and Oncology¹, Surgery², Radiology³ and Pathology⁴, Kubang Kerian, Kelantan, Malaysia

⁵PET Service, Department of Nuclear medicine, General Hospital Palau Pinang, Malaysia

Eur J Gen Med 2010;7(3):340-344

Received: 26.08.2009

Accepted: 18.09.2009

ABSTRACT

Surgery is the crucial modality of management in the multidisciplinary care of breast cancer. Without surgery the outcome of treatment is complicated and sub-optimal. The oncologists face dilemma when patient refuse for surgery or not operable due to patients medical condition. Here we describe two post-menopausal women with operable breast cancers those refused surgery. We managed these patients with induction chemotherapy, radical radiotherapy and hormonal therapy. Their serial radiological evaluation revealed complete disappearance of primary breast tumor and axillary lymph nodes at the end of 88 and 69 months post treatment with good cosmesis. Conservative management may be an option among post-menopausal women with operable breast cancers those refuse surgery. The controversial management of above cases has been discussed with review of literature.

Key words: Breast cancer, refuse surgery, radiotherapy, outcome

Cerrahiye Kabul Etmeyen Operabl Meme Kanseri Hastaların Tedavisi

Meme kanserinin multidisipliner tedavisinde cerrahi hayati tedavi yöntemidir. Cerrah olmadan tedavinin sonucu komplike ve suboptimaldır. Hasta cerrahisi reddettiğinde veya klinik durumu cerrahiye uygun olmadığında onkologlar ikilemeyle karşılaşılır. Burada cerrahiye reddeden iki postmenapozal operabl meme kanseri vakasını bildiriyoruz. Bu hastaları indüksiyon kemoterapisi, radikal radyoterapi ve hormonal tedavi ile tedavi ettik. Bu hastaların seri radyolojik değerlendirmeleri tedavi sonrası 88 ve 69. aylarda primer meme tümörünün ve aksiler lenf nodlarının iyi kosmetik görünümle birlikte tamamen kaybolduğunu gösterdi. Konservatif tedavi operabl meme kanseri olan ve cerrahiye reddeden postmenapozal kadınlarda bir seçenek olabilir. Yukarıdaki vakaların tartışmalı tedavi yaklaşımları literatür eşliğinde tartışıldı.

Anahtar kelimeler: Meme kanseri, cerrahiye red, radyoterapi, sonuç

Correspondence: Biswa Mohan Biswal. MD Associate Professor, Radiotherapy & Oncology, School of Medical Sciences, Health Campus, University Sains Malaysia, 16150, Kubang Kerian, Kelantan, Malaysia Tel: 6097676666, Fax: 6097644416 Email biswa@kb.usm.my

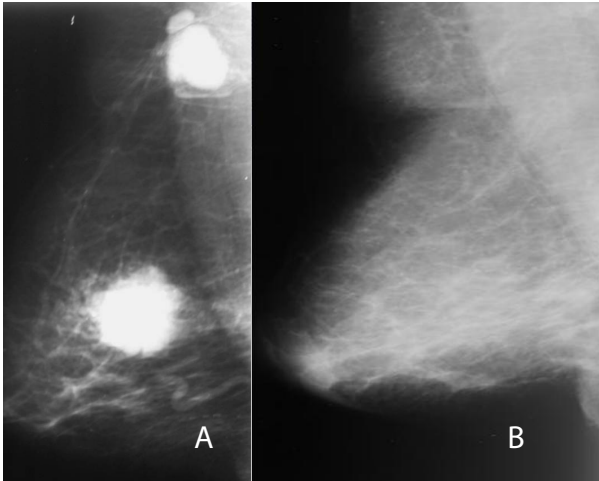


Figure 1. Serial mammogram images showing before treatment (1A) and at 2-years (1B).

INTRODUCTION

The Breast cancer is the most common cancer among women. One out of every nine women in United States develops breast cancer (1). It accounted for 31% of all newly diagnosed breast cancer in Malaysia (2). The most common age incidence is in the 5th decades of life which is changing towards 6th decade possibly due to hormone replacement therapy (3). The breast cancers in post-menopausal patients are usually low grade and invariably hormone receptor positive and slow growing. The standard management of operable breast cancers is surgery in conjunction with adjuvant chemotherapy, radiotherapy and hormone therapy. In early stages breast

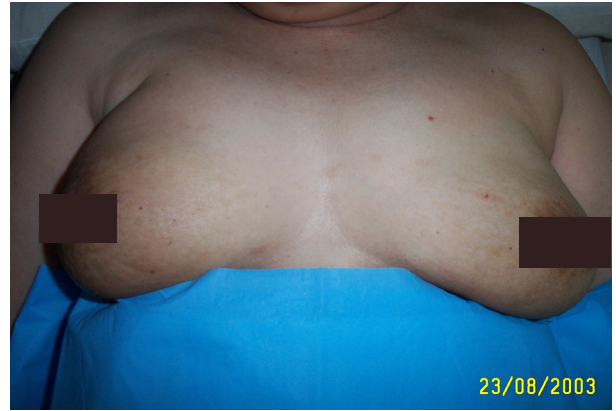

Figure 2. Clinical pictures showing cosmetic outcome after treatment

conservation surgery with axillary lymph node sampling is recommended whereas in relatively advanced cases a standard modified-radical mastectomy with axillary lymph node dissection considered optimal in the current standard. Thus surgery is an integral part of breast cancer treatment. When patient refuse surgery or patient is medically inoperable due to co-morbid medical conditions, oncologists face challenge for a suitable management option (4). With the development of effective chemotherapy and hormone therapy, complete response (CR) rate of around 40% could be easily achievable. Those patients with complete response could be salvaged with radical radiotherapy. Experience from the management

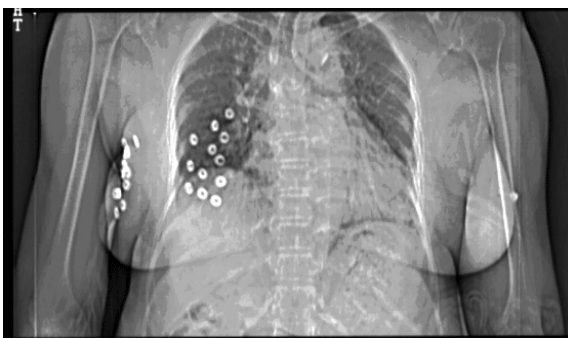

Figure 3. Computer axial tomography topogram showing brachytherapy volume implantation

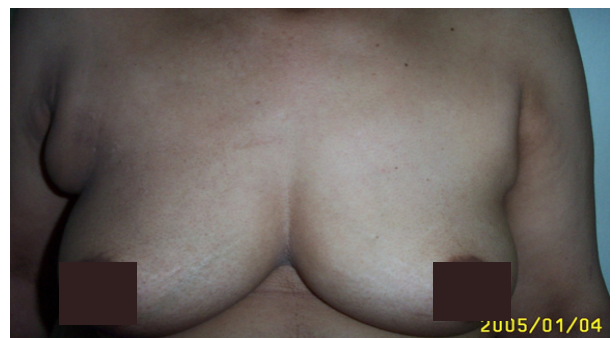

Figure 4. Clinical picture showing cosmetic outcome after 69months post treatment

of locally advanced breast cancer in the past has shown that induction chemotherapy could result in a complete histopathological response rate of 15-30% of patients (5). These patients could be candidate of breast conservation technique. Few studies from Europe have shown the effectiveness of hormone therapy alone in the management of post-menopausal early breast cancers (6). Very small tumors measuring less than 2 cms can be managed with high frequency ultrasound ablation without surgery (7). Here we have presented outcome of management of two operable cases of post-menopausal breast cancers those refuse standard recommended surgery.

CASE

Case 1

A 68-year-old postmenopausal lady presented with complaint of right breast lump over 4-month duration. It was initially started as 3x2 cms lump over the right upper outer quadrant progressively increasing in size. The lump was non-tender and unassociated with nipple discharge or fever. Subsequently she noticed one small lump on her axilla. She was seen by a surgeon and on examination found to be having an intramammary mass on her right breast on the upper outer quadrant measuring 6x5 cms. The lump was oval in shape, mobile and unassociated with nipple retraction or chest wall fixation. The examination of her axilla revealed a central group lymph node measuring 1x1cms, single and non-tender. She underwent bilateral mammogram and revealed a calcified mass with spiculation in her right upper outer quadrant. There was a calcified lymph node in her right axilla. Magnetic resonance imaging (MRI) of her breast revealed an enhancing lesion in the above anatomical site. She underwent fine needle aspiration cytology from the breast lesion and axilla. The cytological feature was suggestive of infiltrating ductal carcinoma. Her radionuclide ^{99}Tc bone scans, ultrasound liver, chest radiograph, serum liver and kidney chemistry including complete blood count revealed normal findings. She was clinically staged as T3N1M0 and opted for modified radical mastectomy and axillary node dissection. However despite several counselling sessions the patient refused surgery. She was thoroughly informed about the consequences of not having surgery. She requested for non-surgical option and she was planned for induction chemotherapy using CEF regimen; consisted of 500mg/m² cyclophosphamide intravenous bolus, 70mg/m² epirubi-

cin, and 5-fluorouracil 500mg/m² along with ondansetron in intravenous bolus administration on day-1. The above chemotherapy regimen was administered every 3-weeks for 6-cycles. She tolerated this chemotherapy well. Following chemotherapy she achieved complete clinical response. After a gap of 3-weeks, her whole breast was irradiated to a dose of 46 Gy in 23 fractions over 4.5 week period, using 6 MV linear accelerator. A MRI scan of her breast revealed complete resolution of the primary and axillary node. Subsequently her primary tumor was boosted with interstitial brachytherapy. A 3-plane volume implant was carried out and a further dose of 15Gy in 6 fractions over 3-days was delivered in b.i.d schedule using microSelectron high dose rate (HDR) run by iridium-192 source. Following brachytherapy the patient was put on oral tamoxifen at a dose of 20mg per day. She was followed up at a regular interval with regular mammogram assessment. Her follow up Mammogram (Figure-1B) scan showed complete resolution of the primary lesion. At the time of reporting (88-months), the patient is healthy with good cosmesis at the primary site (Figure 2).

Case 2

A 56-year-old nurse presented with right breast swelling over a period of one month and discovered on self-breast examination in April 2003. The swelling was increasing in size up to the size of an orange. It was not associated with breast pain, nipple discharge or retraction. She was postmenopausal for 5-years, multiparous and her last childbirth was 23 years ago. She attended her menarche at the age of 14 years and menopause at 50 years. On examination there was a 6x5 cms intramammary, mobile, non-tender lump in the upper outer quadrant of her right breast. The lump did not associated with nipple retraction or fixation to the underlying chest wall. Rest of the systemic examination was within normal limits. She immediately underwent bilateral mammogram that showed features of malignancy. Subsequently a cytology sample was obtained by needle aspiration. The microscopic features suggestive of infiltrating ductal carcinoma. Her further metastatic work up with ultrasound liver, chest radiograph, radionuclide ^{99}Tc bone scan, and liver & renal chemistry and complete blood count were all within normal limits. She was clinically staged as T3N0M0 and opted for mastectomy and axillary clearance. Being a senior nurse she had fair

understanding about her disease and opted for her management supplemented with the advice of her surgeon and oncology counsellor. However she refused for standard treatment option and looking for non-surgical option. She was also explained about the inferior nature of alternate treatment technique. With her agreement, we proceed with 6-course of CEF combination chemotherapy that she tolerated well. To our surprise she achieved complete response on clinical evaluation. Then she was offered whole breast radiotherapy dose of 46 Gy in 23 fractions over 4.5 weeks using 6-MV x-ray from a linear accelerator. After a gap of 3-weeks, she was planned for interstitial brachytherapy. A volume implant was done using removable plastic catheters (Figure 3). A radiation dose of 15Gy in 6 fractions over 3 days was prescribed to the 5mm around the implanted volume. She recovered well from the above treatment and put on 20 mg oral tamoxifen regularly. Subsequently she was on regular clinical and radiological follow up. Her serial mammogram, MRI scans and PET scan, bone scan, liver scan and chest radiography were normal. She is with good quality of life and achieved good cosmesis (Figure 4). At the time of reporting she is with no evidence of disease at the end of 69 months of follow-up.

DISCUSSION

Management of invasive breast cancer without surgery is a nightmare for surgical oncologists. It is not uncommon to see breast cancer patients with above situation. The incidence of refusal for surgery is around 2% even in developed countries (8). The cause of refusal for surgery is lack of awareness, communication gap, lack of insurance for surgery and fear for surgery and loss of organ causing change in body image. Medical conditions that preclude surgery include uncompensated heart disease and other medical conditions that do not allow giving general anesthesia. The incidence of refusal for surgery due to medical reason is very low. In our two cases, both cases were medically fit for surgery but they refuse surgery due to fear of loss of organ despite adequate counseling. There may possibly a particular psychological trait those who refuse surgery.

In a study at MD Anderson Cancer Center, 174 patients with locally advanced breast cancers were planned for 3-cycles of FAC induction chemotherapy followed by reassessment for response to treatment by clinical and radiological evaluation. In this study 16.7% of the

patients achieved clinical complete response rate and 70.7% achieved partial response rate (9). Those patients who underwent surgery (mastectomy) histopathological evaluation revealed complete disappearance of the primary tumor. Similar complete responses were observed noticed in other studies. Bear et al from National Surgical Adjuvant Breast and Bowel Project (NSABP) conducted a prospective randomized trial (Project B-27) on 2411 patients comparing induction AC chemotherapy versus AC followed by taxotere versus AC before and taxotere after surgery. All patients underwent surgery and surgicopathological evaluation. Clinical tumor response was improved from 37% with AC to 60.5% with AC and taxotere combination. The pathological complete response rate was improved from 13% to 25% in their study (10). In Aberdeen study on operable breast cancer including 167 patients combination chemotherapy with CVAP and docetaxel showed improved 3-year overall and recurrence free survival rate (11). From the encouraging response rate some authors question about the necessity of surgery among patients showing complete clinical response rate as the overall survival is similar with or without surgery (12).

In a series of post menopausal patients with positive estrogen receptor status were treated with hormonal manipulation alone. Foudraire et al observed 40 elderly breast cancer patients with tamoxifen alone and found an overall survival of 43% and stable disease in another 40% of patients at a mean follow-up period of 29 months (13). In a Cochrane review of randomized clinical trials comparing surgery followed by tamoxifen versus tamoxifen alone among women aged more than 70 years with operable breast cancer. In this analysis there was no difference in the overall survival (14). The authors proposed trials using aromatase inhibitors as sole treatment on receptor positive elderly postmenopausal breast cancer could improve outcome in future.

For patients those who refuse surgery perhaps in such rare situation, patients should be given an opportunity to get alternative treatment option as described in our cases in a curative intent. There should be a consensus for the management of cases those refuse surgery rather than refuse treatment as they do not comply treatment protocol. Cosmetic outcome in radically treated breast cancer patients are poor. There is scanty report in the medical literature about the cosmetic outcome using above technique (15). Among our patients, the cosmetic result was satisfactory. Both patients and their husband

are happy with the outcome following above treatment. Perhaps this treatment is a better option than denying treatment, as they do not comply with our standards of care. Otherwise those patients would have resorted to traditional and alternative treatment. Looking above evidences, there should be a randomized trial comparing radical non-surgical treatment versus standard management with optimal surgery among post-menopausal women with low tumor volume where cosmetic outcome is least important. With the availability of newer chemotherapy agents showing higher response rate and molecular imaging modality to differentiate tumor activity from fibrosis, non-surgical technique could be a rational option for the women those refuse surgery.

REFERENCES

1. Reis MAG, Harkins D, Krapcho M et al. SEER cancer statistics review, 1975-2003. Bethesda,MD. National Cancer Institute, 2006.
2. Gerard Lim CC, Yahaya H. Second Report of the National Cancer Registry Cancer Incidence in Malaysia 2003. National Cancer Registry, Malaysia
3. Bouchardy C, Usel M, Verkooijen HM et al. Changing pattern of age specific breast cancer incidence in the Swiss canton of Geneva. *Breast Cancer Res Treat* 2009;DOI 10.1007/s10549-009-0478-y
4. Rainsbury RM. A patient decline mastectomy. *Br J Surg* 1999;86:1491-2.
5. Estevez LG, Cuevas JM, Florian AAJ et al. Weekly docetaxel as neoadjuvant chemotherapy for stage II and III breast cancer: Efficacy and correlation with biological markers in a phase II multicenter trial. *Clin Cancer Res* 2003;9:686-692.
6. Hind D, Wyld L, Beverley CB, Reed MW. Surgery versus primary endocrine therapy for operable primary breast cancer in elderly women (70 years plus); Cocharne database *Syst Rev* 2006;25:CD004272.
7. Oura S, Tamaki T, Hirai I et al. Radiofrequency ablation therapy in patients with breast cancers two centimeters or less in size. *Breast Cancer* 2007;14:48-54.
8. Verkooijen HM, Fioretta GM, Rapiti E et al. Patients' refusal of surgery strongly impairs breast cancer survival. *Ann Surg* 2005;242:276-80.
9. Hortobagyi GN, Ames FC, Buzdar AU et al. Management of stage III primary breast cancer with primary chemotherapy, surgery and radiation therapy. *Cancer* 1988;62:2507-16
10. Bear HD, Anderson S, Brown A et al. The effect on tumor response of adding sequential preoperative docetaxel to preoperative doxorubicin and cyclophosphamide: Preliminary results from National Surgical Adjuvant Breast and Bowel Project Protocol B-27. *J Clin Oncol* 2003;21:4165-74.
11. Smith IC, Heys SD, Hutcheon AW et al. Neoadjuvant chemotherapy in breast cancer: significantly enhanced response with docetaxel. *J Clin Oncol* 2002;20:1456-66.
12. Ring A, Webb A, Ashley S et al. Is surgery necessary after complete clinical remission following neoadjuvant chemotherapy for early breast cancer? *J Clin Oncol* 2003;21:4540-5.
13. Foudraine NA, Verhoef LC, Burghouts JT. Tamoxifen as sole therapy for primary breast cancer in the elderly patient. *Eur J Cancer* 1992;28:900-3.
14. Hind D, Wild L, Reed MW. Surgery with or without tamoxifen versus tamoxifen alone for older women with operable breast cancer: Cocharne Review. *Br J Cancer* 2007;96:1025-9.
15. Dubois JB, Salomon A, Gary-Bobo J, Gary-Bobo J, Pourquier H, Pujal H. Exclusive radical radiation therapy in breast carcinoma. *Radiother Oncol* 1991;20:24-9.