



Case Report

Volume 2 - Issue 1: 9-12 / January 2019

CYTOMEGALOVIRUS PNEUMONIA IN A PATIENT WITH ANKYLOSING SPONDYLITIS: CASE REPORT

Sevil Alkan ÇEVİKER^{1*}, Özgür GÜNAL¹

¹Samsun Education and Research Hospital, Department of Infectious Diseases and Clinical Microbiology, 55090, Samsun, Turkey

Received: September 04, 2018; **Accepted:** December 12, 2018; **Published:** January 01, 2019


Abstract


Nowadays, biological agents such as anti-tumor necrosis factor alpha (anti-TNF α) drugs are used in the treatment of many chronic inflammatory diseases, particularly in those cases that do not respond to conventional treatments. However, infrequently, opportunistic infections such as bacterial, viral, fungal and parasitic infections may develop in patients treated with anti-TNF therapy, and physicians should be cautious in terms of increased risk of infection when using these agents. In this case report, we present a case of bilateral Cytomegalovirus (CMV) pneumonia in an adalimumab treated patient due to ankylosing spondylitis.

Keywords: Cytomegalovirus, Pneumonia, Ankylosing Spondylitis, Adalimumab

*Corresponding author: Samsun Education and Research Hospital, Department of Infectious Diseases and Clinical Microbiology, 55090, Samsun, Turkey

E mail: s-ewil@hotmail.com (S.A. ÇEVİKER)

Sevil Alkan ÇEVİKER  <https://orcid.org/0000-0003-1944-2477>

Özgür GÜNAL  <https://orcid.org/0000-0002-7744-4123>

Cite as: Çeviker SA, Günel Ö. 2019. Cytomegalovirus pneumonia in a patient with ankylosing spondylitis: Case report. BSJ Health Sci, 2(1): 9-12.

1. Introduction

Biological agents that have been in use for about 20 years have been shown to block specific pathways and signals of inflammation. Anti-TNF α therapy is the most commonly used class of biological agents (Willrich et al, 2015).

TNF- α , a transmembrane protein expressed from macrophages, T-lymphocytes, natural killer cells, smooth muscle cells and fibroblasts, is an important proinflammatory cytokine and inflammatory agent, plays a role in the pathogenesis of autoimmune disease. Reduction of TNF- α levels by anti-TNF α treatment results in promising results in treatment of patients who do not respond to conventional therapy in these diseases. However, opportunistic infections such as bacterial, viral,

fungal and parasitic infections may develop in these patients, and physicians should be cautious about the risk of increased infection in the use of these agents (Galloway et al, 2011).

In this case report, we aimed to present a case of bilateral CMV multifocal interstitial pneumonia in an adalimumab and steroid treated patient due to ankylosing spondylitis.

2. Case Presentation

A 56-year-old male patient presented to our emergency department (ED), with high fever, cough and acute respiratory failure. The patient had been febrile for 3 days and developed rapidly worsening shortness of breath and dry cough in the last 12 hours. According to the patient's history, he did not smoke and had a history of ankylosing

spondylitis. Physical examination revealed moderate general condition with confusion, tachypnea (respiratory rate: 24/minute), fever (101°F), hypotension (80/50 mmHg) and tachycardia (120 bpm) and SpO₂ at room temperature: 88%. Respiratory system examination revealed bilateral inspiratory and expiratory rales and rhonchi were observed. The patient's laboratory results at admission of emergency department(ED) were as follows: white blood cell count: 3800/ μ L (45% PNL), hemoglobin: 10.6 g/dL (13.5-17.5), hematocrit: 33.4% (40-52), platelet count: 129000/ μ L (140000-440000), C-reactive protein: 195 mg/L (0-5), glucose: 89 mg/L (80-110), blood urea

nitrogen: 40 mg/dL (6-26), creatinine: 1.2 mg/dL (0.7-1.3), sodium: 131 meq/L (132-136), aspartate aminotransferase (AST): 68 U/L (5-35), alanine aminotransferase (ALT): 51 U/L (0-55), lactate dehydrogenase: 171 U/L, creatinine kinase (CK): 153 U/L and with low procalcitonin (2 ng/mL. Arterial blood gas analysis showed severe hypoxemia (pH 7.50, pO₂ 50 mmHg, pCO₂ 29 mmHg, SatO₂ 76%). Anti-HIV test was negative. A chest x-ray and pulmonary CT performed in the ED showed bilateral multifocal involvement of the lungs with marked diffuse interstitial pattern (Figure 1).

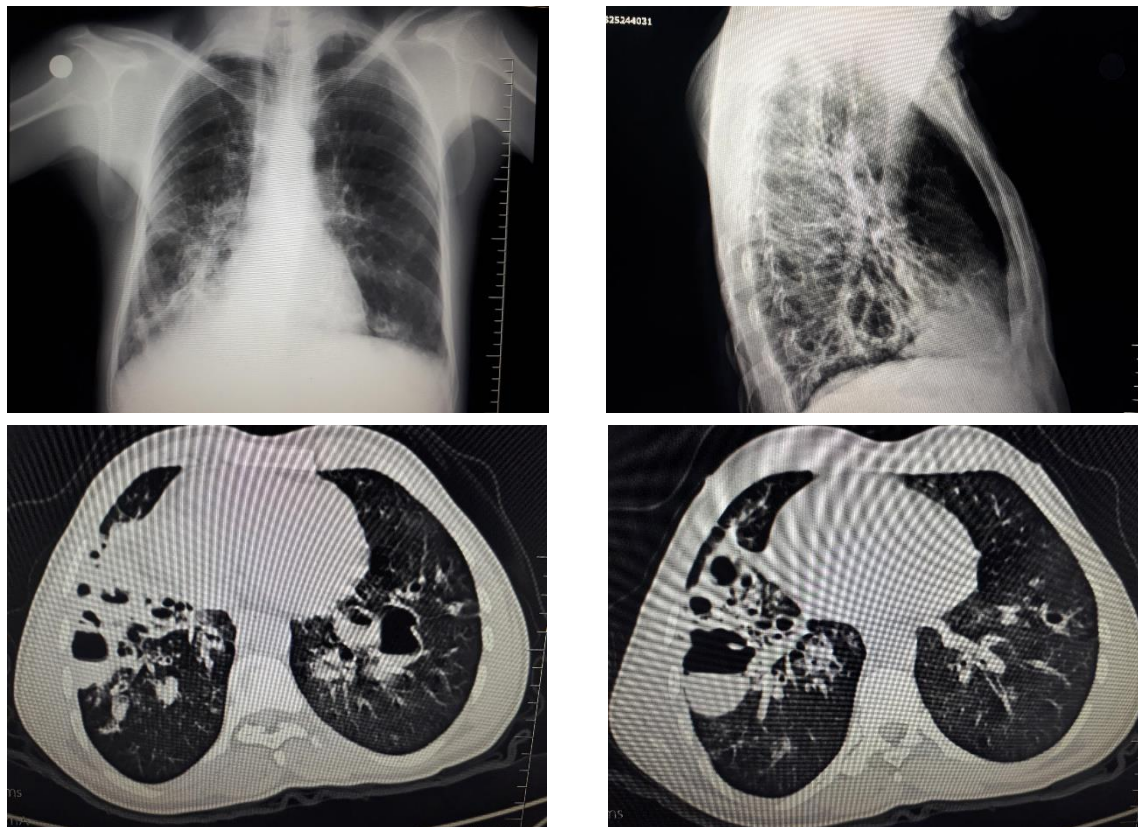


Figure 1. A chest x-ray and pulmonary CT

The patient was transferred to the intensive care unit for oxygen support. His immunosuppressive treatment were stopped. Treatment with intravenous (iv) levofloxacin 750 mg/day and iv imipenem 4x1 gr/day was initiated. Sputum, blood and urine cultures performed before antibiotic treatment. No growth was observed in his cultures. Legionella urine antigen test was negative. The patient suffered increased respiratory distress (respiratory rate 32/minute) and his respiratory distress improved with treatment after twenty hours of hospitalization and he placed on mechanical ventilation. Gram stain of quantitative culture of endotracheal aspirate was negative and no bacterial or fungal growth was observed on endotracheal aspirate cultures,too. No acid-fast bacteria were detected through Ziehl-Neelsen

staining. *Aspergillus galactomannan* antigen was negative. Polymerase chain reaction (PCR) examinations were sent to the external center because they were not studied in our hospital. No substantial clinical or radiological improvement was observed despite the antibiotic therapy and he was persistently in severe respiratory distress. Oseltamivir and co-trimoxazole was added to the treatment as the clinical findings of the patient continued to worsen. PCR testes were negative for *herpes simplex virus 1/2*, *adenovirus*, *influenza A/B*. He was death on the fifth day of admistration. After his death PCR test result positive for *Cytomegalovirus* and he was death due to CMV pneumonia.

3. Results and Discussion

Today, five anti-TNF- α active agents are active in infliximab, etanercept, adalimumab, golimumab and sertolizumab pegol. Before treatment begins, patients are screened for tuberculosis according to the guidelines of the Association for Rheumatology Education and Research (RAED) and isoniazide. However, there are no stimulant suggestions in the guidelines for the prevention of opportunistic infections that may develop in these patients (Keser G et al, 2005).

Cytomegalovirus infection can result in high morbidity and mortality rates and particularly important in immunocompromised (e.g. those with AIDS / allogenic bone marrow transplantation patients (Horger et al, 2006). Pulmonary findings are non-specific and diverse and have been described without distinction between AIDS and non-AIDS patients. Clinical signs and radiological findings including fever, cough, dyspnea, and hypoxemia were not specific to distinguish CMV pneumonia from other pneumonia. Commonly described findings are mixed alveolar-interstitial infiltrative opacification, confluent consolidation, small pulmonary nodules, bronchiectasis and interstitial reticulation without air space opacification (Moon et al, 2002). Our patient pulmonary CT showed bilateral multifocal involvement of the lungs with marked diffuse interstitial pattern (Figure 1).

The incidence of CMV pneumonia in patients diagnosed with hematologic malignancies has been reported to range from 2.3% to 16%, with an overall mortality rate of 57%, which is increasing (Nguyen et al, 2001).

There are some literatures describing non-transplant patients with the risks of CMV pneumonia use of adalimumab (Park et al, 2017). Adalimumab, a fully human anti-TNF α monoclonal antibody, has been shown to be effective and generally well tolerated when used for therapy to reduce the signs and symptoms of ankylosing spondylitis has not fully responded to other medicines in adults. One study in literature showed that, 23 458 patients from global clinical trials in rheumatoid arthritis, juvenile idiopathic arthritis, ankylosing spondylitis, psoriatic arthritis, psoriasis and Crohn's disease and find no serious opportunistic infections have been reported with adalimumab in patients (Burmester et al, 2012).

Adalimumab is considered to be safe drug (Colombel et al, 2018). The case we present was receiving adalimumab-combined therapy with corticosteroids for six months. Corticosteroids is also known to increase the risk of infection. In this case report we think corticosteroid treatment was associated with the increased risk of CMV infection and mortality.

As the use of corticosteroids in patients with rheumatic disease and CMV infection may lead to weak humoral and cellular immune responses. In a study, CMV DNA was detected in 142 (17.0%) of 834 patients received corticosteroid therapy for rheumatic diseases

corticosteroids therapy alone, respectively, suggesting that combination immunosuppressive therapy may shorten the time of CMV reactivation. In this study, 142 CMV positive patients underwent lung imaging, and 73 showed interstitial pneumonia (Xue et al, 2016). It is hard to say exactly as studies has limitations and most controlled clinical trials of anti-TNF treatment found that the risk of developing an infection is minimally increased.

4. Conclusion

Patients receiving anti-TNF treatment require a multidisciplinary approach with a specialist in chest diseases and infectious diseases, as well as the related branch physicians who start treatment before and during treatment. During these treatments risk factors should be kept in mind in terms of opportunistic infections and preventive importance should be taken. As well as in the diagnosis and treatment of opportunistic infections that develop in such patients. Microbiological cultures and PC testes should be performed early. It should not be forgotten that opportunistic infectious agents may be mortal in these patients. As there were no guideline for prevention of opportunistic infections in the settings of anti-TNF treatment, additional studies should be conducted on infections occurring in patients receiving anti-TNF therapy. During immunosuppressive therapy, beware of CMV infection.

Conflict of interest

The authors declare that there is no conflict of interest.

Financial Disclosure

The authors declared that this study received no financial support.

References

- Burmester GR, Panaccione R, Gordon KB, McIlraith MJ, Lacerda AP. 2013. Adalimumab: long-term safety in 23 458 patients from global clinical trials in rheumatoid arthritis, juvenile idiopathic arthritis, ankylosing spondylitis, psoriatic arthritis, psoriasis and Crohn's disease. *Ann Rheum Dis*, 72: 517–524.
- Colombel JF, Sandborn WJ, Reinisch W, Peyrin-Biroulet L, Panaccione R, Rutgeerts P, Hanauer SB, Ghosh S, Van Assche G, Robinson AM, Lau W, Maa JF, Huang B, Pappalardo B, Read H. 2018. Long-term safety of adalimumab in clinical trials in adult patients with Crohn's disease or ulcerative colitis. *Aliment Pharmacol Ther*, 47(2): 219-228.
- Galloway JB, Hyrich KL, Mercer LK, Dixon WG, Fu B, Ustianowski AP, Watson KD, Lunt M, Symmons DP. 2011. Anti-TNF therapy is associated with an increased risk of serious infections in patients with rheumatoid arthritis especially in the first 6 months of treatment: updated results from the British Society for Rheumatology Biologics Register with special emphasis on risks in the elderly. *Rheumatology (Oxford)*, 50: 124–131.
- Horger MS, Pfannenbergs C, Einsele H, Beck R, Hebart H, Lengerke C, Vonthein R, Wehrmann M, Faul C, Claussen C. 2006.

- Cytomegalovirus pneumonia after stem cell transplantation: correlation of CT findings with clinical outcome in 30 patients. *AJR Am J Roentgenol*, 187.
- Keser G, Direskeneli H, Akkoç N. 2005. TNF- α engelleyici ilaç kullanan olguların tedavi öncesinde tüberküloz açısından değerlendirilmesi ve alınması gerekli önlemler. *RAED II. Uzlaşı Toplantısı Raporu* 7.
- Moon JH, Kim EA, Lee KS, Kim TS, Jung KJ, Song JH. 2002. Cytomegalovirus pneumonia: high-resolution CT findings in ten non-AIDS immunocompromised patients. *Korean J Radiol*, 1 (2): 73-78.
- Nguyen Q, Estey E, Raad I, Rolston K, Kantarjian H, Jacobson K, Konoplev S, Ghosh S, Luna M, Tarrand J, Whimbey E. 2001. Cytomegalovirus pneumonia in adults with leukemia: an emerging problem. *Clin Infect Dis*, 32:539-545.
- Park SC, Jeon MY, Jeon YT. 2017. Approach to cytomegalovirus infections in patients with ulcerative colitis. *Korean J Intern Med*, 32(3): 383-392.
- Xue Y, Jiang L, Wan WG, Chen YM, Zhang J, Zhang ZC. 2016. Cytomegalovirus pneumonia in patients with rheumatic diseases after immunosuppressive therapy: A single center study in China. *Chin Med J*, 129:267-273.
- Willrich MAV, Murray DL, Snyder MR. 2015. Tumor necrosis factor inhibitors: clinical utility in autoimmune diseases. *Transl Res*, 165(2): 270-282.