

ETHMOID OSTEOMA WITH FRONTAL AND FRONTOBASAL EXTENSION

*Murat Coşar¹, Olcay Eser¹, Adem Aslan¹, Abdullah Ayçiçek²,
Sefa Dereköy², Hüsniye Dilek³*

Kocatepe University, Faculty of Medicine, Departments of Neurosurgery¹,
Otorhinolaryngology² and Pathology³, Afyonkarahisar, Turkey

Paranasal sinus osteomas are benign slow growing tumors, occasionally known to cause complications for a long time. Frontobasal extension of paranasal sinus osteoma is an uncommon localization. We present a 20 year-old-man admitted to our clinic with a complaint of pus drainage and wound from forehead for 2 weeks. The radiological images of the patient revealed a mass mimicking osteoma and extending into the frontal sinus and frontobasal area with a chronic infection. The patient was initiated antibiotics for 2 weeks and the mass was extirped through the destructed anterior wall of frontal sinus. The histopathological diagnosis was osteoma and the patient was discharged uneventfully at the 7th day after the operation.

Key words: Frontal, ethmoid sinuses, osteoma, surgical treatment

Eur J Gen Med 2008; 5(1):48-50

INTRODUCTION

Although the frontobasal extension of the osteoma is uncommon, it is the most frequent benign tumor of the paranasal sinuses (1-5). It is a slow growing, osteogenic neoplasm that usually originates from the frontal and ethmoid sinus and much less frequently seen in the maxillary and sphenoid sinuses (1). The tumor is generally asymptomatic with incidental radiologic findings but, complications of paranasal sinus osteomas have been known for a long time (6,7). Pain, sinus obstruction and infection are initial symptoms of growing osteomas in ethmoid sinus. Facial deformity, visual changes, or intracranial complications may occur when the lesion become large (1,4,8,9). In this report, we present an ethmoidal osteoma extending into the frontal sinus and frontobasal which was treated surgically.

CASE

A 20 year-old-man admitted to our clinic with a complaint of pus drainage and wound from forehead for 2 weeks. The history of the patient revealed skin blushing and swelling in the forehead for 2 months and progressive frontal headache for one year which had become

more intense for 6 months. The physical examination of the patient revealed fore head infection under the skin. The neurological examination of the patient was normal. Anterior wall destruction of frontal sinus was detected in the direct plain radiographies. Cranial computerized tomography (CT) and magnetic resonance imaging (MRI) showed that the mass was arising from posterior ethmoid cells, extending posteriorly to frontobasal region and frontal sinus, and destructing the anterior wall of frontal sinus. Additionally, infection was accompanying to the mass in the frontal sinus (Figure 1a, 1b). Surgical removal of the lesion was planned and forehead pus and infected materials extending to the frontal sinus were drained with a needle puncture and antibiotics (Ceftriaxon 2x1 gr) was initiated for 2 weeks. The skin blushing and swelling became normal after 2 weeks and operation was planned. Bifrontal skin incision was performed to the patient. The frontal sinus, posterior ethmoid cell and frontobasal located mass was extirped through the destructed anterior wall of frontal sinus. Autogenous grafts from frontal bone were mounted between the frontal and ethmoid sinus. Additionally, lipid tissues transferred from abdominal

Correspondence: Murat Cosar

PK:34 03000 Afyonkarahisar / Turkey

Phone:905058041362

E-mail:drcosar@hotmail.com

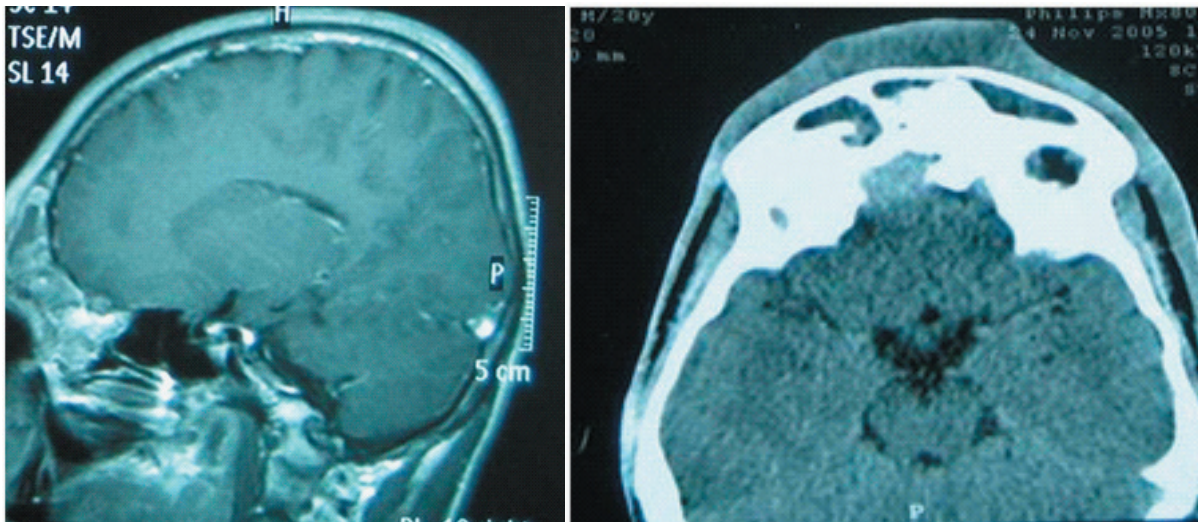


Figure 1a. The T1 weighted contrasted sagittal MRI showing the extension of mass from frontobasal region to the fronto-ethmoidal sinuses. **Figure 1b.** The axial CT image showing a hyperdense mass in the frontal sinus.

region located to the bottom of the frontal sinus and cranioplasty was performed to the roof of frontal sinus. The histopathological examination revealed the osteoma that composed of well-formed bony spicules with prominent cement lines and calcification. They may demonstrate osteoblasts, osteoclasts, and osteocytes and occasionally may even demonstrate bone marrow elements (Figure 2). The course was uneventful and the patient was discharged at the 7th day after the operation. The neurological and physical examination and follow-up cranial CT scans were normal which were performed 1 month and 6 months after the operation (Figure 3a, 3b).

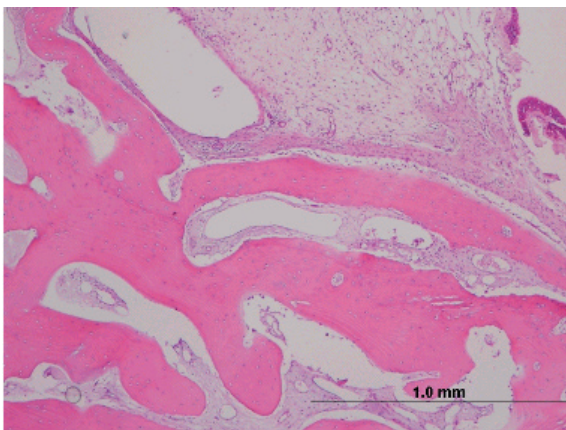


Figure 2. It shows osteoma that is composed of well-formed bony spicules with prominent cement lines and calcification, (H&E \times 200).

DISCUSSION

In relation to its dimensions and localization, a sinonasal osteoma can give rise to functional symptoms, infection, ophthalmologic and cerebral complications etc (1,10,11). Most authors agree that symptomatic osteomas should be treated surgically, but there is some controversy regarding the management of asymptomatic osteomas (5,12,13). According to Savic and Djeric (3), asymptomatic osteomas should be operated upon if they extend beyond the frontal sinus boundaries, if they can be demonstrated to be enlarging on repeated radiological examinations, or if they are located near the frontonasal duct. Chronic infection of frontal sinus due to its obstruction had caused to the destructed anterior wall of frontal sinus and severe headache.

Although the first surgical removal of an osteoma of the paranasal sinuses was performed and recorded as early as 18th century, type of surgical approach of these tumors have not yet been established (3). Osteoplastic flap operation, Reidel's operation, and lateral rhinotomy are the main open procedures which have been used for many years. Osteoblastic flap technique should be used for the frontal and ethmoid sinuses osteomas. Reidel's operation may be chosen when the osteoma has destroyed the anterior wall of the frontal sinus, and in extremely large osteomas

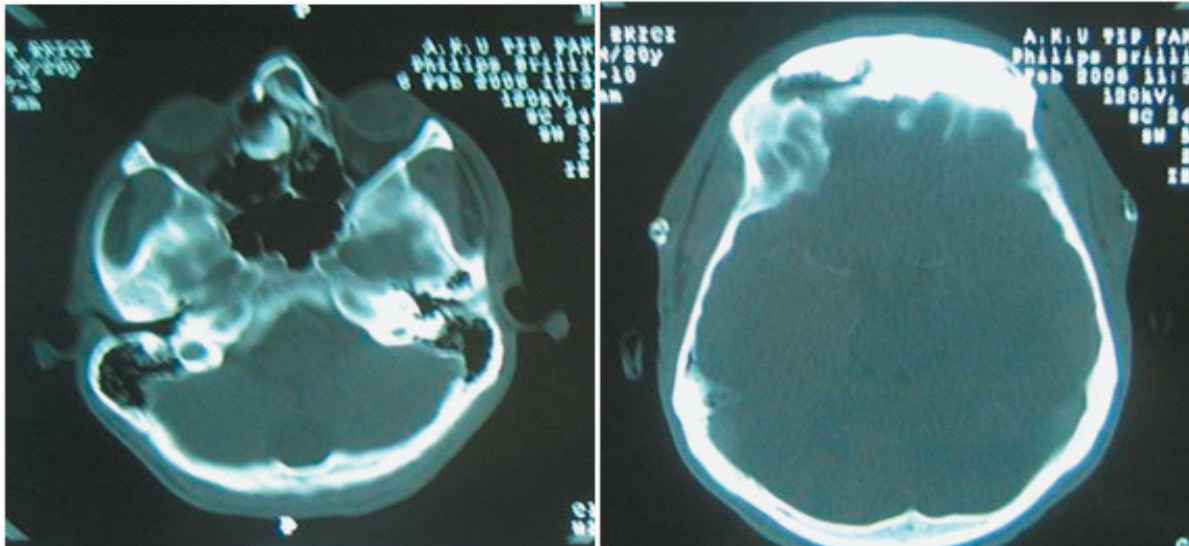


Figure 3a. The postoperative axial CT scan showing cranioplasty material in the frontal sinus. **Figure 3b.** The postoperative axial CT scan showing autogenic bone graft in the ethmoid sinus.

penetrating into the anterior cranial fossa. Additionally, lateral rhinotomy should be used for very large osteomas affecting the frontal, ethmoid and maxillary sinuses (3). The recent development techniques has offered endoscopic approach for solitary ethmoidal osteomas (1). Due to destructed anterior wall and frontobasal extension of our case we decided to perform a modified Reidel's operation. We planned osteoplastic approach but, because of the anterior wall destruction of frontal sinus we could not perform. So, we performed a modified osteoplastic approach.

Direct plain radiographies may show the destruction of bones, additionally may help to plan the operation. CT is gold standard for diagnosis and follow up of these kind of lesions. MRI may help for diagnosis of pus and soft tissue included osteomas as seen in our case.

As a conclusion, we think that the silent osteomas of the paranasal sinuses must be followed carefully. It may obstruct frontal sinus and may trigger infection.

REFERENCES

1. Saetti R, Silvestrini M, Narne S. Ethmoid osteoma with frontal and orbital extension: endoscopic removal and reconstruction. *Acta Otolaryngol* 2005;125(10):1122-5
2. Pai Balaji S, Harish K, Venkatesh MS, Jermely U, Jermely D. Ethmoid osteoid osteoma with orbital and intracranial extension: a case report. *BMC Ear, Nose and Throat Disord* 2005;11:2
3. Savic DLJ, Djerić DR. Indications for the surgical treatment of osteomas of the frontal and ethmoid sinuses. *Clin Otolaryngol* 1990;15:397-404
4. Blitzer A, Post KD, Conley J. Craniofacial resection of ossifying fibromas and osteomas of the sinuses. *Arch Otolaryngol Head Neck Surg* 1989;115:1112-5
5. Koivunen P, Löppönen H, Fors AP, Jokinen K. The growth rate of osteomas of the paranasal sinuses. *Clin Otolaryngol* 1997;22:111-4
6. Spencer MG, Mitchell DB. Growth of a frontal sinus osteoma. *J Laryngol Otol* 1987;101:726-8
7. Becelli R, Santamaria S, Saltarel A, Carboni A, Iannetti G. Endo-orbital osteoma: two case reports. *J Craniofac Surg* 2002;13 493-6
8. Mitrani M, Remsen K, Lawson W, Biller HF. Giant ossifying fibroma of the paranasal sinuses. *ENT J* 1988;67:186-92
9. Young FW, Putney FJ. Ossifying fibroma of the sinuses. *Ann Otol Rhinol Laryngol* 1968;77:425-34
10. Koyuncu M, Belet U, Sesen T, Tanyeri Y, Simsek M. Huge osteoma of the frontoethmoidal sinus with secondary brain abscess. *Auris Nasus Larynx* 2000;27:285-7
11. Bourgeois P, Fichten A, Louis E, Vincent C, Pertuzon B, Assaker R. Frontal sinus osteomas: neuro-ophtalmological complications. *Neurochirurgie* 2002;48:104-8
12. Smith ME, Calcaterra TC. Frontal sinus osteoma. *Ann Otol Rhinol Laryngol* 1989;98:896-900
13. Atallah N, Jay MM. Osteomas of the paranasal sinuses. *J Laryngol Otol* 1981;95: 291-304